

**Arthroscopic Primary Repair of the  
Anterior Cruciate Ligament:  
Rationale, Patient Selection and Early Outcomes**



Jelle van der List

## **Colofon**

### **The work presented in this thesis was performed at:**

The Amsterdam Movement Sciences Research Institute, at the department of Orthopaedic Surgery, Amsterdam UMC, location AMC, the Netherlands and at the department of Orthopaedic Surgery at the Hospital for Special Surgery, New York, NY, United States of America.

### **The printing of this thesis was financially supported by:**

Arthrex, Quin, Wetenschapsbureau Spaarne Gasthuis, Nederlandse Orthopaedische Vereniging, Nederlandse Vereniging voor Arthroscopie, Maatschap Orthopedie Spaarne Gasthuis, Amsterdam Medisch Centrum, Link & Lima Nederland, Amsterdam Movement Sciences, Kaptein Orthopedie, CORAL, Orthis Voetzorg, Anna Fonds te Leiden, and Mathot

### **ISBN**

978-94-6421-480-2

### **Lay-out**

Jelle van der List

### **Cover**

Gezicht op Nieuw-Amsterdam by Johannes Vingboons. Obtained from goodfreephotos.com with permission

### **Print**

Ipskamp Printing, Enschede

© Jelle van der List, 2021

All rights reserved. No part of this book may be reproduced, stored in a retrieval system, or transmitted, in any form or by any means, electronically, mechanically, by photocopying, recording or otherwise without the written permission of the author.

**Arthroscopic Primary Repair of the Anterior Cruciate Ligament:  
Rationale, Patient Selection and Early Outcomes**

**ACADEMISCH PROEFSCHRIFT**

ter verkrijging van de graad van doctor

aan de Universiteit van Amsterdam

op gezag van de rector magnificus

prof. dr. ir. K.I.J. Maex

ten overstaan van een door het College voor Promoties ingestelde commissie,

in het openbaar te verdedigen in de Agnietenkapel

op donderdag 4 november 2021, te 10.00 uur,

door

**Jelle Philip Jacob van der List**

geboren te Rotterdam

## Promotiecommissie:

<b>Promotor:</b>	prof. dr. G.M.M.J. Kerkhoffs	AMC-UvA
<b>Copromotor:</b>	dr. A. van Noort	Spaarne Gasthuis
<b>Overige leden:</b>	prof. dr. J.L. Tol	AMC-UvA
	prof. dr. M. Maas	AMC-UvA
	prof. dr. R.J. Oostra	AMC-UvA
	prof. dr. E.A.L.M. Verhagen	Vrije Universiteit Amsterdam
	prof. dr. Nollet	AMC-UvA
	dr. R.P.A. Janssen	Máxima Medisch Centrum
	dr. M.V. Rademakers	Spaarne Gasthuis
<b>Faculteit:</b>	Faculteit der Geneeskunde	

Stellingen behorende bij het proefschrift

# **Arthroscopic Primary Repair of the Anterior Cruciate Ligament: Rationale, patient selection and early outcomes**

1. The surgical history of ACL injuries contains a paradigm shift. *(this thesis)*
2. For successful outcomes of primary ACL repair, patient selection is critical. *(this thesis)*
3. Primary repair may be possible in up to 70,000 patients in the United States and 3,500 patients in the Netherlands annually if these ACL injuries were treated acutely. *(this thesis)*
4. Arthroscopic primary repair is a tool that should be in the armamentarium of every surgeon. *(this thesis)*
5. Preserve what is possible, reconstruct what is necessary. *(this thesis, from Gregory S. DiFelice)*
6. Early outcomes of arthroscopic primary repair are good and a randomized controlled trial is needed to assess the objective and long-term outcomes. *(this thesis)*
7. You can't connect the dots looking forward, you can only connect them looking backwards. So, you have to trust that the dots will somehow connect in your future. *(Steve Jobs)*
8. Stay hungry, stay foolish. *(Steve Jobs)*
9. Listen to your patients, they are trying to tell you their diagnosis. *(William Osler)*
10. Always listen to experts. They'll tell you what can't be done, and why. Then do it. *(Robert Heinlein)*
11. Je gaat het pas zien als je het door hebt. *(Johan Cruijff)*

**Jelle van der List**, Amsterdam, 2021

# Table of Contents

<b>Chapter 1</b>	General introduction, aims and outline of this thesis	<b>9</b>
<b>Chapter 2</b>	Primary repair of the anterior cruciate ligament: a paradigm shift	<b>23</b>
<b>Chapter 3</b>	Role of tear location on outcomes of open primary repair of the anterior cruciate ligament: a systematic review of historical studies	<b>39</b>
<b>Chapter 4</b>	Age, activity level and meniscus injury, but not tear location, tibial slope or anterolateral ligament injury predict coping with anterior cruciate ligament injury	<b>59</b>
<b>Chapter 5</b>	The location of anterior cruciate ligament tears: a prevalence study using magnetic resonance imaging	<b>79</b>
<b>Chapter 6</b>	Preoperative magnetic resonance imaging predicts eligibility for arthroscopic primary anterior cruciate ligament repair	<b>97</b>
<b>Chapter 7</b>	Identifying candidates for arthroscopic primary repair of the anterior cruciate ligament: a case-control study	<b>119</b>
<b>Chapter 8</b>	Range of motion and complications following primary repair versus reconstruction of the anterior cruciate ligament	<b>135</b>

# Table of Contents

<b>Chapter 9</b>	Arthroscopic primary repair of proximal anterior cruciate ligament tears seems safe but higher level of evidence is needed: a systematic review and meta-analysis of recent literature	<b>157</b>
<b>Chapter 10</b>	Arthroscopic primary repair of proximal anterior cruciate ligament tears: outcomes of the first 56 consecutive patients and the role of additional internal bracing	<b>177</b>
<b>Chapter 11</b>	Clinical outcomes of arthroscopic primary repair of proximal anterior cruciate ligament tears are maintained at mid-term follow-up	<b>191</b>
<b>Chapter 12</b>	Repair versus reconstruction for proximal anterior cruciate ligament tears: a study protocol for a randomized controlled trial	<b>207</b>
<b>Chapter 13</b>	General discussion, future perspectives, and conclusions	<b>227</b>
<b>Appendices</b>	Surgical technique	<b>241</b>
	Summary	<b>253</b>
	Summary in Dutch (Samenvatting)	<b>257</b>
	PhD Portfolio	<b>261</b>
	Reference list with contributions of the authors	<b>269</b>
	List of publications	<b>275</b>
	Acknowledgments	<b>285</b>





# **Chapter 1**

**General introduction, aims  
and outline of this thesis**

## General introduction

The anterior cruciate ligament (ACL) is a ligament in the center of the knee and functions as an important knee stabilizer. It is one of the most injured ligaments in the knee, and also one of the most frequently studied ligaments in the field of orthopaedic research with hundreds of studies published annually on this topic.<sup>1</sup> Injury of the ACL can often lead to pain or instability and prevent playing sports that are demanding for the knee.

In the second part of the twentieth century, preserving and repairing (*primary repair*) the torn ligament, rather than removing and replacing (*reconstruction*), was the most common procedure for ACL injury, but fell out of favor due to various reasons. This thesis will focus on a 'renaissance' of primary repair and assesses the modern indications, techniques and outcomes of this 'renewed' procedure.

This first chapter provides an overview of the anatomy and function of the ACL, etiology and epidemiology of ACL injury, and it will review the historical and current treatments of ACL injury. At the end of this chapter, the research questions and outline of this thesis are presented.

## Anterior Cruciate Ligament

### Anatomy

The ACL is a ligament of approximately three to four centimeters long and runs within the joint (intra-articular) between the tibia and the femur. The ligament consists of dense connective tissue fascicles and is composed of predominantly collagen type I and some collagen type III.<sup>2</sup> A synovial fold covers the ligament, which ensures that the ligament is not in contact with the synovial fluid of the knee.<sup>2</sup> The ACL has two distinct bundles, named after their tibial insertion: the anteromedial (AM) and posterolateral (PL) bundle.<sup>2</sup> The AM bundle runs from an anteromedial position within the tibial footprint to a proximal and anterior position within the femoral footprint, whereas the PL bundle runs from a posterolateral position within the tibial footprint to a distal and posterior position within the femoral footprint on the medial side of the lateral femoral condyle.<sup>2,3</sup>

The majority of the blood supply to the ACL is received proximally from the medial genicular artery, while the other blood supply is received at the distal insertion from the medial and lateral inferior genicular arteries.<sup>2,4</sup> These arteries provide blood supply to the ligament via a rich network of vessels within the synovial fold.<sup>2</sup> The proximal and distal ends of the ligament receive more blood supply than the relatively hypovascular middle part of the ligament.<sup>2,4</sup>

The ACL is innervated distally by branches of the tibial nerve that run from distal to proximal along and within the synovium. The ligament has slow mechanoreceptors that provide information on the motion and positioning of the knee joint (proprioception) and fast

mechanoreceptors that provide information on fast changes in ligament tensioning.<sup>5,6</sup> Several studies have shown that, in the setting of ACL injury, the mechanoreceptors are still present and functioning in some extent.<sup>6-8</sup>

### **Function**

The ACL functions as a primary stabilizer for anterior tibial translation and internal rotation of the tibia relative to the femur.<sup>9</sup> The AM and PL bundles differ in the biomechanical function as the AM bundle mainly resists anterior translation of the tibia at flexion and the PL bundle mainly resists internal tibial rotation and resists anterior translation at near extension.<sup>10</sup> The ACL also acts as a secondary stabilizer to valgus and varus stress.

## **Anterior Cruciate Ligament Injury**

### **Epidemiology**

ACL injuries have been on the rise over the last decades in both the adult<sup>11</sup> and pediatric population<sup>12</sup>. The reported incidence of ACL injuries ranges between 37 and 79 injuries per 100,000 person-years, which corresponds to approximately 200,000 new injuries in the United States and approximately 10,000 in the Netherlands each year.<sup>11,13-15</sup> Injuries most often occur between the ages of 14 and 35 years, likely because of the high sports participation rates at these ages.<sup>13</sup> Women are at increased risk for ACL injury, especially at a younger age, which can be explained by anatomical, biomechanical and possibly hormonal differences.<sup>13,16</sup> Despite this higher risk for women, more men suffer from ACL injuries annually due to the higher absolute exposure to sports activities.<sup>13</sup>

### **Etiology**

ACL injuries occur in approximately 70% of the time without any form of physical contact.<sup>17,18</sup> They most commonly occur during pivoting movements, incorrect landing, or sudden acceleration or deceleration.<sup>17,18</sup> Generally, two major injury mechanisms have been described in the literature (Figure 1).<sup>19</sup> The most common injury mechanism is a pivoting movement with the knee in flexion and the foot in external rotation, while the knee collapses in valgus.<sup>20</sup> The other often-described injury mechanism is a hyperextension of the knee with the ACL impinging at the femoral notch leading to an ACL tear.<sup>21</sup> In the setting of contact injuries, there is often impact on the outside of the knee forcing the knee inwards (in valgus) and increasing the stress on the ACL leading to injury.

Most injuries occur during sports activities, such as football, soccer, basketball and skiing. The ACL can also tear in the setting of a knee dislocation, often caused by high-energy trauma, such as motor vehicle accidents or falls from a height. In these settings, other stabilizing ligaments, such as the posterior cruciate ligament (PCL), medial collateral ligament (MCL) or lateral collateral ligament (LCL), are often injured as well.



**Figure 1.** On the left, an example of a non-contact ACL injury in which the player in white-red makes a pivoting move, while the left knee is in 30° flexion and the foot externally rotated, leading to valgus collapse and subsequent ACL injury. On the right, an example of a contact ACL injury when the knee is forced in valgus, while the knee is flexed and the foot is externally rotated.

## Diagnosis

When patients tear their ACL, they often describe a loud ‘pop’, and experience pain and instability of the knee.<sup>22</sup> After the injury, haemarthrosis and knee effusion usually occur rapidly, and patients complain of their knee giving way. This giving way sensation can be explained by the tibia moving forward and rotating internally that is not resisted by the torn ACL.<sup>23,24</sup>

Physical examination that consists of a Lachman test, anterior drawer test and pivot shift test, are generally performed in every patient. These tests should be compared to the contralateral knee, as different laxity patterns are present in individual patients. A meta-analysis by Van Eck et al. has shown that the three tests have comparable specificity, but that under anesthesia the Lachman test was most sensitive and the pivot shift test was most specific.<sup>25</sup> The anterior drawer test is less commonly used in diagnosing ACL tears and is thought to be more useful in the chronic setting, possibly due to progressive injury of the secondary stabilizers with the increased knee laxity.<sup>26</sup>

The first choice of imaging is anterior-posterior and lateral radiographs of the knee to assess any bony deformities. Segond fractures can be present at the lateral side of the tibia, indicating a bony avulsion of the anterolateral ligament (ALL) or capsule, which is considered pathognomonic for ACL injury.<sup>27</sup> Furthermore, distal bony avulsions can be detected using radiographs and these avulsions are more common in the pediatric population.<sup>28</sup>

Magnetic resonance imaging (MRI) is often used for the diagnosis of ACL injury and concomitant injuries. The estimated sensitivity and specificity of MRI for acute ACL tears are

87% and 89%, respectively,<sup>29</sup> although the specificity has been reported to increase with higher quality 3.0T MRIs.<sup>30</sup> In addition to the coronal, sagittal and axial views, sagittal and coronal oblique views parallel to the course of the ligament are increasingly performed and used with MRI, which can be helpful for diagnosing ACL injuries.<sup>31-33</sup> Moreover, concomitant injuries, such as meniscus tears, PCL, MLC, LCL, ALL and posterolateral corner injuries, can also be visualized using MRI. This is important as these other injuries influence treatment and outcomes.

## **Treatment of Anterior Cruciate Ligament Injuries**

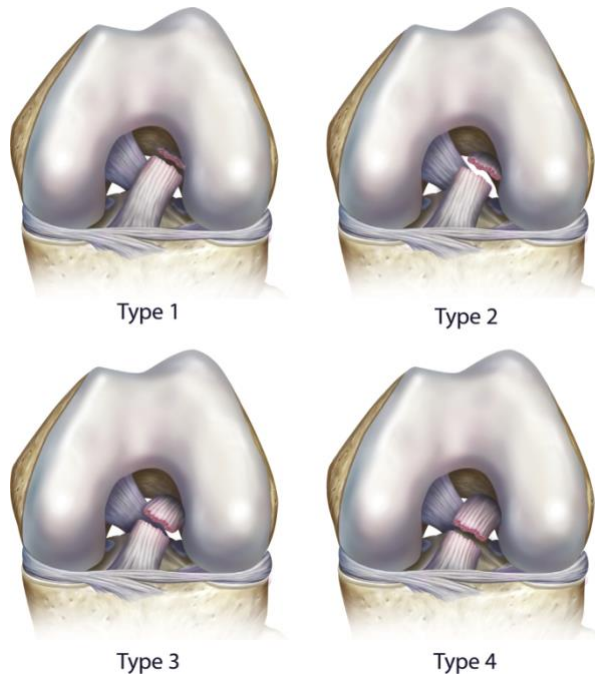
### **Historical overview**

The first surgical treatment of an ACL injury was performed by Mayo Robson in 1895.<sup>34</sup> In a 41-year-old male, who presented with proximal tears of both the ACL and PCL, Robson used catgut ligatures to stitch both ligaments back to the femoral wall. At six-year follow-up, the patient reported resolution of pain symptoms and excellent function.<sup>34</sup> In the 1930s and 1940s, Ivar Palmer further assessed the role of primary ACL repair and emphasized the importance of acute diagnosis of ACL injuries and repairing them primarily in his thesis *On the Injuries of the Ligaments of the Knee Joint*.<sup>35,36</sup> In the 1950s and early 1960s, Don O'Donoghue reported on the outcomes of acute repair of ACL injuries, which stimulated a shift from conservative treatment to surgical treatment using open primary repair.<sup>37,38</sup>

In the 1960s and early 1970s, several authors reported good short-term outcomes of primary repair.<sup>39-41</sup> In 1976, John Feagin and Walton Curl were the first to note a deterioration in their cohort at mid-term (5 year) follow-up.<sup>42</sup> They reported that 71% of patients had pain, 66% swelling, 71% stiffness and 94% instability. Following this study, others made several improvements in the surgical technique such as the usage of non-absorbable sutures and tying them directly over the femoral condyle. Although the results were not as inferior as found by Feagin and Curl, they also noted deterioration at longer follow-up.<sup>43-45</sup> After several prospective (randomized) studies in the late 1980s and early 1990s showed better and more predictable outcomes following ACL reconstruction compared to open primary ACL repair, the surgical treatment shifted from open primary ACL repair to open ACL reconstruction.<sup>46-51</sup>

At the end of the primary repair era in 1991, however, Sherman et al. published an important study on the outcomes of primary repair, which was considered a landmark paper by John Feagin.<sup>45</sup> Sherman et al. noticed the same deterioration in outcomes at longer follow-up and, uniquely, performed a subgroup analysis to understand this deterioration. Interestingly, they noted an association of better outcomes of primary repair in a subgroup of patients with proximal avulsion (type 1) and proximal (type 2) tears and better tissue quality when compared to midsubstance (type 3 and 4) tears, and suggested that primary repair may be a good treatment option in these patients (Figure 2). A few years later, in 1993, Genelin et al. treated patients with only proximal tears, and noted no deterioration and excellent outcomes

of open primary repair at mid-term follow-up.<sup>52</sup> Unfortunately, these findings were made relatively late, and because the aforementioned prospective (randomized) studies showed more predictable outcomes of ACL reconstruction than open primary repair, the treatment had already shifted from primary repair to reconstruction of the torn ACL.



**Figure 2.** The intraoperative classification system by Sherman et al. in 1991.<sup>44</sup> Type 1 tears were true proximal avulsion tears, type 2 tears had up to 20% of the ligament on the femoral wall, type 3 tears up to 33%, and type 4 tears had up to 50% of the ligament tissue on the femoral wall. With kind permission of Elsevier.<sup>52</sup>

## **Current treatments**

ACL injuries are these days be managed by conservative or surgical treatment, a choice that is often patient specific. For older, less active patients that are not involved in cutting or pivoting sports activities, conservative treatment is often a good choice. In younger or more active patients, however, conservative treatment leads to a low return to sports rate, high frequency of instability episodes, and a significant risk for meniscal tears and cartilage damage,<sup>54</sup> and therefore operative treatment is often pursued.

Over the last two to three decades, several modern developments have been made that have improved surgical treatment. Arthroscopic surgery has replaced open procedures for ACL surgery, which significantly reduces the morbidity, and MRI has become widely available for better preoperative diagnoses and patient counseling. Furthermore, with more knowledge on postoperative rehabilitation, it is now well understood that the knee should be mobilized early postoperatively to regain range of motion (ROM) and prevent stiffness, while in the era of open primary repair, the joint was immobilized with a cast for four to six weeks.

Over the last 25 years, single-bundle ACL reconstruction has been the gold standard of surgically treating ACL injuries for all patients ranging from children to sexagenarians. With this procedure, the torn ACL is removed and a graft is placed at the anatomic location of the native ACL. Autograft tissue, most commonly patellar tendon or hamstring tendons, and allograft tissue (older patients and multiligamentous injuries) can both be used for ACL reconstruction. The outcomes of ACL reconstruction are generally good as the instability is often restored following surgery.<sup>55</sup>

## **Problems with current treatments**

Although outcomes of ACL reconstruction surgery have been reported to be generally good and reliable with failure rates between 5 and 15%,<sup>56-59</sup> the surgical treatment algorithm of ACL injuries currently consists of “one size fits all” surgery that also has disadvantages. Firstly, autograft reconstruction necessitates graft harvesting, which can cause complications based on the type of graft. With patellar tendon grafts, anterior knee pain and kneeling pain are often reported, while the hamstring strength can decrease when using hamstring grafts and some studies have suggested higher failure rates with hamstring grafts.<sup>60-62</sup> Allograft reconstruction, on the other hand, has high failure rates and is not a reliable treatment in younger patients.<sup>63,64</sup> Secondly, the native ligament is removed along with its nerve endings and proprioception, and patients often experience a knee that does not feel like their native knee following ACL reconstruction.<sup>65</sup> Thirdly, reconstruction surgery does not restore the native kinematics,<sup>66-68</sup> and, as a result, it does not prevent<sup>69-71</sup> or might even increase<sup>72</sup> the risk for osteoarthritis when compared to conservative treatment. This is especially problematic, as most patients undergoing reconstructive surgery are young and active, and studies have shown an incidence of osteoarthritis up to 78% at 14-year follow-up.<sup>73</sup> Finally, despite the fact that acceptable failure rates are achieved in the general population, the

failure rates are very high in the patients younger than 20 to 25 years of age between 15 and 20%.<sup>58,59,74,75</sup> This is especially relevant, because when ACL reconstruction surgery fails, revision surgery is often difficult due to numerous factors such as pre-existing hardware, malpositioned or widened tunnels, and the unavailability of autologous grafts. As a result, the revision reconstruction outcomes are not as good as primary reconstruction outcomes.<sup>76-78</sup>

### **Primary repair over the last two decades**

Intuitively, the concept of preserving the native ACL makes sense if this is possible. Why remove the native ligament and replace it by a reconstructive graft if you can preserve it? This question has been the basis for numerous experimental and histological studies over the last two decades. Compared to ACL reconstruction, primary repair has several (theoretical) advantages. First of all, the native ligament is preserved with its nerve endings and proprioception, and this might restore native kinematics.<sup>79,80</sup> Secondly, this procedure is significantly less invasive than ACL reconstruction as no tunnels need to be drilled and no grafts need to be harvested. As a result, patients will not experience graft morbidity and have potentially less quadriceps atrophy which enables them to regain range of motion earlier postoperatively and potentially pass rehabilitation milestones quicker. Thirdly, the less invasive surgery and preservation of native tissues may decrease the risk of osteoarthritis and recent experimental studies have suggested to decrease the risk of osteoarthritis following primary repair.<sup>81,82</sup> This might be important as osteoarthritis has a high social and economic burden for patients and society. Finally, if ACL repair fails, “no bridges have been burned” for a primary reconstruction procedure. Therefore, primary repair could be considered an extra opportunity for a patient: if primary repair works, the patient benefits from a less invasive surgery in which the native tissues are preserved and patient experiences a normal sensation of the knee, and if primary repair fails, patients still can undergo “primary” reconstruction surgery.

Recent histological studies have shown that there is indeed healing capacity in the proximal region of the ACL.<sup>83,84</sup> The rationale for only repairing proximal tears is that the avulsed ligament can heal to the notch with the good vascularity at the proximal end of the ligament,<sup>4,83,84</sup> whereas midsubstance tears have a decreased likelihood of healing with inferior vascularity and the fact that the synovial fluid washes away the clot that is needed for healing.<sup>85</sup> These studies have revived the clinical interest for primary repair. In 2015, DiFelice et al. reported on the outcomes of primary repair using arthroscopy and when only treating patients with proximal (type 1) ACL tears.<sup>53</sup> In their pilot study, they noted one failure (9%) and excellent functional outcomes in the first 11 consecutive patients at minimum two-year follow-up. Although this study showed that arthroscopic primary ACL repair can be a good treatment option in selective patients, not much is currently known on which patients are candidates for this treatment, how often primary repair can be performed and how we can preoperatively identify these patients. Furthermore, more information is needed on the safety and postoperative course of this treatment and the outcomes and failure rates of primary



repair, especially since the outcomes in historical studies have deteriorated at mid-term follow-up. These gaps in our knowledge regarding arthroscopic primary repair have formed the foundation of this thesis.

## **Aims of this thesis**

The general aim of this thesis is to gain more insight in arthroscopic primary ACL repair. This thesis aims to review the history of open primary repair, assess patient selection, and assess the safety and early clinical outcomes of this procedure in order to understand the role of arthroscopic primary repair in the modern treatment algorithm of ACL injuries.

The following research questions were formulated for this thesis:

1. Which factors led to the abandoning of primary ACL repair in the historical literature?
2. Which patients are candidates for primary ACL repair, and can we identify these patients preoperatively?
3. What are the safety and early outcomes of arthroscopic primary ACL repair?

## **Outline of this thesis**

In **chapter 2**, we carefully reviewed the historical evolution of open primary repair. The goal was to understand why open primary repair was abandoned at the end of the 20<sup>th</sup> century in order to prevent repeating prior mistakes and assess potential bias and limitations in the historical literature. In **chapter 3**, we systematically assessed the role of tear location on the outcomes of open primary repair in historical studies to understand if the outcomes of open primary repair were, in hindsight, indeed better in patients with proximal ACL tears compared to patients with midsubstance ACL tears.

In **chapter 4**, the goal was to assess predictors of coping with ACL injury, including the role of tear location on the success of coping with ACL injury. This is important as primary repair will be performed in the more acute setting and conservative treatment cannot be performed when pursuing this treatment, and it is therefore important to assess the outcomes of non-operative treatment of the different tear types including proximal tears.

In **chapter 5**, we aimed to design a MRI classification system for tear locations of acute ACL injuries. Furthermore, we aimed to assess the incidence of different tear types in order to understand what number of patients may be candidates for primary ACL repair. In **chapter 6**, we aimed to assess the predictive role of tear types and tissue quality on MRI on the eligibility for arthroscopic primary ACL repair.

In **chapter 7**, we have aimed to assess which patients are candidates for arthroscopic primary repair and analyzed which patient and injury characteristics are predictive of the possibility of

undergoing primary repair. This obviously helps to critically select patients for primary ACL repair.

In **chapter 8**, the goal of the study was to assess the safety and postoperative course of primary ACL repair compared to the gold standard of single-bundle ACL reconstruction. We aimed to compare ROM, complications and operation time following both treatments. In **chapter 9**, we aimed to systematically review the outcomes of primary repair in the modern literature. The goal was to identify the different techniques that were used for primary repair in the literature, and assess the reported outcomes of these techniques.

In **chapter 10**, we aimed to assess the surgical outcomes of arthroscopic primary repair of proximal ACL tears in a larger cohort of patients with minimum two-year follow-up. Both the failure and reoperation rates, and the functional outcomes were assessed. Furthermore, a comparison was made between primary repair without augmentation and primary repair with additional augmentation to understand the effect of augmentation. In **chapter 11**, the objective was to assess the mid-term outcomes of arthroscopic primary ACL repair. As discussed in the historical overview in this general introduction, the historical studies on open primary repair noted good short-term outcomes, but a deterioration at mid-term follow-up had been reported. In this study, we followed the first eleven consecutive patients that had excellent short-term outcomes, and assessed if the outcomes remained good at the critical mid-term follow-up.

In **chapter 12**, the design of a randomized controlled trial is presented. The goal is to launch a multicenter Dutch initiative to prospectively compare the outcomes of primary repair versus reconstruction of proximal ACL tears while minimizing potential bias and confounders and to be able to critically appraise the findings presented in this thesis.

Finally, in **chapter 13**, the results and findings of all these studies are discussed and the research questions are answered. As a closure, the role of primary ACL repair in the current treatment algorithm will be discussed with the future directions for research on this topic. In the **appendix**, the surgical technique that was used in most of these studies is presented, along with a summary in English, summary in Dutch, PhD Portfolio, list of publications, acknowledgements and information about the author.

## References

1. Nayar SK, Dein EJ, Spiker AM, Bernard JA, Zikria BA. The top 100 cited articles in clinical orthopedic sports medicine. *Am J Orthop (Belle Mead NJ)*. 2015;44(8):E252-261.
2. Irarrazaval S, Albers M, Chao T, Fu FH. Gross, arthroscopic, and radiographic anatomies of the anterior cruciate ligament: Foundations for anterior cruciate ligament surgery. *Clin Sports Med*. 2017;36(1):9-23.
3. van der List JP, Nawabi DH, Pearle AD. Functional analysis of acl insertion site. In: Nakamura N, Zaffagnini S, Marx RG, Musahl V, editors. *Controversies in the technical aspects of acl reconstruction: An evidence-based medicine approach*: Springer Berlin Heidelberg; 2017. p. 181-192.
4. Toy BJ, Yeasting RA, Morse DE, McCann P. Arterial supply to the human anterior cruciate ligament. *J Athl Train*. 1995;30(2):149-152.
5. Schutte MJ, Dabezies EJ, Zimny ML, Happel LT. Neural anatomy of the human anterior cruciate ligament. *J Bone Joint Surg Am*. 1987 Feb;69(2):243-247.
6. Schultz RA, Miller DC, Kerr CS, Micheli L. Mechanoreceptors in human cruciate ligaments. A histological study. *J Bone Joint Surg Am*. 1984 Sep;66(7):1072-1076.
7. Georgoulis AD, Pappa L, Moebius U, Malamou-Mitsi V, Pappa S, Papageorgiou CO, Agnantis NJ, Soucacos PN. The presence of proprioceptive mechanoreceptors in the remnants of the ruptured acl as a possible source of re-innervation of the acl autograft. *Knee Surg Sports Traumatol Arthrosc*. 2001 Nov;9(6):364-368.
8. Raunest J, Sager M, Burgener E. Proprioceptive mechanisms in the cruciate ligaments: An electromyographic study on reflex activity in the thigh muscles. *J Trauma*. 1996 Sep;41(3):488-493.
9. van der List JP, Pearle AD. Mechanizing the pivot shift test. In: Musahl V, Karlsson J, Kuroda R, Zaffagnini S, editors. *Rotatory knee instability: An evidence based approach* Cham: Springer International Publishing; 2016. p. 255-268.
10. Zantop T, Herbort M, Raschke MJ, Fu FH, Petersen W. The role of the anteromedial and posterolateral bundles of the anterior cruciate ligament in anterior tibial translation and internal rotation. *Am J Sports Med*. 2007 Feb;35(2):223-227.
11. Lyman S, Koulouvaris P, Sherman S, Do H, Mandl LA, Marx RG. Epidemiology of anterior cruciate ligament reconstruction: Trends, readmissions, and subsequent knee surgery. *J Bone Joint Surg Am*. 2009;91(10):2321-2328.
12. Werner BC, Yang S, Looney AM, Gwathmey FW, Jr. Trends in pediatric and adolescent anterior cruciate ligament injury and reconstruction. *J Pediatr Orthop*. 2015;36(5):447-452.
13. Sanders TL, Maradit Kremers H, Bryan AJ, Larson DR, Dahm DL, Levy BA, Stuart MJ, Krych AJ. Incidence of anterior cruciate ligament tears and reconstruction: A 21-year population-based study. *Am J Sports Med*. 2016;44(6):1502-1507.
14. Gianotti SM, Marshall SW, Hume PA, Bunt L. Incidence of anterior cruciate ligament injury and other knee ligament injuries: A national population-based study. *J Sci Med Sport*. 2009;12(6):622-627.
15. Engelen-van Melick N, Hullegie W, Brooijmans F, Hendriks E, Neeter C, Van Tienen T, van Cingel R. Kngf evidence statement; revalidatie na voorste-kruisbandreconstructie. 2014.
16. Gould S, Hooper J, Strauss E. Anterior cruciate ligament injuries in females: Risk factors, prevention, and outcome. *Bull Hosp Jt Dis (2013)*. 2016 Mar;74(1):46-51.
17. Sayampanathan AA, Howe BK, Bin Abd Razak HR, Chi CH, Tan AH. Epidemiology of surgically managed anterior cruciate ligament ruptures in a sports surgery practice. *J Orthop Surg (Hong Kong)*. 2017 Jan;25(1):2309499016684289.
18. Boden BP, Dean GS, Feagin JA, Jr., Garrett WE, Jr. Mechanisms of anterior cruciate ligament injury. *Orthopedics*. 2000 Jun;23(6):573-578.
19. Speer KP, Warren RF, Wickiewicz TL, Horowitz L, Henderson L. Observations on the injury mechanism of anterior cruciate ligament tears in skiers. *Am J Sports Med*. 1995 Jan-Feb;23(1):77-81.
20. Grassi A, Smiley SP, Roberti di Sarsina T, Signorelli C, Marcheggiani Muccioli GM, Bondi A, Romagnoli M, Agostini A, Zaffagnini S. Mechanisms and situations of anterior cruciate ligament injuries in professional male soccer players: A youtube-based video analysis. *Eur J Orthop Surg Traumatol*. 2017 Jan 25.
21. DeMorat G, Weinhold P, Blackburn T, Chudik S, Garrett W. Aggressive quadriceps loading can induce noncontact anterior cruciate ligament injury. *Am J Sports Med*. 2004 Mar;32(2):477-483.
22. Kaeding CC, Leger-St-Jean B, Magnussen RA. Epidemiology and diagnosis of anterior cruciate ligament injuries. *Clin Sports Med*. 2017 Jan;36(1):1-8.
23. Galway HR, MacIntosh DL. The lateral pivot shift: A symptom and sign of anterior cruciate ligament insufficiency. *Clin Orthop Relat Res*. 1980 Mar-Apr(147):45-50.

24. Slocum DB, James SL, Larson RL, Singer KM. Clinical test for anterolateral rotary instability of the knee. *Clin Orthop Relat Res.* 1976 Jul-Aug(118):63-69.
25. van Eck CF, van den Bekerom MP, Fu FH, Poolman RW, Kerkhoffs GM. Methods to diagnose acute anterior cruciate ligament rupture: A meta-analysis of physical examinations with and without anaesthesia. *Knee Surg Sports Traumatol Arthrosc.* 2013 Aug;21(8):1895-1903.
26. Benjaminse A, Gokeler A, van der Schans CP. Clinical diagnosis of an anterior cruciate ligament rupture: A meta-analysis. *J Orthop Sports Phys Ther.* 2006 May;36(5):267-288.
27. Claes S, Luyckx T, Vereecke E, Bellemans J. The second fracture: A bony injury of the anterolateral ligament of the knee. *Arthroscopy.* 2014 Nov;30(11):1475-1482.
28. Fehnel DJ, Johnson R. Anterior cruciate injuries in the skeletally immature athlete. *Sports Medicine.* 2000;29(1):51-63.
29. Phelan N, Rowland P, Galvin R, O'Byrne JM. A systematic review and meta-analysis of the diagnostic accuracy of mri for suspected acl and meniscal tears of the knee. *Knee Surg Sports Traumatol Arthrosc.* 2016 May;24(5):1525-1539.
30. Van Dyck P, Vanhoenacker FM, Lambrecht V, Wouters K, Gielen JL, Dossche L, Parizel PM. Prospective comparison of 1.5 and 3.0-t mri for evaluating the knee menisci and acl. *J Bone Joint Surg Am.* 2013;95(10):916-924.
31. Barberie JE, Carson BW, Finnegan M, Wong AD. Oblique sagittal view of the anterior cruciate ligament: Comparison of coronal vs. Axial planes as localizing sequences. *J Magn Reson Imaging.* 2001 Sep;14(3):203-206.
32. Kosaka M, Nakase J, Toratani T, Ohashi Y, Kitaoka K, Yamada H, Komura K, Nakamura S, Tsuchiya H. Oblique coronal and oblique sagittal mri for diagnosis of anterior cruciate ligament tears and evaluation of anterior cruciate ligament remnant tissue. *Knee.* 2014;21(1):54-57.
33. Park HJ, Lee SY, Park NH, Ahn JH, Chung EC, Kim SJ, Cha JG. Three-dimensional isotropic t2-weighted fast spin-echo (vista) knee mri at 3.0 t in the evaluation of the anterior cruciate ligament injury with additional views: Comparison with two-dimensional fast spin-echo t2-weighted sequences. *Acta Radiol.* 2016;57(11):1372-1379.
34. Robson AW. Vi. Ruptured crucial ligaments and their repair by operation. *Ann Surg.* 1903;37(5):716-718.
35. Palmer I. On the injuries to the ligaments of the knee joint. *Acta Orthop Scand.* 1938;53.
36. Palmer I. On the injuries to the ligaments of the knee joint: A clinical study. 1938. *Clin Orthop Relat Res.* 2007;454:17-22.
37. O'Donoghue DH. Surgical treatment of fresh injuries to the major ligaments of the knee. *J Bone Joint Surg Am.* 1950;32 A(4):721-738.
38. O'Donoghue DH. An analysis of end results of surgical treatment of major injuries to the ligaments of the knee. *J Bone Joint Surg Am.* 1955;37(1):1-13.
39. Liljedahl SO, Lindvall N, Wetterfors J. Early diagnosis and treatment of acute ruptures of the anterior cruciate ligament; a clinical and arthrographic study of forty-eight cases. *J Bone Joint Surg Am.* 1965;47(8):1503-1513.
40. Feagin JA, Abbott HG, Rokous JR. The isolated tear of the anterior cruciate ligament. *J Bone Joint Surg Am.* 1972;54(6):1340-1341.
41. England RL. Repair of the ligaments about the knee. *Orthop Clin North Am.* 1976;7(1):195-204.
42. Feagin JA, Jr., Curl WW. Isolated tear of the anterior cruciate ligament: 5-year follow-up study. *Am J Sports Med.* 1976;4(3):95-100.
43. Straub T, Hunter RE. Acute anterior cruciate ligament repair. *Clin Orthop Relat Res.* 1988;227:238-250.
44. Kaplan N, Wickiewicz TL, Warren RF. Primary surgical treatment of anterior cruciate ligament ruptures. A long-term follow-up study. *Am J Sports Med.* 1990;18(4):354-358.
45. Sherman MF, Lieber L, Bonamo JR, Podesta L, Reiter I. The long-term followup of primary anterior cruciate ligament repair. Defining a rationale for augmentation. *Am J Sports Med.* 1991;19(3):243-255.
46. Odensten M, Hamberg P, Nordin M, Lysholm J, Gillquist J. Surgical or conservative treatment of the acutely torn anterior cruciate ligament. A randomized study with short-term follow-up observations. *Clin Orthop Relat Res.* 1985 (198):87-93.
47. Harilainen A, Myllynen P. Treatment of fresh tears of the anterior cruciate ligament. A comparison of primary suture and augmentation with carbon fibre. *Injury.* 1987;18(6):396-400.
48. Andersson C, Odensten M, Good L, Gillquist J. Surgical or non-surgical treatment of acute rupture of the anterior cruciate ligament. A randomized study with long-term follow-up. *J Bone Joint Surg Am.* 1989;71(7):965-974.

49. Engebretsen L, Benum P, Fasting O, Molster A, Strand T. A prospective, randomized study of three surgical techniques for treatment of acute ruptures of the anterior cruciate ligament. *Am J Sports Med.* 1990;18(6):585-590.
50. Jonsson T, Peterson L, Renstrom P. Anterior cruciate ligament repair with and without augmentation. A prospective 7-year study of 51 patients. *Acta Orthop Scand.* 1990;61(6):562-566.
51. Andersson C, Odensten M, Gillquist J. Knee function after surgical or nonsurgical treatment of acute rupture of the anterior cruciate ligament: A randomized study with a long-term follow-up period. *Clin Orthop Relat Res.* 1991 (264):255-263.
52. Genelin F, Trost A, Primavesi C, Knoll P. Late results following proximal reinsertion of isolated ruptured acl ligaments. *Knee Surg Sports Traumatol Arthrosc.* 1993;1(1):17-19.
53. DiFelice GS, Villegas C, Taylor SA. Anterior cruciate ligament preservation: Early results of a novel arthroscopic technique for suture anchor primary anterior cruciate ligament repair. *Arthroscopy.* 2015;31(11):2162-2171.
54. Frobell RB, Roos EM, Roos HP, Ranstam J, Lohmander LS. A randomized trial of treatment for acute anterior cruciate ligament tears. *N Engl J Med.* 2010;363(4):331-342.
55. Maletis GB, Inacio MC, Funahashi TT. Risk factors associated with revision and contralateral anterior cruciate ligament reconstructions in the kaiser permanente aclr registry. *Am J Sports Med.* 2015 Mar;43(3):641-647.
56. Li S, Chen Y, Lin Z, Cui W, Zhao J, Su W. A systematic review of randomized controlled clinical trials comparing hamstring autografts versus bone-patellar tendon-bone autografts for the reconstruction of the anterior cruciate ligament. *Arch Orthop Trauma Surg.* 2012 Sep;132(9):1287-1297.
57. Xie X, Liu X, Chen Z, Yu Y, Peng S, Li Q. A meta-analysis of bone-patellar tendon-bone autograft versus four-strand hamstring tendon autograft for anterior cruciate ligament reconstruction. *Knee.* 2015 Mar;22(2):100-110.
58. Sonnery-Cottet B, Saithna A, Cavalier M, Kajetanek C, Temponi EF, Daggett M, Helito CP, Thaunat M. Anterolateral ligament reconstruction is associated with significantly reduced acl graft rupture rates at a minimum follow-up of 2 years. *Am J Sports Med.* 2017 Feb 01;45(7):1547-1557.
59. Getgood AMJ, Bryant DM, Litchfield R, Heard M, McCormack RG, Rezansoff A, Peterson D, Bardana D, MacDonald PB, Verdonk PCM, Spalding T, Group SS, Willits K, Birmingham T, Hewison C, Wanlin S, Firth A, Pinto R, Martindale A, O'Neill L, Jennings M, Daniluk M, Boyer D, Zomar M, Moon K, Pritchett R, Payne K, Fan B, Mohan B, Buchko GM, Hiemstra LA, Kerslake S, Tynedal J, Stranges G, McRae S, Gullett L, Brown H, Legary A, Longo A, Christian M, Ferguson C, Mohtadi N, Barber R, Chan D, Campbell C, Garven A, Pulsifer K, Mayer M, Simunovic N, Duong A, Robinson D, Levy D, Skelly M, Shanmugaraj A, Howells F, Tough M, Spalding T, Thompson P, Metcalfe A, Asplin L, Dube A, Clarkson L, Brown J, Bolsover A, Bradshaw C, Belgrove L, Millan F, Turner S, Verdugo S, Lowe J, Dunne D, McGowan K, Suddens CM, Declercq G, Vuylsteke K, Van Haver M. Lateral extra-articular tenodesis reduces failure of hamstring tendon autograft anterior cruciate ligament reconstruction: 2-year outcomes from the stability study randomized clinical trial. *Am J Sports Med.* 2020 Feb;48(2):285-297.
60. Kraeutler MJ, Bravman JT, McCarty EC. Bone-patellar tendon-bone autograft versus allograft in outcomes of anterior cruciate ligament reconstruction: A meta-analysis of 5182 patients. *Am J Sports Med.* 2013;41(10):2439-2448.
61. Biau DJ, Tournoux C, Katsahian S, Schranz PJ, Nizard RS. Bone-patellar tendon-bone autografts versus hamstring autografts for reconstruction of anterior cruciate ligament: Meta-analysis. *BMJ.* 2006;332(7548):995-1001.
62. Rahr-Wagner L, Thillemann TM, Pedersen AB, Lind M. Comparison of hamstring tendon and patellar tendon grafts in anterior cruciate ligament reconstruction in a nationwide population-based cohort study: Results from the danish registry of knee ligament reconstruction. *Am J Sports Med.* 2014 Feb;42(2):278-284.
63. Kaeding CC, Aros B, Pedroza A, Pifel E, Amendola A, Andrish JT, Dunn WR, Marx RG, McCarty EC, Parker RD, Wright RW, Spindler KP. Allograft versus autograft anterior cruciate ligament reconstruction: Predictors of failure from a moon prospective longitudinal cohort. *Sports Health.* 2011;3(1):73-81.
64. Jacobs CA, Burnham JM, Makhni E, Malempati CS, Swart E, Johnson DL. Allograft augmentation of hamstring autograft for younger patients undergoing anterior cruciate ligament reconstruction. *Am J Sports Med.* 2017;45(4):892-899.
65. Behrend H, Zdravkovic V, Giesinger JM, Giesinger K. Joint awareness after acl reconstruction: Patient-reported outcomes measured with the forgotten joint score-12. *Knee Surg Sports Traumatol Arthrosc.* 2017 Oct 19;25(5):1454-1460.

66. Imhauser C, Mauro C, Choi D, Rosenberg E, Mathew S, Nguyen J, Ma Y, Wickiewicz T. Abnormal tibiofemoral contact stress and its association with altered kinematics after center-center anterior cruciate ligament reconstruction: An in vitro study. *Am J Sports Med.* 2013;41(4):815-825.
67. Logan MC, Williams A, Lavelle J, Gedroyc W, Freeman M. Tibiofemoral kinematics following successful anterior cruciate ligament reconstruction using dynamic multiple resonance imaging. *Am J Sports Med.* 2004 Jun;32(4):984-992.
68. Ristanis S, Stergiou N, Patras K, Vasiliadis HS, Giakas G, Georgoulis AD. Excessive tibial rotation during high-demand activities is not restored by anterior cruciate ligament reconstruction. *Arthroscopy.* 2005 Nov;21(11):1323-1329.
69. Ajuied A, Wong F, Smith C, Norris M, Earnshaw P, Back D, Davies A. Anterior cruciate ligament injury and radiologic progression of knee osteoarthritis: A systematic review and meta-analysis. *Am J Sports Med.* 2014;42(9):2242-2252.
70. Luc B, Gribble PA, Pietrosimone BG. Osteoarthritis prevalence following anterior cruciate ligament reconstruction: A systematic review and numbers-needed-to-treat analysis. *J Athl Train.* 2014;49(6):806-819.
71. Oiestad BE, Engebretsen L, Storheim K, Risberg MA. Knee osteoarthritis after anterior cruciate ligament injury: A systematic review. *Am J Sports Med.* 2009;37(7):1434-1443.
72. Kessler MA, Behrend H, Henz S, Stutz G, Rukavina A, Kuster MS. Function, osteoarthritis and activity after acl-rupture: 11 years follow-up results of conservative versus reconstructive treatment. *Knee Surg Sports Traumatol Arthrosc.* 2008;16(5):442-448.
73. Von Porat A, Roos EM, Roos H. High prevalence of osteoarthritis 14 years after an anterior cruciate ligament tear in male soccer players: A study of radiographic and patient relevant outcomes. *Ann Rheum Dis.* 2004;63(3):269-273.
74. Webster KE, Feller JA. Exploring the high reinjury rate in younger patients undergoing anterior cruciate ligament reconstruction. *Am J Sports Med.* 2016;44(11):2827-2832.
75. Dekker TJ, Godin JA, Dale KM, Garrett WE, Taylor DC, Riboh JC. Return to sport after pediatric anterior cruciate ligament reconstruction and its effect on subsequent anterior cruciate ligament injury. *J Bone Joint Surg Am.* 2017 Jun 07;99(11):897-904.
76. Lind M, Menhert F, Pedersen AB. Incidence and outcome after revision anterior cruciate ligament reconstruction: Results from the danish registry for knee ligament reconstructions. *Am J Sports Med.* 2012;40(7):1551-1557.
77. Lefevre N, Klouche S, Mirouse G, Herman S, Gerometta A, Bohu Y. Return to sport after primary and revision anterior cruciate ligament reconstruction. *Am J Sports Med.* 2017;45(1):34-41.
78. Kamath GV, Redfern JC, Greis PE, Burks RT. Revision anterior cruciate ligament reconstruction. *Am J Sports Med.* 2011;39(1):199-217.
79. Fleming BC, Carey JL, Spindler KP, Murray MM. Can suture repair of acl transection restore normal anteroposterior laxity of the knee? An ex vivo study. *J Orthop Res.* 2008 Nov;26(11):1500-1505.
80. Chahla J, Nelson T, Dallo I, Yalamanchili D, Eberlein S, Limpisvasti O, Mandelbaum B, Metzger MF. Anterior cruciate ligament repair versus reconstruction: A kinematic analysis. *Knee.* 2019;27(2):334-340.
81. Murray MM, Fleming BC. Use of a bioactive scaffold to stimulate anterior cruciate ligament healing also minimizes posttraumatic osteoarthritis after surgery. *Am J Sports Med.* 2013;41(8):1762-1770.
82. Strand T, Molster A, Hordvik M, Krukhaug Y. Long-term follow-up after primary repair of the anterior cruciate ligament: Clinical and radiological evaluation 15-23 years postoperatively. *Arch Orthop Trauma Surg.* 2005;125(4):217-221.
83. Nguyen DT, Geel J, Schulze M, Raschke MJ, Woo SL, van Dijk CN, Blankevoort L. Healing of the goat anterior cruciate ligament after a new suture repair technique and bioscaffold treatment. *Tissue Eng Part A.* 2013 Oct;19(19-20):2292-2299.
84. Nguyen DT, Ramwadhoebe TH, van der Hart CP, Blankevoort L, Tak PP, van Dijk CN. Intrinsic healing response of the human anterior cruciate ligament: An histological study of reattached acl remnants. *J Orthop Res.* 2014;32(2):296-301.
85. Murray MM. Current status and potential of primary acl repair. *Clin Sports Med.* 2009;28(1):51-61.

# Chapter 2

## **Primary repair of the anterior cruciate ligament: a paradigm shift**

Jelle P. van der List

Gregory S. DiFelice

*Surgeon. 2017 Jun;15(3):161-168.*

## **Abstract**

Over the last century, many surgical treatments have been developed in the orthopedic field, including treatments of anterior cruciate ligament (ACL) injuries. These treatments ideally evolve in a process of trial and error with prospective comparison of new treatments to the current treatment standard. However, these evolutions are sometimes not linear and periodically undergo paradigm shifts.

In this article, we review the evolution of ACL treatment and explain how it underwent a paradigm shift. Open primary ACL repair was the most common treatment in the 1970s and 1980s, but because multiple studies noted deterioration of outcomes at mid-term follow-up, in addition to several randomized clinical trials (RCTs) that noted better outcomes following ACL reconstruction, the open primary repair technique was abandoned.

At the end of the primary repair era, however, several studies showed that outcomes of open primary repair were good to excellent and did not deteriorate when this technique was selectively performed in patients with proximal ACL tears, whereas primary repair led to disappointing and unpredictable results in patients with midsubstance tears. Unfortunately, enrollment of patients in the aforementioned RCTs was already finished, ultimately leading to abandoning of open primary repair, despite the advantages of ligament preservation.

In this review, we discuss (I) why the evolution of ACL treatment underwent a paradigm shift, (II) which factors may have played a role in this and (III) what the future role of arthroscopic primary ACL repair is in the evolution of ACL treatments.



## Introduction

Over the last century, many surgical techniques and treatments have been developed in the field of orthopaedic surgery. These evolutions generally consist of a process of trial and error with (prospective) comparison of new treatments to the current treatment standard. If carefully executed and well documented, techniques with superior outcomes would then be further developed. More often, however, evolutions of surgical treatments undergo periodic “paradigm shifts” instead of progressing in a linear way. Thomas Kuhn described this in 1962<sup>1</sup> and stated that, because of these paradigm shifts, the scientific truth cannot only be determined by objective criteria but is defined by a consensus of a scientific community.

The evolution of anterior cruciate ligament (ACL) treatments started in 1895 when Mayo Robson reported on primary repair of an ACL injury.<sup>2</sup> A 41-year old male, who had both cruciate ligaments torn from the femoral wall, underwent primary repair in which the ligaments were stitched back to the femur using catgut ligatures. Over the following decades, Ivar Palmer<sup>3,4</sup> and Don O’Donoghue<sup>5,6</sup> further popularized primary repair for the treatment of ACL injuries. Following their work, open primary ACL repair was the most commonly performed surgical treatment in the 1970s and 1980s for ACL injuries<sup>7-12</sup>, and the initial short-term results of primary repair were good.<sup>9-15</sup> However, Feagin and Curl were the first to note that the results deteriorated at mid-term follow-up.<sup>16</sup> Reporting on only 50% of their original cohort, they found a 53% reinjury rate at five-year follow-up, along with high rates of pain, stiffness and instability. Following this study, some others also noted deterioration of the results at mid-term follow-up.<sup>17-19</sup> In addition, several randomized, prospective clinical trials showed better results following ACL reconstruction when compared to primary ACL repair.<sup>20-26</sup> Taken together, these studies led to the abandoning of open primary ACL repair as a treatment for ACL injury in the early 1990s, and also led to the eventual adoption of ACL reconstruction as the new standard for all patients. With primary repair, however, the native ligament is preserved and the surgery is less invasive, which has some advantages over ACL reconstruction, including maintaining proprioception<sup>27,28</sup> and preventing complications in graft harvesting, tunnel widening and revisions.<sup>29-31</sup>

The evolution of primary ACL repair is often believed to have been a natural and linear evolution of ACL treatments. However, with modern-day understanding we carefully reviewed the evolution and abandonment of primary ACL repair, and we noted that the evolution of treatment of ACL injuries underwent a paradigm shift. We feel that this shift led to the suboptimal treatment algorithm currently used for ACL injuries. In this article, we will discuss (I) why this evolution underwent a paradigm shift, (II) which factors may have contributed to this and (III) what the future role of primary repair might be in the evolution of ACL treatments.

## **Evolution of primary ACL repair through the prism of modern-day understanding**

Looking back at the evolution of primary ACL repair, several interesting observations can be made. The most important observation was made by Sherman et al., in 1991,<sup>19</sup> when they reported their mid-term results in what was considered a landmark paper on primary ACL repair.<sup>19</sup> The authors also noted a deterioration of their results at mid-term follow-up, although not as severe as in the cohort of Feagin and Curl, and they sought to find an explanation for this. They performed an extensive subgroup analysis and found a trend of better clinical results in certain subgroups of patients, including those with proximal (type I) tears. They were, however, not the first to note the role of tear location on the outcomes of primary ACL repair. Already in the early 1980s several authors suggested this correlation.<sup>12,13,32-34</sup> Weaver et al., for example, reported their outcomes of primary ACL repair in patients in the four Aspen skiing areas in 1985<sup>12</sup> and found that 52 of the 66 patients (79%) with proximal tears were satisfied following primary repair, while only 3 out of 13 patients (23%) with midsubstance tears reported being satisfied with the result at 3.5-year follow-up. They stated,<sup>12</sup>

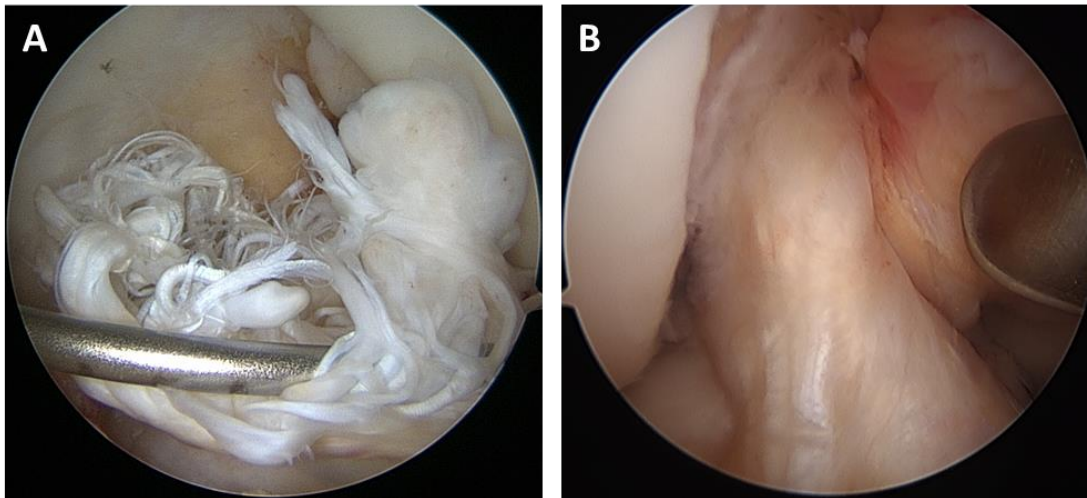
*“selection can be made with some predictability of the type of injury to the ligament as to which patients will do better.”*

Surprisingly, however, this study by Weaver et al., and other studies that suggested a role for proximal tears<sup>32-34</sup>, were not frequently cited and did not seem to be a part of the worldwide discussion in the literature regarding the treatment of ACL injuries.

### **Outcomes of open primary ACL repair stratified by tear location**

Many of the early authors did not specify the location of the ACL tear,<sup>16,35-38</sup> which is not surprising, since a possible relationship between tear location and outcomes was made relatively late in the evolution of primary ACL repair. When looking at studies that mainly, or only, treated patients with midsubstance tears (Figure 1A), it was noted that the results of primary ACL repair were poor. As mentioned, Weaver et al., showed only a 23% satisfaction rate in 13 patients with midsubstance tears. Frank et al., reported similar poor results of primary repair in 42 patients with midsubstance tears. At four-year follow-up, they reported that 22% of the patients had a positive pivot shift, 44% had a +2 or +3 anterior drawer test, and only 61% reported being satisfied with the procedure.<sup>39</sup> Odensten et al., reported the outcomes of primary repair in a subgroup of 22 patients with all midsubstance tears and noted a revision rate of 20% at 1.5-year follow-up.<sup>25</sup> Furthermore, Kaplan et al., reported their mid-term follow-up of 70 patients treated with primary ACL repair, of which 56 had midsubstance tears.<sup>18</sup> They reported a 17% failure rate, 42% laxity on KT-1000, and only a 62% return to sport rate. They concluded that,

*“although ... primary repair of the anterior cruciate may work in some patients, it is an unpredictable operative procedure.”*



**Figure 1. (A)** Arthroscopic view is shown with a “mop-end” midsubstance tear of the anterior cruciate ligament. Outcomes of primary repair of these tears were considered to be mixed and unpredictable.<sup>18</sup> **(B)** Arthroscopic view is shown with a “peel-off” proximal (type I) tear of the anterior cruciate ligament. These tears often have excellent tissue quality and outcomes of these tears are excellent.<sup>73</sup>

On the contrary, when reviewing studies that treated patients with mainly, or only proximal tears (Figure 1B), it was noted that good to excellent results were seen in the literature<sup>14,32,33,40-43</sup>. Kühne et al., reported treatment of 75 patients with proximal tears treated with primary ACL repair at four-year follow-up and reported 0% failure rate, negative pivot shift in 88% of the patients, a 0 or +1 Lachman test in 87% and a return to sports in 89% of patients.<sup>42</sup> Similarly, Genelin et al., reported their results of 42 patients treated with proximal tears at five- to seven-year follow-up.<sup>41</sup> They found negative pivot shift in 81% of patients, 0 or +1 Lachman test and anterior drawer test in 81% of cases, and reported that 86% of patients were satisfied with the procedure at mid-term follow-up. Raunest et al., reported outcomes of primary repair in 51 patients with proximal ACL tears at average 3.5-year follow-up. They noted 0% revisions, negative pivot shift and anterior drawer test in 84% of patients, return to sports in 71% and satisfaction in 75% of patients. These studies that reported results of treating patients with mostly proximal ACL tears showed that good to excellent results could clearly be achieved following open, primary ACL repair. In addition, Bram et al.,<sup>40</sup> and Genelin et al.,<sup>41</sup> showed that the results did not deteriorate at a mean follow-up of seven and six years, respectively. It seems that, when the decision was made to abandon primary repair due to marginal results, the surgical community did not recognize the role of tear location on the outcomes of primary repair.

### **Factors that played a role in this paradigm shift**

When reviewing the literature, and bearing in mind the findings of Sherman et al. and others, we identified several factors that may have contributed to why primary repair was abandoned

for all tears. Performing a search to identify studies that reported outcomes of primary ACL repair in the 1980s and 1990s, we encountered several limitations in identifying these studies. It must have been even harder for the orthopaedic surgeon in those days to be up to date on all studies, and therefore to make a well-informed decision regarding the optimal treatment for ACL injuries.

First of all, modern advances in computer technology enable us to use search engines, such as PubMed and Embase, to identify studies. The fact that search engine capabilities of the time were more rudimentary made it relatively difficult for the orthopaedic surgeon to be up to date on all the recent literature. Secondly, numerous authors reported outcomes of primary ACL repair in the 1980s and 1990s in their own language and, therefore, were neither easily readable, nor easily searchable at the time. With modern search engines, many Italian<sup>44,45</sup>, French<sup>46</sup>, Norwegian<sup>47</sup> and especially German<sup>32,40,42,48-52</sup>, studies were identified that were published on the topic of primary ACL repair in their respective languages. This could have led to the fact that most of these studies were not available, and thus, may not have been included in the worldwide discussion regarding ACL treatment. Finally, and perhaps most importantly, the nomenclature describing the procedure differed throughout the literature. Primary repair was sometimes referred to as “ACL reinsertion”,<sup>32,41,50,51</sup> instead of “ACL repair”. This makes sense because for proximal tears the ACL remnant could be described as being “reinserted” into the femoral footprint, whereas for midsubstance tears this was likely considered more of a true “repair” technique. It is likely that this nomenclature issue contributed to significant bias in the historical literature, since multiple positive outcome studies were largely omitted from the discussion in the English speaking literature<sup>32,41,50,51</sup>. Certainly the observations of poor accessibility and readability, in addition to the varying descriptive nomenclature, suggest that not all studies may have been used to make a well-informed decision regarding the abandonment of primary ACL repair for all patients instead of only abandoning this technique for midsubstance tears.

Taking these observations into account, and reviewing the results of open primary ACL repair stratified by tear location, it seems clear that the decision to abandon open primary ACL repair in favor of augmented ACL repair and eventually ACL reconstruction, was, at least partially, based on studies that did not factor in the importance of the tear type to the outcome of surgery.<sup>20-26</sup> When reviewing these results, it raises the question, “what would have happened if the observation of the importance of tear location was recognized earlier?” Intuitively, it makes sense that a more natural evolution of trial and error would have taken place. The technique of primary repair would have likely only been abandoned for midsubstance tears, whereas the repair techniques for patients with proximal tears would have been refined given the significantly better results that were actually reported in the world literature as discussed above.

## Unfortunate timing

The timing of abandoning primary ACL repair was an unlucky one for multiple reasons. First of all, the observations on tear type by Sherman et al., were made in 1991, which was relatively late in the evolution of primary ACL repair. With the introduction of augmented repair and reconstruction techniques, several randomized clinical trials were undertaken towards the end of the 1980s to determine the optimal treatment for ACL injuries.<sup>20-26</sup> At the time that Sherman et al., reported their findings, the enrollment of patients for these randomized clinical trials were already closed. These studies, therefore, did not stratify their results by tear location. It is likely that the majority of tears were midsubstance tears, since this is reportedly the most common tear type in the adult population (estimated to be between 70 and 90%, although observational studies assessing this are lacking).<sup>53-55</sup> With the critical role of tear location to the outcomes of primary ACL repair, combined with the fact that tear location does not play a role in ACL reconstruction where the entire ligament is removed, it is not surprising that superior outcomes of augmented repair and reconstruction were found when compared to primary repair.<sup>20-24</sup>

Furthermore, there was an increased interest in minimally invasive surgical techniques and improved rehabilitation techniques around this time. The surgical technique of primary ACL repair during the 1980s and 1990s consisted of an arthrotomy, which is an invasive and morbid procedure when compared to arthroscopic surgery.<sup>56-58</sup> It is intuitive that a significant contribution to the sub-optimal results of ACL treatment in the 1980s and 1990s could have been attributed to the morbidity of the arthrotomy, combined with immobilization. Although arthroscopy became available around the 1970s and 1980s, there were significant technologic limitations in the ability to control bleeding and reliably visualize and manipulate the internal anatomy of the joints. As with all innovations, it takes time until the technique can be developed sufficiently, and for the surgeon to become experienced enough to successfully utilize it. Despite the high pace of arthroscopic advances, the technology was not developed enough to reliably attempt arthroscopic primary repair in the early 1990s.<sup>59</sup> By the time arthroscopic surgery was more developed, primary repair had been abandoned and reconstruction had become the standard treatment for all ACL injuries.

Over the ensuing decades, ACL reconstruction benefited from, and evolved with the less invasive arthroscopic procedures, while primary ACL repair did not benefit from such development. Therefore, the question remains, “what would the outcomes of primary ACL repair have been if it had evolved to be performed arthroscopically.” Interestingly, Strand et al. recently reported their 20-year follow-up results on 81 patients with 71% good or excellent knee function, 13% reconstructions and 27% total failure of stability.<sup>60</sup> They stated,

*“...open procedures cannot be recommended for any type of patients. However, if the same results could be accomplished by a smaller, arthroscopic procedure, primary repair might reduce the number of patients needing later reconstructions with small ‘costs’ in the way of risk and inconvenience for the patients. We therefore believe that*

*further research and development of methods for closed (arthroscopic) repair are justified.”*

Similarly as for the invasive arthrotomy, it was noted that rehabilitation in the 1980s and 1990s consisted of joint immobilization for at least five or six weeks using a long leg cast.<sup>11,13,19,22,41,61,62</sup> The concept of early mobilization was being developed in the late 1980s and early 1990s<sup>63,64</sup>, and thus, most patients treated with primary ACL repair or ACL reconstruction around this time still received joint immobilization. However, it is now known that knee joint immobilization may cause pain, loss of range of motion and decreased function.<sup>65,66</sup> The technique of ACL reconstruction has evolved over three decades and early mobilization has significantly improved the results of ACL reconstruction.<sup>67-69</sup> However, studies reporting outcomes of primary ACL repair all used postoperative joint immobilization, which raises another question, “would the results of primary ACL repair have further improved if the repairs were performed only on patients with proximal tears, and they were mobilized early?” Indeed, Genelin et al., also noted this in their study on proximal ACL tears, which was one of the last original studies reporting results of primary ACL repair in 1994.<sup>41</sup> They stated,

*“nevertheless we believe that, even with the same operational technique, the results can be improved still further by early postoperative treatment with a continuous passive motion machine, combined with a brace providing limited knee joint motion.”*

Finally, the study by Feagin and Curl was often quoted by studies in the 1980s and 1990s, despite the fact that their methods were already outdated by the late 1970s. The authors used figure of eight absorbable sutures and secured the sutures over the iliotibial band.<sup>16,70</sup> The authors reported instability in 94% of the cases, and a reinjury rate of 53%, which is significantly worse than any other paper published on primary repair. More recent preclinical studies on ACL repair have shown that the strength of a repair significantly decreased when absorbable sutures were used, compared to non-absorbable sutures.<sup>71</sup> Not surprisingly, a few years later, Marshall and colleagues introduced a different technique using multiple looped, non-absorbable sutures that they tied directly over the bone of the femoral condyle without the iliotibial band between it.<sup>10,13</sup> The results in their studies were significantly better, even though most of these patients in their study had midsubstance tears.<sup>18,22,50</sup> It is likely that the use of absorbable sutures, the fact that only a figure of eight loop was used, and that the sutures were tied over the iliotibial band, could have worsened the results as reported by Feagin and Curl.<sup>16</sup> It is interesting to note that the study by Feagin and Curl is more often quoted than any other study on primary ACL repair and remained an important study leading to the abandonment of primary ACL repair, yet there were multiple aforementioned limitations regarding the surgical technique, including the high risk for selection bias given that they had only a 50% follow-up rate on the original cohort.

## The future role of primary repair in the evolution of ACL treatment

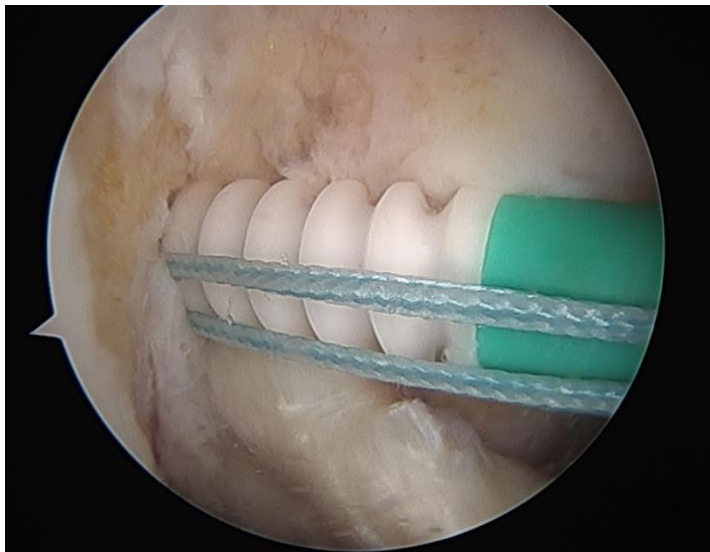
After the discussion in the historic literature regarding the limitations of open primary repair, one would expect that the results of primary ACL repair would have improved over the second part of the 1990s and into the next century. With the introduction of magnetic resonance imaging (MRI) for patient selection, with the advances made in arthroscopic surgery for a minimally invasive approach, and with improved rehabilitation understanding that focuses on early mobilization, both techniques of primary repair and reconstruction would have ideally been further developed and both techniques could have been used for proximal and midsubstance tears, respectively. However, over the last two decades no original cohorts have been started using primary repair<sup>72</sup>, and it is only very recently that studies have reported outcomes of arthroscopic primary repair<sup>73-75</sup> or primary repair augmented with an external device<sup>76-78</sup> or with an internal brace<sup>79-81</sup> (Table 1).

The first study of arthroscopic primary ACL repair was performed by DiFelice et al.<sup>73</sup> They reported a case series of 11 patients with proximal tears that were treated with arthroscopic suture anchor primary ACL repair (Figure 2).<sup>73</sup> They applied all modern developments and only treated patients with proximal tears that were predicted by MRI, utilized an arthroscopic, minimally invasive surgical approach using non-absorbable sutures, and their patients underwent rehabilitation focusing on early range of motion. Not surprisingly, after the discussion of these topics above, the authors found excellent results at a mean of 3.5-year follow-up. They reported a mean Lysholm score of 93.2, modified Cincinnati score of 91.5, pre- and postoperative Tegner score of 7.3 and 6.9, respectively, SANE score of 91.8 and subjective IKDC-score of 86.4. They reported only one clinical failure (9%) who had a KT-1000 leg difference of 6 mm. Nine patients had an objective IKDC A score, one an IKDC B score, and one an IKDC C score. Of the eight patients who had post-operative KT-1000 tests, all except the clinical failure, had <3mm side-to-side, maximum manual differences. The authors concluded that a modern approach to ACL preservation, using an arthroscopic suture anchor primary ACL repair technique, could achieve short-term clinical success in carefully selected patients. Although they did report good results in three patients with four- to five-year follow-up, they concluded that more studies are necessary to determine whether the clinical successes will be sustained at longer follow-up.

More recently, Achtnich et al. compared arthroscopic primary repair in 20 patients with proximal ACL tears and with single-bundle reconstruction in 20 patients with proximal ACL tears at 2.3-years follow-up.<sup>74</sup> Although this study was not randomized, they reported excellent stability testing and patient-reported outcome scores in both groups but a higher revision rate following primary repair (15% vs. 0%). Despite this higher revision rate, they concluded that in a significant amount of patients good results could be achieved with this minimally invasive treatment option of arthroscopic primary repair.

In this article, we discussed why we feel that the evolution of treating ACL injuries with primary ACL repair underwent a paradigm shift. We also described the flaws and biases in the historic

literature that may have led to the decision to abandon the technique of ACL primary repair for all patients. If we acknowledge the importance of tear location on outcomes of primary repair, the encouraging preliminary results by DiFelice et al.<sup>73</sup> and Achtnich et al.<sup>74</sup> and the modern developments, such as MRI, early motion rehabilitation and arthroscopy, then it certainly seems that a new approach to ACL treatment might be emerging. That is that primary ACL repair may be a good and minimally invasive solution for patients with proximal tears, whereas ACL reconstruction or augmentation is the preferred technique in patients with non-proximal tears.<sup>82</sup>



**Figure 2.** Arthroscopic view of a suture anchor primary ACL repair.



**Table 1.** Overview of studies reporting outcomes of primary repair and augmented repair (primary repair with augmentation using external device or graft tissue)

Authors	Year	Journal	Design	Surgery	No.	Age (y)	Fixation	FU (y)	Failure	Reop.*
<b>Primary repair of proximal tears</b>										
DiFelice et al. <sup>73</sup>	2015	Arthroscopy	Case series	Repair	11	37	Suture anchor	3.5	1 (9%)	1 (9%)
Achtnich et al. <sup>74</sup>	2016	Arthroscopy	Case control	Repair	20	30	Suture anchor	2.3	3 (15%)	4 (20%)
<b>Augmented repair of proximal tears using external device or graft tissue or internal</b>										
Anthony and Mackay <sup>79</sup>	2015	Orthop Muscul Syst	Case series	Repair	68	34	Internal Brace	1.0	1 (1%)	4 (6%)
Eggli et al. <sup>76</sup>	2015	KSSTA	Case series	Repair	10	25	DIS Device	2.0	1 (10%)	1 (10%)
Henle et al. <sup>77</sup>	2015	BMC Musc.	Case series	Repair	278	31	DIS Device	3.0	11 (4%)	78 (28%)
Eggli et al. <sup>78</sup>	2016	BMC Musc.	Case series	Repair	10	23	DIS Device	5.0	2 (20%)	6 (60%)
Smith et al. <sup>81</sup>	2016	KSSTA	Case reports	Repair	3	6	Internal Brace	1.5	0 (0%)	0 (0%)

No. indicates number of knees; FU, follow-up; y, years; reop., reoperation; recon., reconstruction; KSSTA, Knee Surg Sports Traumatol Arthroscopy; BMC Musc, BioMed Central Musculoskeletal Disorders; DIS, Dynamic Intraligamentary Stabilization

\* Reoperation includes failures and reoperations for removal of hardware or concomitant injuries

## **Conclusions**

When reviewing the historical outcomes of primary repair, it becomes clear that the evolution of ACL treatment underwent a paradigm shift. In hindsight, we have learned of multiple factors in the historical literature that negatively influenced the reported results of primary ACL repair, including: non-strict patient selection, invasive surgical techniques, prolonged joint immobilization, and the use of absorbable sutures. Furthermore, modern search engines enabled us to do a more thorough search of the world literature and identify more historical studies that reported excellent results of primary repair of proximal ACL lesions than were previously appreciated.

It is possible that, if this paradigm shift in ACL treatment had not occurred, these limitations would have been addressed, and an arthroscopic repair technique, focusing only on proximal tears and rehabilitation with an emphasis on early range of motion would have evolved. It is encouraging that the first results of arthroscopic primary repair of proximal ACL tears have been recently published and that the treatment may shift back to a treatment algorithm that takes tear location into account.

## **Conflict of interest**

J.P.L. has nothing to disclose. G.S.D. is a paid consultant for Arthrex (Naples, FL, USA).

## References

1. Kuhn TS. The structure of scientific revolutions. 1st ed. Neurath O, editor. Chicago and London: University of Chicago Press; 1962.
2. Robson AW. Vi. Ruptured crucial ligaments and their repair by operation. *Ann Surg.* 1903;37(5):716-718.
3. Palmer I. On the injuries to the ligaments of the knee joint. *Acta Chirurgica Scandinavica.* 1938;53.
4. Palmer I. On the injuries to the ligaments of the knee joint: A clinical study. 1938. *Clin Orthop Relat Res.* 2007;454:17-22; discussion 14.
5. O'Donoghue DH. An analysis of end results of surgical treatment of major injuries to the ligaments of the knee. *J Bone Joint Surg Am.* 1955;37(1):1-13.
6. O'Donoghue DH. Surgical treatment of fresh injuries to the major ligaments of the knee. *J Bone Joint Surg Am.* 1950;32 A(4):721-738.
7. Feagin JA, Abbott HG, Rokous JR. The isolated tear of the anterior cruciate ligament. *J Bone Joint Surg Am.* 1972;54(6):1340-1341.
8. Odensten M, Lysholm J, Gillquist J. Suture of fresh ruptures of the anterior cruciate ligament. A 5-year follow-up. *Acta Orthop Scand.* 1984;55(3):270-272.
9. England RL. Repair of the ligaments about the knee. *Orthop Clin North Am.* 1976;7(1):195-204.
10. Marshall JL, Warren RF, Wickiewicz TL, Reider B. The anterior cruciate ligament: A technique of repair and reconstruction. *Clin Orthop Relat Res.* 1979 (143):97-106.
11. Warren RF. Primary repair of the anterior cruciate ligament. *Clin Orthop Relat Res.* 1983 (172):65-70.
12. Weaver JK, Derkash RS, Freeman JR, Kirk RE, Oden RR, Matyas J. Primary knee ligament repair-revisited. *Clin Orthop Relat Res.* 1985 (199):185-191.
13. Marshall JL, Warren RF, Wickiewicz TL. Primary surgical treatment of anterior cruciate ligament lesions. *Am J Sports Med.* 1982;10(2):103-107.
14. Higgins RW, Steadman JR. Anterior cruciate ligament repairs in world class skiers. *Am J Sports Med.* 1987;15(5):439-447.
15. Sherman MF, Bonamo JR. Primary repair of the anterior cruciate ligament. *Clin Sports Med.* 1988;7(4):739-750.
16. Feagin JA, Jr., Curl WW. Isolated tear of the anterior cruciate ligament: 5-year follow-up study. *Am J Sports Med.* 1976;4(3):95-100.
17. Straub T, Hunter RE. Acute anterior cruciate ligament repair. *Clin Orthop Relat Res.* 1988;227:238-250.
18. Kaplan N, Wickiewicz TL, Warren RF. Primary surgical treatment of anterior cruciate ligament ruptures. A long-term follow-up study. *Am J Sports Med.* 1990;18(4):354-358.
19. Sherman MF, Lieber L, Bonamo JR, Podesta L, Reiter I. The long-term followup of primary anterior cruciate ligament repair. Defining a rationale for augmentation. *Am J Sports Med.* 1991;19(3):243-255.
20. Andersson C, Odensten M, Gillquist J. Knee function after surgical or nonsurgical treatment of acute rupture of the anterior cruciate ligament: A randomized study with a long-term follow-up period. *Clin Orthop Relat Res.* 1991 (264):255-263.
21. Andersson C, Odensten M, Good L, Gillquist J. Surgical or non-surgical treatment of acute rupture of the anterior cruciate ligament. A randomized study with long-term follow-up. *J Bone Joint Surg Am.* 1989;71(7):965-974.
22. Engebretsen L, Benum P, Fasting O, Molster A, Strand T. A prospective, randomized study of three surgical techniques for treatment of acute ruptures of the anterior cruciate ligament. *Am J Sports Med.* 1990;18(6):585-590.
23. Grontvedt T, Engebretsen L, Benum P, Fasting O, Molster A, Strand T. A prospective, randomized study of three operations for acute rupture of the anterior cruciate ligament. Five-year follow-up of one hundred and thirty-one patients. *J Bone Joint Surg Am.* 1996;78(2):159-168.
24. Grontvedt T, Engebretsen L. Comparison between two techniques for surgical repair of the acutely torn anterior cruciate ligament. A prospective, randomized follow-up study of 48 patients. *Scand J Med Sci Sports.* 1995;5(6):358-363.
25. Odensten M, Hamberg P, Nordin M, Lysholm J, Gillquist J. Surgical or conservative treatment of the acutely torn anterior cruciate ligament. A randomized study with short-term follow-up observations. *Clin Orthop Relat Res.* 1985 (198):87-93.

26. Sandberg R, Balkfors B, Nilsson B, Westlin N. Operative versus non-operative treatment of recent injuries to the ligaments of the knee. A prospective randomized study. *J Bone Joint Surg Am.* 1987;69(8):1120-1126.
27. Dhillon MS, Bali K, Prabhakar S. Differences among mechanoreceptors in healthy and injured anterior cruciate ligaments and their clinical importance. *Muscles Ligaments Tendons J.* 2012;2(1):38-43.
28. Barrett DS. Proprioception and function after anterior cruciate reconstruction. *J Bone Joint Surg Br.* 1991;73(5):833-837.
29. Busam ML, Provencher MT, Bach BR, Jr. Complications of anterior cruciate ligament reconstruction with bone-patellar tendon-bone constructs: Care and prevention. *Am J Sports Med.* 2008;36(2):379-394.
30. Aga C, Wilson KJ, Johansen S, Dornan G, La Prade RF, Engebretsen L. Tunnel widening in single- versus double-bundle anterior cruciate ligament reconstructed knees. *Knee Surg Sports Traumatol Arthrosc.* 2016.
31. Griffith TB, Allen BJ, Levy BA, Stuart MJ, Dahm DL. Outcomes of repeat revision anterior cruciate ligament reconstruction. *Am J Sports Med.* 2013;41(6):1296-1301.
32. Heim U, Bachmann B, Infanger K. Reinsertion of the anterior cruciate ligament or primary ligamentous plasty? *Helv Chir Acta.* 1982;48(5):703-708.
33. Strand T, Engesaeter LB, Molster AO, Raugstad TS, Stangeland L, Stray O, et al. Knee function following suture of fresh tear of the anterior cruciate ligament. *Acta Orthop Scand.* 1984;55(2):181-184.
34. Marcacci M, Spinelli M, Chiellini F, Buccolieri V. Notes on 53 cases of immediate suture of acute lesions of the anterior cruciate ligament. *Italian Journal of Sports Traumatology.* 1985;7(2):69-79.
35. Aho AJ, Lehto MU, Kujala UM. Repair of the anterior cruciate ligament. Augmentation versus conventional suture of fresh rupture. *Acta Orthop Scand.* 1986;57(4):354-357.
36. Engebretsen L, Benum P, Sundalsvoll S. Primary suture of the anterior cruciate ligament. A 6-year follow-up of 74 cases. *Acta Orthop Scand.* 1989;60(5):561-564.
37. Lysholm J, Gillquist J, Liljedahl SO. Long-term results after early treatment of knee injuries. *Acta Orthop Scand.* 1982;53(1):109-118.
38. Sommerlath K, Lysholm J, Gillquist J. The long-term course after treatment of acute anterior cruciate ligament ruptures. A 9 to 16 year followup. *Am J Sports Med.* 1991;19(2):156-162.
39. Frank C, Beaver P, Rademaker F, Becker K, Schachar N, Edwards G. A computerized study of knee-ligament injuries: Repair versus removal of the torn anterior cruciate ligament. *Can J Surg.* 1982;25(4):454-458.
40. Bram J, Plaschy S, Lutolf M, Leutenegger A. [The primary cruciate ligament suture--is the method outdated? Results in follow-up of 58 patients]. *Z Unfallchir Versicherungsmed.* 1994;87(2):91-109.
41. Genelin F, Trost A, Primavesi C, Knoll P. Late results following proximal reinsertion of isolated ruptured ACL ligaments. *Knee Surg Sports Traumatol Arthrosc.* 1993;1(1):17-19.
42. Kühne JH, Theermann R, Neumann R, Sagasser J. [Acute uncomplicated anterior knee instability. 2-5 year follow-up of surgical treatment]. *Unfallchirurg.* 1991;94(2):81-87.
43. Simonet WT, Sim FH. Repair and reconstruction of rotatory instability of the knee. *Am J Sports Med.* 1984;12(2):89-97.
44. Cabitza P, Colombo A, Verdoia C. Follow-up of results obtained with o'donoghue's technique in the repair of recent lesions of the anterior cruciate ligament. *Minerva Ortopedica.* 1978;29(12):579-583.
45. Costa P, Dall'Aglio S, Tedeschi C, Fontanesi G. [Comparison of simple suture and suture reinforced with semitendinous tendon in the treatment of acute lesions of the anterior cruciate ligament]. *Chir Organi Mov.* 1988;73(4):329-334.
46. Rosso R, Martinoli S. [Rupture of the anterior cruciate ligament at a peripheral hospital. Apropos of 70 cases]. *Helv Chir Acta.* 1989;56(1-2):63-66.
47. Haaverstad R, Salkowitsch B, Griegel K, Bergmann S, Engebretsen L. [Primary suture of the anterior cruciate ligament at a county hospital]. *Tidsskr Nor Laegeforen.* 1990;110(2):217-220.
48. Blatter G, Tissi R. [Does it make sense to suture the ruptured anterior cruciate ligament without augmentation?]. *Unfallchirurg.* 1991;17(4):232-235.
49. Seiler H, Frank HR. [Suture of the anterior cruciate ligament--what is the real value of this method?]. *Unfallchirurg.* 1993;96(9):443-450.

50. Raunest J, Derra E, Ohmann C. Long term results following primary reconstruction of the cruciate ligaments without augmentation. *Unfallchirurg*. 1989;17(3):166-174.
51. Gaudernak T, Schreinlechner U, Kwasny O, Leixnering M. Comparison between primary replacement of the anterior cruciate ligament and primary suture or reinsertion. *Hefte zur Unfallheilkunde*. 1984;167:174-178.
52. Müller HW, Simons M, Schilling H. Treatment of the cruciate ligament lesion following to a trauma to the knee. *Unfallchirurg*. 1986;14(5):265-275.
53. Vahey TN, Broome DR, Kayes KJ, Shelbourne KD. Acute and chronic tears of the anterior cruciate ligament: Differential features at mr imaging. *Radiology*. 1991;181(1):251-253.
54. Remer EM, Fitzgerald SW, Friedman H, Rogers LF, Hendrix RW, Schafer MF. Anterior cruciate ligament injury: Mr imaging diagnosis and patterns of injury. *Radiographics*. 1992;12(5):901-915.
55. Ng WH, Griffith JF, Hung EH, Paunipagar B, Law BK, Yung PS. Imaging of the anterior cruciate ligament. *World J Orthop*. 2011;2(8):75-84.
56. Cameron SE, Wilson W, St Pierre P. A prospective, randomized comparison of open vs arthroscopically assisted ACL reconstruction. *Orthopedics*. 1995;18(3):249-252.
57. Laffargue P, Delalande J, Maillet M, Vanhecke C, Decouls J. Anterior cruciate ligament reconstruction: Arthrotomy versus arthroscopy. *Rev Chir Orthop Reparatrice Appar Mot*. 1999;85(4):367-373.
58. Yip DK, Wong JW, Chien EP. Arthroscopic surgery in the posterior compartment of the knee: Suture fixation of anterior and posterior cruciate ligament avulsions. *Arthroscopy*. 2003;19(3):23e.
59. Fox JM, Sherman OH, Markolf K. Arthroscopic anterior cruciate ligament repair: Preliminary results and instrumented testing for anterior stability. *Arthroscopy*. 1985;1(3):175-181.
60. Strand T, Molster A, Hordvik M, Krukhaug Y. Long-term follow-up after primary repair of the anterior cruciate ligament: Clinical and radiological evaluation 15-23 years postoperatively. *Arch Orthop Trauma Surg*. 2005;125(4):217-221.
61. Andersson C, Odensten M, Gillquist J. Early arthroscopic evaluation of acute repair of the anterior cruciate ligament. *Arthroscopy*. 1989;5(4):331-335.
62. Cross MJ, Paterson RS, Capito CP. Acute repair of the anterior cruciate ligament with lateral capsular augmentation. *Am J Sports Med*. 1989;17(1):63-67.
63. Shelbourne KD, Nitz P. Accelerated rehabilitation after anterior cruciate ligament reconstruction. *J Orthop Sports Phys Ther*. 1992;15(6):256-264.
64. Anderson AF, Lipscomb AB. Analysis of rehabilitation techniques after anterior cruciate reconstruction. *Am J Sports Med*. 1989;17(2):154-160.
65. Enneking WF, Horowitz M. The intra-articular effects of immobilization on the human knee. *J Bone Joint Surg Am*. 1972;54(5):973-985.
66. Millett PJ, Wickiewicz TL, Warren RF. Motion loss after ligament injuries to the knee. Part i: Causes. *Am J Sports Med*. 2001;29(5):664-675.
67. Noyes FR, Mangine RE, Barber S. Early knee motion after open and arthroscopic anterior cruciate ligament reconstruction. *Am J Sports Med*. 1987;15(2):149-160.
68. McCarthy MR, Yates CK, Anderson MA, Yates-McCarthy JL. The effects of immediate continuous passive motion on pain during the inflammatory phase of soft tissue healing following anterior cruciate ligament reconstruction. *J Orthop Sports Phys Ther*. 1993;17(2):96-101.
69. Noyes FR, Berrios-Torres S, Barber-Westin SD, Heckmann TP. Prevention of permanent arthrofibrosis after anterior cruciate ligament reconstruction alone or combined with associated procedures: A prospective study in 443 knees. *Knee Surg Sports Traumatol Arthrosc*. 2000;8(4):196-206.
70. Feagin JA, Jr. The syndrome of the torn anterior cruciate ligament. *Orthop Clin North Am*. 1979;10(1):81-90.
71. Vavken P, Proffen B, Peterson C, Fleming BC, Machan JT, Murray MM. Effects of suture choice on biomechanics and physeal status after bioenhanced anterior cruciate ligament repair in skeletally immature patients: A large-animal study. *Arthroscopy*. 2013;29(1):122-132.
72. Taylor SA, Khair MM, Roberts TR, DiFelice GS. Primary repair of the anterior cruciate ligament: A systematic review. *Arthroscopy*. 2015;31(11):2233-2247.
73. DiFelice GS, Villegas C, Taylor SA. Anterior cruciate ligament preservation: Early results of a novel arthroscopic technique for suture anchor primary anterior cruciate ligament repair. *Arthroscopy*. 2015;31(11):2162-2171.

74. Achtnich A, Herbst E, Forkel P, Metzloff S, Sprenger F, Imhoff AB, Petersen W. Acute proximal anterior cruciate ligament tears: Outcomes after arthroscopic suture anchor repair versus anatomic single-bundle reconstruction. *Arthroscopy*. 2016;32(12):2562-2569.
75. DiFelice GS, van der List JP. Arthroscopic primary repair of proximal anterior cruciate ligament tears. *Arthrosc Tech*. 2016;5(5):E1057-E1061.
76. Egli S, Kohlhof H, Zumstein M, Henle P, Hartel M, Evangelopoulos DS, Bonel H, Kohl S. Dynamic intraligamentary stabilization: Novel technique for preserving the ruptured ACL. *Knee Surg Sports Traumatol Arthrosc*. 2015;23(4):1215-1221.
77. Henle P, Roder C, Perler G, Heitkemper S, Egli S. Dynamic intraligamentary stabilization (dis) for treatment of acute anterior cruciate ligament ruptures: Case series experience of the first three years. *BMC Musculoskelet Disord*. 2015;16:27.
78. Egli S, Roder C, Perler G, Henle P. Five year results of the first ten ACL patients treated with dynamic intraligamentary stabilisation. *BMC Musculoskelet Disord*. 2016;17:105.
79. Anthony IC, Mackay GM. Anterior cruciate ligament repair revisited. Preliminary results of primary repair with internal brace ligament augmentation: A case series. *Orthop Muscul Syst*. 2015;4(2).
80. Mackay GM, Blyth MJ, Anthony I, Hopper GP, Ribbans WJ. A review of ligament augmentation with the internalbrace: The surgical principle is described for the lateral ankle ligament and ACL repair in particular, and a comprehensive review of other surgical applications and techniques is presented. *Surg Technol Int*. 2015;26:239-255.
81. Smith JO, Yaseen SK, Palmer HC, Lord BR, Britton EM, Wilson AJ. Paediatric ACL repair reinforced with temporary internal bracing. *Knee Surg Sports Traumatol Arthrosc*. 2016;24(6):1845-1851.
82. Murray MM, Fleming BC. Biology of anterior cruciate ligament injury and repair: Kappa delta ann doner vaughn award paper 2013. *J Orthop Res*. 2013;31(10):1501-1506.

# Chapter 3

## **Role of tear location on outcomes of open primary repair of the anterior cruciate ligament: a systematic review of historical studies**

Jelle P. van der List

Gregory S. DiFelice

*Knee. 2017 Oct;24(5):898-908.*

## **Abstract**

### **Introduction**

The general opinion is that outcomes of open primary repair of the anterior cruciate ligament (ACL) in the historical literature were disappointing. Since good outcomes of primary repair of proximal tears have recently been reported, we aimed to assess the role of tear location on open primary repair outcomes in the historical literature.

### **Methods**

All studies reporting outcomes of open primary ACL repair published between the inception of PubMed, Embase and Cochrane and 2000 were identified. Studies were included if tear location was reported. Outcome scores, return to sports, stability examinations, failures and patient satisfaction were collected and reviewed in the total study cohort and in a subgroup of studies treating only proximal tears. Spearman correlation analysis was performed between the percentage of proximal tears in the studies and all outcomes.

### **Results**

Twenty-nine studies were included reporting outcomes of open primary in 1457 patients of which 72% had proximal and 23% midsubstance tears. Mean age was 30 years, 65% were males, and mean follow-up was 3.6 years. Good outcomes were noted in the total cohort, and excellent outcomes were noted following repair of proximal tears. Positive correlation was found between the percentage proximal tears in the studies and percentage satisfied patients ( $p=0.010$ ).

### **Conclusion**

Tear location seems to have played a role on the outcomes of open primary ACL repair. Outcomes of open primary repair in patients with proximal tears were excellent, which confirms there may be a potential role for primary repair as treatment for proximal ACL tears.



## Introduction

The first documented treatment of an anterior cruciate ligament (ACL) injury took place in 1895 using primary repair when Mayo Robson repaired both cruciate ligaments in a 41-year-old male using catgut ligatures after they were torn off the femoral wall<sup>1</sup>. Over the following decades, Ivar Palmer<sup>2</sup> and Don O'Donoghue<sup>3</sup> further popularized primary ACL repair as a treatment for ACL injuries. Preservation of the ligament via primary ACL repair was the most common treatment for ACL injuries throughout the early 1990s.<sup>4-9</sup>

Open primary repair outcomes were initially good at short-term follow-up.<sup>4,5</sup> Feagin and Curl were the first to notice that outcomes deteriorated at mid-term follow-up with their technique using figure-of-eight absorbable sutures and tying these over the iliotibial band.<sup>10</sup> A few years later, Marshall et al. used multiple looped non-absorbable sutures and tied them directly over the femoral condyle,<sup>6,7</sup> but despite these improvements and excellent short-term outcomes,<sup>11</sup> their outcomes also deteriorated at mid-term follow-up.<sup>12</sup> They concluded that

*“although ... primary repair of the anterior cruciate may work in some patients, it is an unpredictable operative procedure and resulted in a 17% failure rate.”<sup>12</sup>*

Several other studies echoed these findings of deterioration at longer follow-up.<sup>13,14</sup>

In 1991, Sherman et al. sought to find an explanation for both the unpredictable outcomes and the deterioration at mid-term follow-up by performing an exhaustive subgroup analysis.<sup>14</sup> They noted patients with proximal tears and excellent tissue quality were associated with better outcomes than patients with mid-substance tears and poor tissue quality. This was similar to the observations of others who suggested a role of tear location on the outcomes of primary ACL repair.<sup>9,15-17</sup> Unfortunately, this discovery was made relatively late in the evolution of this procedure and primary ACL repair was already abandoned as ACL reconstruction had become the gold standard for the treatment of ACL injuries.

These observations raise the question if the tear location could indeed be an explanation for both the unpredictable outcomes and the deterioration at mid-term follow-up. This is especially of interest since several studies recently reported excellent outcomes of arthroscopic primary repair of proximal ACL tears.<sup>18-21</sup> To the best of our knowledge, no systematic review or meta-analysis has assessed the role of tear location on outcomes of primary ACL repair. A systematic search of studies reporting outcomes of open primary repair was therefore performed with the goal to assess the role of tear location on the historical outcomes of open primary ACL repair. We hypothesized that better outcomes were reported in studies performing primary ACL repair of proximal tears when compared to studies performing primary repair of all tear types.

## **Methods**

The Preferred Reporting Items for Systematic Reviews and Meta-Analyses (PRISMA) guidelines were followed when performing this study.

### **Literature search**

A systematic search in the electronic search engines PubMed, Embase and Cochrane Library was performed for historical studies on open primary ACL repair. Following a preliminary search, the search algorithm “(ACL OR anterior cruciate ligament) AND (repair OR reinsertion OR suture)” was used on September 15, 2016. The search was limited for studies published before 2000 since the goal was to assess historical outcomes of open primary repair, and since a recent systematic review showed that no new studies of open primary repair have been performed in the twenty-first century.<sup>22</sup> The search was not limited to English studies since the preliminary search revealed several eligible non-English studies. After removing duplicates, two authors (J.P.L. and G.S.D.) reviewed all studies based on title and abstract. Eligible studies were then scanned for full-text on inclusion and exclusion criteria. References of full-text scanned articles were reviewed for other possibly eligible studies. Agreement was reached on inclusion and exclusion of all studies.

Inclusion criteria consisted of studies that (I) reported outcomes of open primary repair, (II) reported tear location, (III) and were minimum level IV studies. Exclusion criteria consisted of studies that (I) used intra-articular or extra-articular augmentation, (II) did not report tear location, (III) reported bony avulsion tears, and (IV) were review articles, abstracts, or podium presentations.

### **Quality of studies**

Level of evidence of included studies was determined using the adjusted Oxford Centre for Evidence-Based Medicine 2011 Levels of Evidence. The Methodological Index for NonRandomized Studies (MINORS) criteria were used to assess the methodological quality of studies.<sup>23</sup> Different languages, countries where studies were performed and terms that studies used to define primary repair were assessed.

### **Data extraction**

Collected baseline characteristics included author names, year of publication, number of knees available at follow-up, length of follow-up, age at surgery and gender. Tear location was in all included studies quantified as upper one-third tears, mid-substance tears and lower one-third tears. Bony avulsions were excluded from analysis. Collected outcome scores included Lysholm scores, percentage of patients with good or excellent Lysholm scores (i.e., >84 points of Lysholm score), mean Tegner scores, return to sport defined as return to previous level, percentage of patients with <3mm leg difference with the contralateral leg using KT-1000, percentage of patients with negative pivot shift, percentage of patients with grade 0/1

Lachman test and anterior drawer test, percentage of patients that were considered to have a failed primary repair or were revised and percentage of patients that were satisfied with their primary repair or scored good/excellent on patient satisfaction questionnaires. All data was collected in Excel 2011 (Microsoft Corp., Redmond, WA, USA) and weighted percentages were calculated (e.g., total patients return to sports / total patients × 100%). Outcomes were reported in percentages, or mean ± standard deviation (range, minimum – maximum).

Because no studies (statistically) compared outcomes of open primary repair based on the tear locations (as it was generally not known that tear location potentially played a role), the outcomes could not be separately reported in groups of proximal, midsubstance and distal tears. Therefore, no meta-analysis could be performed using Forest plots. Studies were therefore reviewed, and the mean or cumulative outcomes of all studies were reported. In addition, outcomes of studies that treated only proximal tears were separately reviewed to evaluate the hypothesis of better outcomes in studies treating only proximal tears.

### **Statistical analysis**

Statistical analysis was performed using SPSS Statistics 21.0 (SPSS Inc., Armonk, NY, USA). To describe the outcomes of studies, continuous variables were reported using mean ± standard deviation (range), and categorical data were reported in percentages. Two-sided Spearman correlation analysis was performed to assess correlations between percentage of proximal tears in the individual studies and the percentage of patients fulfilling the categorical data in the individual studies (for example, percentage of negative pivot shift in each of the individual studies). Outcomes of the correlation analysis were reported in correlation coefficient (CC) and p-value (with p<0.05 considered significant). The strength of the correlation was graded according to Evans<sup>24</sup> as “very weak” (0.00 – 0.19), “weak” (0.20 – 0.39), “moderate” (0.40 – 0.59), “strong” (0.60 – 0.79) or “very strong” (0.80 – 1.00).

# Results

## Literature Search

A flowchart of the inclusion and exclusion of studies is shown in Figure 1. A total of 932 studies were reviewed on title and abstract. After reviewing these studies on title, abstract and full-text, a total of 29 studies were included.<sup>9,11,12,14-17,25-46</sup> Ten studies treated only proximal tears and one study separately reported the outcomes of proximal tears, and these studies were additionally reviewed separately.<sup>9,15,17,39-46</sup>

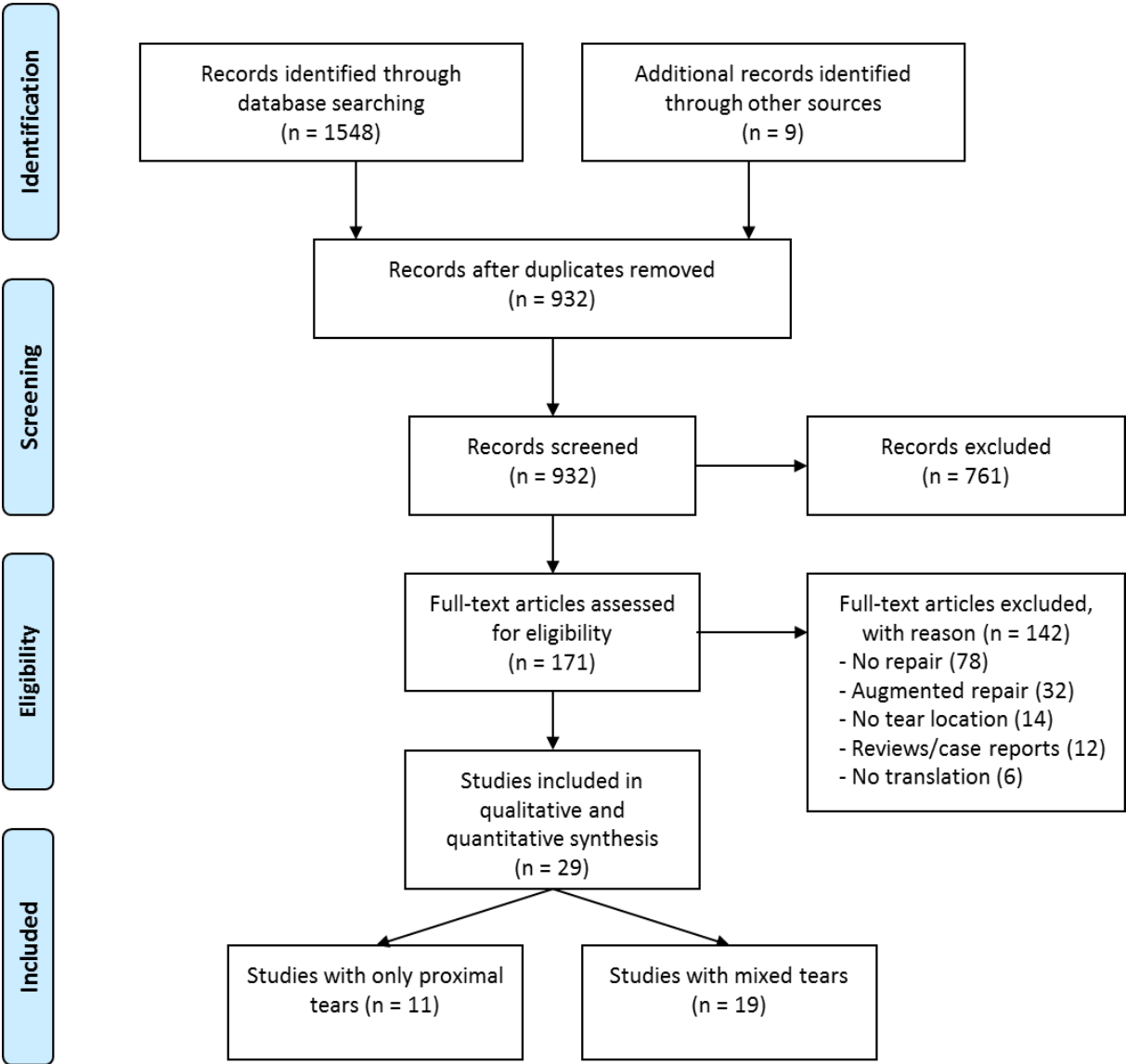


Figure 1. PRISMA flowchart of inclusion and exclusion of this study.

## Quality of studies

Four studies were level I studies<sup>26,34,35,37</sup>, two level II studies<sup>29,33</sup>, eight level III studies<sup>15,17,25,32,40,43,45,46</sup>, and 15 level IV studies<sup>9,11,12,14,16,27,28,30,31,36,38,39,41,42,44</sup>. The quality of studies is graded according to the MINORS criteria (Table 1). Most studies were lacking blinding, and none of the studies had a control group of different tear location. Eight studies were performed in Scandinavia<sup>16,26,27,34-38</sup>, six in the United States<sup>9,11,12,14,25,46</sup>, five in Germany<sup>28,32,39,43,44</sup>, four in Italy<sup>17,29,30,33</sup>, four in Switzerland<sup>15,31,42,45</sup> and two in Austria<sup>40,41</sup>. Most studies were written in the English language<sup>9,11,14,16,25-27,31,34,35,37,38,41,42,46</sup>, German<sup>15,28,32,39,40,43,44</sup>, Italian<sup>30,33</sup>, Norwegian<sup>36</sup>, French<sup>45</sup> or both the Italian and English<sup>17,29</sup> language. Terms to describe open primary repair differed between the studies with “primary suture”<sup>16,17,29,32,33,36-40</sup>, “primary repair”<sup>9,14,25,29-31,42,46</sup>, “reinsertion”<sup>15,40,41</sup> and “primary reconstruction”<sup>44</sup>.

## Baseline characteristics

For all included studies, 29 studies reported primary ACL repair outcomes in 1457 patients, of which 72% were proximal tears, 23% were midsubstance tears and 5% were distal tears. Mean age of these patients was 30±5.4 years (range, 11–72 years) and 65% of these patients were males. Mean length of follow-up was 3.6±1.7 years (range, 0.5–13 years). Eleven studies reported on outcomes of only proximal tears in 539 patients. Mean age in the proximal group was 31±5.8 years (range, 11–71 years), the percentage of males was 63% and mean length of follow-up was 3.9±1.8 years (range, 0.5–13 years) in this subgroup. All baseline characteristics are displayed in Table 2 (studies below the black line are the proximal studies).

## Lysholm scores

Ten studies reported mean Lysholm scores in 489 patients while nine studies reported percentage of good/excellent Lysholm scores in 398 patients. Mean Lysholm score was 87.8±5.0 (range, 77–97) and the percentage of good/excellent Lysholm score was 68.6%±16.6% (range, 34%–93%). No significant correlation was noted between the percentage of proximal tears in the studies and the percentage of good/excellent Lysholm scores, but this was not statistically significant (CC 0.233, p=0.546). Three studies treating only proximal tears reported a mean Lysholm score of 86.8±1.7 (range, 85–88) in 184 patients, and good/excellent Lysholm scores in 78.8%±2.3% (range, 76%–81%) of 151 patients.

**Table 1.** Quality assessment of the included studies using the Methodological Index for NonRandomized Studies (MINORS)

Authors	Year	Journal	Study design	1	2	3	4	5	6	7	8	Total
Liljedah <sup>27</sup>	1965	J Bone Joint Surg Am	Case Series	0	2	1	1	0	1	1	0	6
Cabitz <sup>30</sup>	1978	Minerva Ortopedica	Case Series	1	2	1	2	0	2	1	0	9
Frank <sup>25</sup>	1982	Can J Surg	Case Control	2	2	1	2	0	2	1	1	11
Heim <sup>15</sup>	1982	Helv Chirc Acta	Case Control	2	2	1	2	0	2	1	0	10
Marshall <sup>11</sup>	1982	Am J Sports Med	Case Series	2	2	1	2	0	2	1	0	10
Gerber <sup>42</sup>	1983	J Bone Joint Surg Br	Case Series	2	1	1	1	0	1	1	0	7
Gaudernak <sup>40</sup>	1984	Hefte Unfallheilkd	Cohort Study	1	2	1	0	0	0	1	0	5
Simonet <sup>46</sup>	1984	Am J Sports Med	Cohort Study	2	2	1	2	0	2	1	0	10
Strand <sup>16</sup>	1984	Acta Orthop Scand	Case Series	2	2	1	2	0	2	0	0	9
Marcacci <sup>17</sup>	1985	Ital J Sports Tramadol	Case Control	2	2	1	2	0	2	0	0	9
Odensten <sup>26</sup>	1985	Clin Orthop Relat Res	RCT	2	2	2	2	0	1	1	0	10
Weaver <sup>9</sup>	1985	Clin Orthop Relat Res	Case Series	2	2	1	1	0	2	1	0	9
Aglietti <sup>29</sup>	1986	Ital J Sports Tramadol	Cohort Study	2	2	2	1	0	2	1	0	10
Müller <sup>28</sup>	1986	Unfallchirurg	Case Series	2	2	1	1	0	1	1	0	7
Harilainen <sup>37</sup>	1987	Injury	RCT	2	2	2	2	0	1	1	0	10
Costa <sup>33</sup>	1988	Chir Organi Mov	Cohort Study	2	2	1	2	0	2	0	0	9
Rosso <sup>45</sup>	1989	Helv Chirc Acta	Cohort Study	2	2	1	1	0	2	1	0	9
Sherman <sup>14</sup>	1989	Am J Sports Med	Case Series	2	2	1	2	0	2	1	0	10
Ballmer <sup>31</sup>	1990	The Knee and Cruciate Ligaments	Case Series	2	1	0	2	0	2	0	0	7
Engbretsen <sup>34</sup>	1990	Am J Sports Med	RCT	2	2	2	2	0	2	2	2	14
Haaverstad <sup>36</sup>	1990	Tidsskr Nor Laegeforen	Case Series	2	2	1	2	0	2	0	0	9
Kaplan <sup>12</sup>	1990	Am J Sports Med	Case Series	2	2	1	2	0	2	1	0	10
Kühne <sup>43</sup>	1991	Unfallchirurg	Case Control	1	2	1	2	0	2	1	0	9
Raunest <sup>44</sup>	1991	Unfallchirurg	Case Series	2	1	1	2	0	2	0	0	8
Fruensgaard <sup>38</sup>	1992	Acta Orthop Scand	Case Series	2	2	1	2	0	2	1	0	10
Genelin <sup>41</sup>	1993	Knee Surg Sports Traum Arth	Case Series	2	2	1	2	0	2	1	0	10
Seiler <sup>32</sup>	1993	Unfallchirurg	Case Control	1	2	1	2	0	2	0	0	8
Bram <sup>39</sup>	1994	Z Unfallchir Versicherungsmed	Case Series	1	2	1	1	0	2	1	0	8
Grontvedt <sup>35</sup>	1996	J Bone Joint Surg Am	RCT	2	2	2	2	0	2	2	2	14

Only the non-comparative part of the MINORS criteria were used (i.e., first 8 questions), as no studies compared outcomes between different tear locations (i.e., proximal vs. midsubstance). Some studies compared repair vs. reconstruction but this control group was not considered relevant for this study. RCT indicates randomized clinical trial.

The criteria of MINORS <sup>23</sup> with 0 points when not reported, 1 when reported but not adequate, and 2 when reported and adequate. Maximum score is 24.

1. A clearly stated aim: the question addressed should be precise and relevant in the light of available literature.
2. Inclusion of consecutive patients: all patients potentially fit for inclusion (satisfying the criteria for inclusion) have been included in the study during the study period (no exclusion or details about the reasons for exclusion).
3. Prospective collection of data: data were collected according to a protocol established before the beginning of the study.
4. End points appropriate to the aim of the study: unambiguous explanation of the criteria used to evaluate the main outcome which should be in accordance with the question addressed by the study. In addition, the end points should be assessed on an intention-to-treat basis.
5. Unbiased assessment of the study end point: blind evaluation of objective end points and double-blind evaluation of subjective end points. Otherwise the reasons for not blinding should be stated.
6. Follow-up period appropriate to the aim of the study: the follow-up should be sufficiently long to allow the assessment of the main endpoint and possible adverse events.
7. Loss to follow-up less than 5%: all patients should be included in the follow-up. Otherwise, the proportion lost to follow-up should not exceed the proportion experiencing the major end point.
8. Prospective calculation of the study size: information of the size of detectable difference of interest with a calculation of 95% CI, according to the expected incidence of the outcome event, and information about the level for statistical significance and estimates of power when comparing the outcomes

### **Tegner scores**

Six studies reported Tegner scores in 311 patients and Tegner score in this study was  $5.3 \pm 0.6$  (range, 4.4–6.0). No significant correlation was noted between the percentage of proximal tears in the studies and better Tegner scores (CC 0.143,  $p=0.787$ ). One study treating only proximal tears in 75 patients reported a mean Tegner score of 5.8.

### **Return to sports**

Sixteen studies reported percentage of return to sports level in 788 patients. The percentage of patients that returned to sports was  $72.0\% \pm 13.7\%$  (range, 46%–100%). No significant correlation was noted between the percentage of proximal tears in the studies and the percentage of patients returning to their preinjury level of sports (CC 0.216,  $p=0.421$ ). Seven studies treating only proximal tears in 360 patients found  $80.0\% \pm 9.3\%$  (range, 67%–89%) of these patients returning to their preinjury level.

### **KT-1000 testing**

Six studies reported percentage of patients with  $<3\text{mm}$  leg difference with KT-1000 testing in 222 patients. The percentage of patients with  $<3\text{mm}$  leg difference in this study was  $49.5\% \pm 18.9\%$  (range, 29%–81%). No significant correlation was noted between the percentage of proximal tears in the studies and the percentage of patients with stable KT-1000 testing (CC 0.353,  $p=0.493$ ). One study treating only proximal tears in 42 patients reported that 81% of patients had stable knees on KT-1000 testing.

### **Pivot shift test**

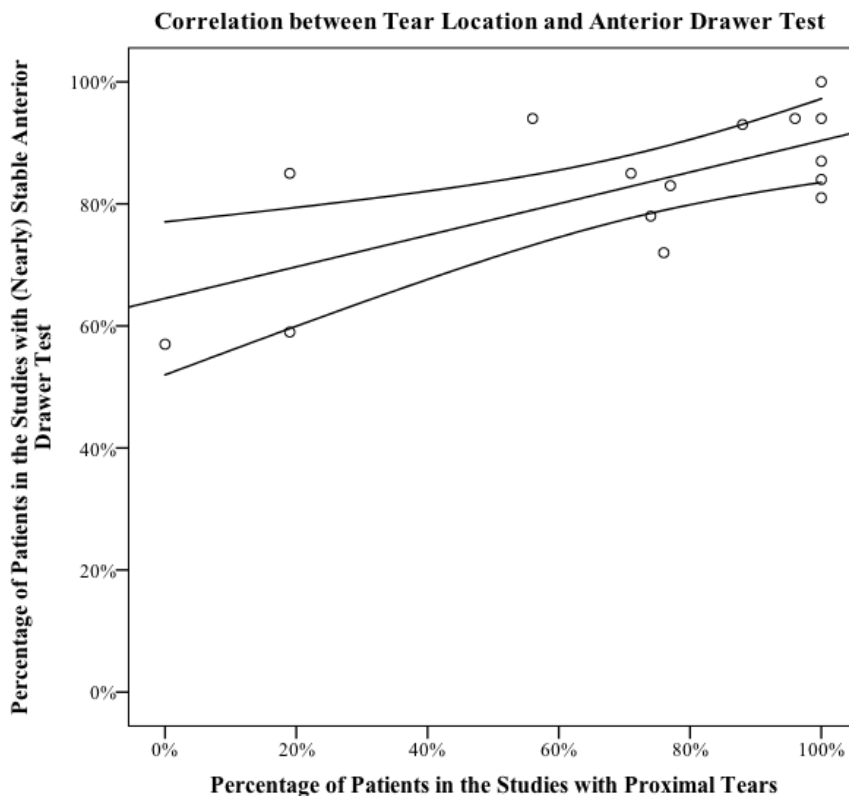
Nineteen studies reported pivot shift grades in 863 patients. Due to different reporting of outcomes, it was only possible to report percentage of patients with completely negative pivot shift grade. The percentage of patients with a negative pivot shift was  $64.9\% \pm 18.3\%$  (range, 25%–88%). No significant correlation was noted between the percentage of proximal tears in the studies and the percentage of patients with negative pivot examination (CC 0.289,  $p=0.230$ ). Seven studies treating only proximal tears in 185 patients reported that  $82.7\% \pm 8.3\%$  (range, 67%–88%) of these patients had negative pivot shift examination.

### **Lachman test**

Twenty studies reported Lachman test outcomes in 993 patients. Due to different reporting of outcomes in the studies, it was only possible to report percentage of patients with grade 0/1 Lachman test. The percentage of patients with grade 0/1 Lachman in all patients was  $80.9\% \pm 13.4\%$  (range, 53%–100%). No significant correlation between the percentage of proximal tears in the studies and the percentage of patients with (nearly) stable Lachman examination was noted (CC 0.090,  $p=0.705$ ). Seven studies treating only proximal tears in 315 patients reported that  $86.0\% \pm 9.3\%$  (range, 73%–96%) of patients with proximal tears had (nearly) stable Lachman examination.

## Anterior drawer test

Fifteen studies reported anterior drawer test outcomes in 722 patients. Similar to the Lachman tests, it was only possible to assess the percentage of patients with grade 0/1 anterior drawer test. The percentage of patients with grade 0/1 anterior drawer test was  $83.4\% \pm 12.6\%$  (range, 57%–100%). A non-significant trend towards a positive correlation was noted between the percentage of proximal tears in the studies and the percentage of patients with (nearly) stable anterior drawer examination (CC 0.489,  $p=0.064$ ) (Figure 2). Six studies treating only proximal tears in 251 patients reported that  $90.0\% \pm 7.3\%$  (range, 81%–100%) of patients with proximal tears had (nearly) stable anterior drawer examination.

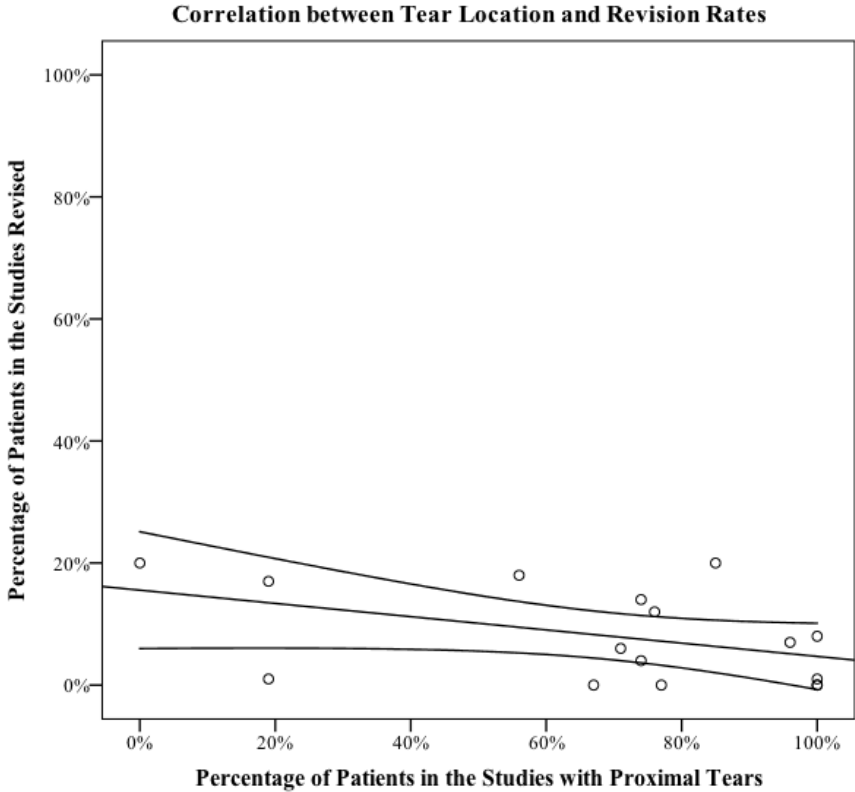


**Figure 2.** Correlation between the percentage of patients with proximal tears in the studies and the percentage of patients with a negative or 1+ anterior drawer test. Correlation coefficient 0.489,  $R^2=0.486$ ,  $p=0.064$ .



**Failure rates**

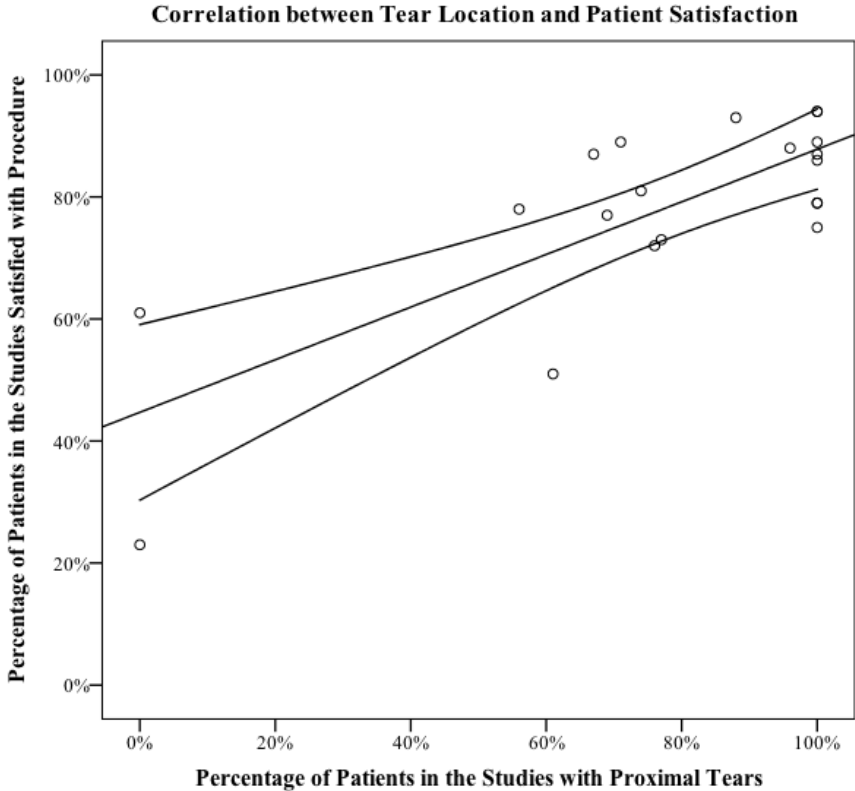
Sixteen studies reported failure rates in 885 patients. The percentage of patients that were considered to have a failed repair or were revised was  $6.8\% \pm 7.7\%$  (range, 0%–20%). A non-significant negative trend was noted between the percentage of proximal tears in the studies and the percentage of patients that had failure of the repair (CC -0.406,  $p=0.119$ ) (Figure 3). Five studies treating only proximal tears in 300 patients reported a failure rate of  $2.6\% \pm 3.9\%$  (range, 0%–8%) in proximal repair patients.



**Figure 3.** Correlation between the percentage of patients with proximal tears in the studies and the percentage of revisions that were needed for failures. Correlation coefficient -0.406,  $R^2=0.196$ ,  $p=0.119$ .

**Patient satisfaction**

Twenty studies reported the percentage of patients that were satisfied with primary repair in 883 patients. The overall percentage of satisfied patients was 79.7%±16.9% (range, 23%–94%). A moderate positive correlation between the percentage of proximal tears in the cohort studies and the percentage of satisfied patients was noted (CC 0.559, p=0.010) (Figure 4). Nine studies treating only proximal tears in 391 patients reported that 85.7%±6.9% (range, 75%–94%) of patients with proximal tears were satisfied.



**Figure 4.** Correlation between the percentage of patients with proximal tears in the studies and the percentage of satisfied patients in the studies is shown. Correlation coefficient 0.559, R<sup>2</sup>=0.598, p=0.010

**Table 2.** Outcomes of primary repair of anterior cruciate ligament of studies that reported tear location

Authors	Year	Knees at FU		FU (years)		Age (years)		Male (%)	Prox. (%)	Lysholm Mean	Tegner	RTS	KT-1000*	Pivot shift test (neg.)	Lachm. test (0/1)	Ant. draw. test (0/1)	Revised (%)	Satisfied (G/E)
		Mn.	Range	Mn	Range	Mn	Range											
Frank <sup>25</sup>	1982	42	4.2	1-10	32	18-72	76%	0%						78%		57%	20%	61%
Odensten <sup>26</sup>	1985	22	1.5	1-3	22	13-49	72%	0%									20%	23%
Weaver <sup>9</sup>	1985	13	3.5	3-6	32		31%	0%		6							17%	23%
Kaplan <sup>12</sup>	1990	56	6.8	5-13	27	14-49	73%	19%				62%	58%	71%	77%	85%	17%	23%
Marshall <sup>11</sup>	1982	70	2.4	1-8	27	13-50	71%	19%				69%		75%	100%	59%	1%	1%
Liljedahl <sup>27</sup>	1965	27	1.0	0.5-2		16-55	71%	23%				100%						
Sherman <sup>14</sup>	1989	50	5.1	4-7	23	15-56	70%	56%				78%	46%	50%	68%	94%	18%	78%
Müller <sup>28</sup>	1986	94	1.4	0.5-6	31	11-66	76%	61%						80%	87%		0%	51%
Aglietti <sup>29</sup>	1986	15	3.5	1-7	25	16-43	69%	67%		93%		79%					0%	87%
Cabitz <sup>30</sup>	1978	26	2.4	1-4	32	14-61	77%	69%									6%	77%
Ballmer <sup>31</sup>	1990	123	5.5	2-12	32	16-65	61%	71%				57%		49%	88%	85%	6%	89%
Seiler <sup>32</sup>	1993	88	3.7	2-6	30	15-57	58%	72%			4.4			82%	81%			
Costa <sup>33</sup>	1988	27	3.8	3-6	27	16-46	67%	74%				70%		56%	85%	78%		81%
Engelbretsen <sup>34</sup>	1990	50	2.0		29	16-50	58%	74%					29%	25%	53%		4%	
Grontvedt <sup>35</sup>	1996	41	6.0	5-7	29	16-50	58%	74%					34%	27%	56%		14%	
Haaverstad <sup>36</sup>	1990	25	3.0	1-6	37	17-71	64%	76%					58%	64%	76%	72%	12%	72%
Harilainen <sup>37</sup>	1987	29	1.1	1-2	31	15-51	53%	77%						55%	76%	83%	0%	73%
Fruensgaard <sup>38</sup>	1992	60	5.0	2-9	24	15-53	69%	85%				46%		66%	56%		20%	
Strand <sup>16</sup>	1984	60	4.0	1-6	44	15-70	57%	88%						78%	92%	93%		93%
Bram <sup>39</sup>	1994	58	7.0	2-13	35	16-62	55%	96%				76%			91%	94%	7%	88%
Gaudernak <sup>40</sup>	1984	72						100%							96%	94%		
Genelin <sup>41</sup>	1993	42	6.0	5-7	27		61%	100%							81%	81%		86%
Gerbe <sup>42</sup>	1983	15	1.9	0.5-6	43	26-62		100%							81%	81%		86%
Heim <sup>15</sup>	1982	86		1-6				100%							93%	87%		87%
Kühne <sup>43</sup>	1991	75	3.7	2-6	27	11-57	62%	100%							87%		1%	94%
Marcacci <sup>17</sup>	1985	19		1-4			66%	100%							87%		0%	0%
Raunest <sup>44</sup>	1991	51	3.5		33	14-71	67%	100%							74%	84%		79%
Rosso <sup>45</sup>	1989	38	3.3	1-7	29		71%	100%							73%		0%	75%
Simonet <sup>16</sup>	1984	17	2.2	2-3	24	17-40	79%	100%							73%	100%	8%	90%
Weaver <sup>9</sup>	1985	66	3.5	3-6	32		50%	100%							76%			94%
<b>All studies</b>		<b>1457</b>	<b>3.6</b>	<b>0.5-13</b>	<b>30</b>	<b>11-72</b>	<b>65%</b>	<b>72%</b>		<b>88</b>	<b>69%</b>	<b>72%</b>	<b>50%</b>	<b>65%</b>	<b>81%</b>	<b>83%</b>	<b>7%</b>	<b>80%</b>
<b>Studies with proximal tears</b>		<b>539</b>	<b>3.9</b>	<b>0.5-13</b>	<b>31</b>	<b>11-71</b>	<b>66%</b>	<b>100%</b>		<b>87</b>	<b>79%</b>	<b>80%</b>	<b>81%</b>	<b>83%</b>	<b>86%</b>	<b>90%</b>	<b>3%</b>	<b>86%</b>

FU indicates follow-up; Mn, mean; Prox., % of proximal tears; G/E, good/excellent; RTS, return to previous level of sports; \*, <3 mm leg difference with contralateral side; neg., negative; 0/1, grade 0/1.

## Discussion

This study has assessed the role of tear location on historical outcomes of open primary ACL repair. We systematically collected data from all studies reporting ACL tear location of patients undergoing open primary repair. The outcomes of open primary repair were reviewed in the total cohort and in studies treating only proximal tears. Data in this study suggest that open repair of ACL injuries resulted in good outcomes in the total cohort and excellent outcomes in proximal tears at short- and mid-term follow-up. Trends were also noted towards better anterior drawer examination, failure rates and satisfaction rates in studies with more proximal tears in their cohort.

Limitations are present in this study. First of all, it was not possible to statistically compare the different studies as no direct comparative studies of proximal versus midsubstance repair were identified. Therefore, we could only describe the different outcomes of open repair in all patients and in the subgroup of proximal tears. Secondly, we could not correct for potential confounders, such as surgical technique and concomitant injuries (meniscal injuries, chondral injuries, etc.) in this study, which could have influenced the trends that were noted. Other known confounders (age, gender and, more importantly, follow-up length) were not different between the total study cohort and the studies treating only proximal tears. Thirdly, despite recognizing a trend of better outcomes in the proximal tears, it is difficult to draw strong conclusions regarding the exact outcomes of both groups as the quality of studies was low. This can be explained by the fact that these studies were performed in the period of 1965 – 1996. Despite these limitations, we feel that, when reviewing the mean outcomes, correlation analyses and the ranges of the groups, this study shows better outcomes in studies with more proximal tears, which confirms and also justifies the current increased interest in primary repair of proximal tears.<sup>18-21,47,48</sup>

An often-reported problem with open primary ACL repair was the deterioration of outcomes at mid-term follow-up.<sup>10,12-14</sup> When reviewing all studies that had mean follow-up of 5.0 years or longer, significant similar differences were noted between the proximal and mixed groups. Genelin et al. and Bram et al. treated patients with proximal tears and reported excellent outcomes<sup>39,41</sup>. Genelin et al.<sup>41</sup> reported that 81% of patients had a negative pivot shift, grade 0/1 Lachman and anterior drawer test, while Bram et al.<sup>39</sup> reported a 91% grade 0/1 Lachman test, 94% grade 0/1 anterior drawer test, 76% return to sports and 7% failure rate at seven-year follow-up (1% per year)<sup>39</sup>. In the mixed group, however, five studies reported mid-term outcomes with very high failure rates<sup>12,14,31,35,38</sup>. Kaplan et al.<sup>12</sup> reported at 6.8-years follow-up a 62% return to sports and 17% failure rate. Sherman et al.<sup>14</sup> reported their outcomes in the mixed group in their landmark study with a negative pivot shift in only 50% of patients and an 18% failure rate. Ballmer et al. reported a 46% return to sports, 49% negative pivot shift and 6% failure rate at 5.5-year follow-up, Grontvedt et al.<sup>35</sup> reported at 6.0-year follow-up that only 27% had a negative pivot shift, 56% a stable or nearly stable Lachman test and a 14% failure rate while Fruensgaard et al.<sup>38</sup> reported a 46% return to previous level of sports, 66%

negative pivot shift and 56% stable or nearly stable Lachman test and a 20% failure rate. Most of these mixed studies reported revision rates of 2.5% – 4% per year. It not only seems that tear location played a role in the overall outcomes of open primary ACL repair but that also the mid-term results were better in studies that treated only proximal tears compared to studies that treated all types of tears.

Kaplan et al. performed open primary repair in patients with midsubstance tears and reported deterioration of their outcomes at mid-term follow-up with a 17% failure rate and 62% return to previous level of sports.<sup>12</sup> They concluded that open primary repair in these patients was an unpredictable procedure. Reviewing the results in our study, it was noted that the outcomes in the mixed group indeed had a greater variation, a larger range in outcomes than the proximal group and that the standard deviation was approximately twice the standard deviation of the proximal group. It therefore not only seems that outcomes of open primary repair in the proximal group were better than the mixed group, but that these outcomes were also more reliable when compared to midsubstance tears, as was already noted by Kaplan et al.<sup>12</sup>

The observations of better outcomes in proximal tears and less deterioration at mid-term follow-up could be explained several factors, including the vascularity of the ACL. The ACL gets most of its blood supply via a synovial membrane covering the ACL. The ACL is mostly vascularized by the middle genicular artery while the distal end is vascularized by the inferior genicular artery. Petersen and Hansen assessed the vascularity of the ACL and reported that the vascularity of the ACL is not homogeneous.<sup>49</sup> They noted that the richest blood supply is found in the proximal part of the ACL while they also noted that there is an avascularity at the junction of the middle and distal one-thirds, which is the watershed zone of middle and inferior genicular artery. This could also explain why some case reports<sup>50,51</sup> and case series<sup>52-54</sup> have reported spontaneous healing of proximal tears and perhaps also why better results at short-term and mid-term follow-up are seen in this current study. Studies assessing the role of ACL vascularity with different tear locations are necessary to confirm this hypothesis.

In our preliminary and final systematic search, we identified several reasons that may have contributed to the fact that the role of tear location on outcomes of primary repair was unknown for a long time. First of all, it was noted that a search with terms “anterior cruciate ligament” and “repair” would result in far fewer studies as are included now. This was especially true for studies that reported outcomes of proximal ACL repair, since many studies were in non-English languages, such as German and French. In the era of primary repair, this likely led to less understanding of others results and findings. Furthermore, it was noted that many studies used other terms rather than open primary repair, such as “reinsertion”, “suture” and even “primary reconstruction”, which likely added to the confusion. Finally, it was noted that only three out of eleven proximal repair studies were reported in large international journals at the time,<sup>9,42,46</sup> which also could have contributed to the fact that the role of tear location on open primary repair outcomes was not widely understood.<sup>55</sup>

Several studies had reported the deterioration of outcomes at mid- to long-term follow-up.<sup>10,12,13</sup> Therefore, randomized clinical trials were started in order to identify the optimal treatment for ACL injuries comparing open primary repair with open ACL reconstruction.<sup>34,35,37,56</sup> Unfortunately, enrollment of patients for these studies was already completed before 1991, when Sherman et al. and others published the potential role of tear location on outcomes, and it is therefore not surprising that many of these studies did not report tear location in their populations. Given the fact that midsubstance tears are reported to occur in approximately 50% – 60% of all adult ACL tears,<sup>14,57</sup> it is also not surprising that inferior results of primary ACL repair were reported when compared to ACL reconstruction.<sup>34,35,37,56</sup> This raises the question whether primary ACL repair was prematurely abandoned in favor of ACL reconstruction, and what the outcomes of these prospective randomized clinical trials would have been if only patients with proximal tears were treated with open primary repair.

It is difficult to compare results of this current study with more recent outcomes of ACL reconstruction. However, outcomes of this study in patients with proximal tears were relatively good, even by modern standards.<sup>58-60</sup> Even better results could be expected from primary ACL repair with modern advancements, such as arthroscopy and early rehabilitation motion protocols. In the included studies, patients were treated with arthrotomy and the historic standard was to postoperatively immobilize the knee joint with a lower leg cast for six weeks, which often results in stiffness, pain and suboptimal outcomes.<sup>61</sup> Recent studies with arthroscopy and early rehabilitation motion protocols indeed reported excellent outcomes of arthroscopic primary repair of proximal ACL tears.<sup>18,19,21,62-66</sup> DiFelice et al. reported a case series of eleven patients treated with arthroscopic primary ACL repair of proximal tears followed by an early motion rehabilitation protocol and they indeed reported good outcomes at 3.5-year follow-up.<sup>21</sup> Furthermore, Achtnich et al. performed arthroscopic primary repair of proximal tears and found equivalent functional outcomes and stability examination when compared to ACL reconstruction of proximal tears.<sup>18</sup> These studies, combined with the findings of this current systematic review, suggest that good to excellent outcomes are possible following primary repair of proximal tears. Future studies are necessary to assess the mid-term outcomes of modern arthroscopic primary repair in proximal tears, and compare these with the current gold standard of ACL reconstruction.

## **Conclusions**

This study assessed the role of tear location on outcomes of open primary ACL repair in historical studies and assessed outcomes of open primary ACL repair in proximal tears. The data showed that better outcomes were present in studies with a larger percentage of proximal tears in their cohorts, and that excellent results were noted in studies treating only proximal tears. These findings suggest that primary repair might be a reasonable treatment option for those patients with proximal ACL tears, especially when considering modern day advancements, such as arthroscopy and early motion rehabilitation protocols.

## **Conflict of interest**

Author G.S.D. declares to be a paid consultant for Arthrex. Author J.P.L. declares that he has no competing interests.

## References

1. Robson AW. Vi. Ruptured crucial ligaments and their repair by operation. *Ann Surg.* 1903;37(5):716-718.
2. Palmer I. On the injuries to the ligaments of the knee joint. *Acta Chirurgica Scandinavica.* 1938;53.
3. O'Donoghue DH. An analysis of end results of surgical treatment of major injuries to the ligaments of the knee. *J Bone Joint Surg Am.* 1955;37(1):1-13.
4. Feagin JA, Abbott HG, Rokous JR. The isolated tear of the anterior cruciate ligament. *J Bone Joint Surg Am.* 1972;54(6):1340-1341.
5. England RL. Repair of the ligaments about the knee. *Orthop Clin North Am.* 1976;7(1):195-204.
6. Marshall JL, Warren RF, Wickiewicz TL, Reider B. The anterior cruciate ligament: A technique of repair and reconstruction. *Clin Orthop Relat Res.* 1979 (143):97-106.
7. Warren RF. Primary repair of the anterior cruciate ligament. *Clin Orthop Relat Res.* 1983 (172):65-70.
8. Odensten M, Lysholm J, Gillquist J. Suture of fresh ruptures of the anterior cruciate ligament. A 5-year follow-up. *Acta Orthop Scand.* 1984;55(3):270-272.
9. Weaver JK, Derkash RS, Freeman JR, Kirk RE, Oden RR, Matyas J. Primary knee ligament repair--revisited. *Clin Orthop Relat Res.* 1985 (199):185-191.
10. Feagin JA, Jr., Curl WW. Isolated tear of the anterior cruciate ligament: 5-year follow-up study. *Am J Sports Med.* 1976;4(3):95-100.
11. Marshall JL, Warren RF, Wickiewicz TL. Primary surgical treatment of anterior cruciate ligament lesions. *Am J Sports Med.* 1982;10(2):103-107.
12. Kaplan N, Wickiewicz TL, Warren RF. Primary surgical treatment of anterior cruciate ligament ruptures. A long-term follow-up study. *Am J Sports Med.* 1990;18(4):354-358.
13. Straub T, Hunter RE. Acute anterior cruciate ligament repair. *Clin Orthop Relat Res.* 1988;227:238-250.
14. Sherman MF, Lieber L, Bonamo JR, Podesta L, Reiter I. The long-term followup of primary anterior cruciate ligament repair. Defining a rationale for augmentation. *Am J Sports Med.* 1991;19(3):243-255.
15. Heim U, Bachmann B, Infanger K. Reinsertion of the anterior cruciate ligament or primary ligamentous plasty? *Helv Chir Acta.* 1982;48(5):703-708.
16. Strand T, Engesaeter LB, Molster AO, Raugstad TS, Stangeland L, Stray O, Alho A. Knee function following suture of fresh tear of the anterior cruciate ligament. *Acta Orthop Scand.* 1984;55(2):181-184.
17. Marcacci M, Spinelli M, Chiellini F, Buccolieri V. Notes on 53 cases of immediate suture of acute lesions of the anterior cruciate ligament. *Ital J Sports Traumatol.* 1985;7(2):69-79.
18. Achtnich A, Herbst E, Forkel P, Metzclaff S, Sprenger F, Imhoff AB, Petersen W. Acute proximal anterior cruciate ligament tears: Outcomes after arthroscopic suture anchor repair versus anatomic single-bundle reconstruction. *Arthroscopy.* 2016;32(12):2562-2569.
19. van der List JP, DiFelice GS. Successful arthroscopic primary repair of a chronic anterior cruciate ligament tear 11 years following injury. *HSS J.* 2017;13(1):90-95.
20. van der List JP, DiFelice GS. The role of ligament repair in anterior cruciate ligament surgery. In: Mascarenhas R, Bhatia S, Lowe WR, editors. *Ligamentous injuries of the knee.* 1 ed. Houston: Nova Science Publishers; 2016. p. 199-220.
21. DiFelice GS, Villegas C, Taylor SA. Anterior cruciate ligament preservation: Early results of a novel arthroscopic technique for suture anchor primary anterior cruciate ligament repair. *Arthroscopy.* 2015;31(11):2162-2171.
22. Taylor SA, Khair MM, Roberts TR, DiFelice GS. Primary repair of the anterior cruciate ligament: A systematic review. *Arthroscopy.* 2015;31(11):2233-2247.
23. Slim K, Nini E, Forestier D, Kwiatkowski F, Panis Y, Chipponi J. Methodological index for non-randomized studies (minors): Development and validation of a new instrument. *ANZ J Surg.* 2003;73(9):712-716.
24. Evans JD. *Straightforward statistics for the behavioral sciences:* Brooks/Cole; 1996.
25. Frank C, Beaver P, Rademaker F, Becker K, Schachar N, Edwards G. A computerized study of knee-ligament injuries: Repair versus removal of the torn anterior cruciate ligament. *Can J Surg.* 1982;25(4):454-458.



26. Odensten M, Hamberg P, Nordin M, Lysholm J, Gillquist J. Surgical or conservative treatment of the acutely torn anterior cruciate ligament. A randomized study with short-term follow-up observations. *Clin Orthop Relat Res.* 1985 (198):87-93.
27. Liljedahl SO, Lindvall N, Wetterfors J. Early diagnosis and treatment of acute ruptures of the anterior cruciate ligament; a clinical and arthrographic study of forty-eight cases. *J Bone Joint Surg Am.* 1965;47(8):1503-1513.
28. Müller HW, Simons M, Schilling H. Treatment of the cruciate ligament lesion following to a trauma to the knee. *Unfallchirurg.* 1986;14(5):265-275.
29. Aglietti P, Buzzi R, Pisaneschi A, Salvi M. Comparison between suture and augmentation with the semitendinosus tendon in the repair of acute lesions of the anterior cruciate ligament. *Ital J Sports Tramadol.* 1986;8(4):217-231.
30. Cabitza P, Colombo A, Verdoia C. Follow-up of results obtained with o'donoghue's technique in the repair of recent lesions of the anterior cruciate ligament. *Minerva Ortopedica.* 1978;29(12):579-583.
31. Ballmer PM, Kipfer WC, Grünig B, Stäubli HU, Zehnder R, Jakob RP. Late results after primary repair. In: Jakob RP, Stäubli HU, editors. *The knee and the cruciate ligaments: Springer Berlin Heidelberg;* 1990. p. 293-298.
32. Seiler H, Frank HR. [Suture of the anterior cruciate ligament--what is the real value of this method?]. *Unfallchirurg.* 1993;96(9):443-450.
33. Costa P, Dall'Aglio S, Tedeschi C, Fontanesi G. [Comparison of simple suture and suture reinforced with semitendinous tendon in the treatment of acute lesions of the anterior cruciate ligament]. *Chir Organi Mov.* 1988;73(4):329-334.
34. Engebretsen L, Benum P, Fasting O, Molster A, Strand T. A prospective, randomized study of three surgical techniques for treatment of acute ruptures of the anterior cruciate ligament. *Am J Sports Med.* 1990;18(6):585-590.
35. Grontvedt T, Engebretsen L, Benum P, Fasting O, Molster A, Strand T. A prospective, randomized study of three operations for acute rupture of the anterior cruciate ligament. Five-year follow-up of one hundred and thirty-one patients. *J Bone Joint Surg Am.* 1996;78(2):159-168.
36. Haaverstad R, Salkowitsch B, Griegel K, Bergmann S, Engebretsen L. [Primary suture of the anterior cruciate ligament at a county hospital]. *Tidsskr Nor Laegeforen.* 1990;110(2):217-220.
37. Harilainen A, Myllynen P. Treatment of fresh tears of the anterior cruciate ligament. A comparison of primary suture and augmentation with carbon fibre. *Injury.* 1987;18(6):396-400.
38. Fruensgaard S, Kroner K, Riis J. Suture of the torn anterior cruciate ligament. 5-year follow-up of 60 cases using an instrumental stability test. *Acta Orthop Scand.* 1992;63(3):323-325.
39. Bram J, Plaschy S, Lutolf M, Leutenegger A. [The primary cruciate ligament suture--is the method outdated? Results in follow-up of 58 patients]. *Z Unfallchir Versicherungsmed.* 1994;87(2):91-109.
40. Gaudernak T, Schreinlechner U, Kwasny O, Leixnering M. Comparison between primary replacement of the anterior cruciate ligament and primary suture or reinsertion. *Hefte zur Unfallheilkunde.* 1984;NO. 167:174-178.
41. Genelin F, Trost A, Primavesi C, Knoll P. Late results following proximal reinsertion of isolated ruptured ACL ligaments. *Knee Surg Sports Traumatol Arthrosc.* 1993;1(1):17-19.
42. Gerber C, Matter P. Biomechanical analysis of the knee after rupture of the anterior cruciate ligament and its primary repair. An instant-centre analysis of function. *J Bone Joint Surg Br.* 1983;65(4):391-399.
43. Kühne JH, Theermann R, Neumann R, Sagasser J. [Acute uncomplicated anterior knee instability. 2-5 year follow-up of surgical treatment]. *Unfallchirurg.* 1991;94(2):81-87.
44. Raunest J, Derra E, Ohmann C. Long term results following primary reconstruction of the cruciate ligaments without augmentation. *Unfallchirurg.* 1989;17(3):166-174.
45. Rosso R, Martinoli S. [Rupture of the anterior cruciate ligament at a peripheral hospital. Apropos of 70 cases]. *Helv Chir Acta.* 1989;56(1-2):63-66.
46. Simonet WT, Sim FH. Repair and reconstruction of rotatory instability of the knee. *Am J Sports Med.* 1984;12(2):89-97.
47. van der List JP, DiFelice GS. Gap formation following primary anterior cruciate ligament repair: A biomechanical study. *Knee.* 2017;24(2):243-249.
48. Everhart JS, Sojka JH, Kaeding CC, Bertone AL, Flanigan DC. The ACL injury response: A collagen-based analysis. *Knee.* 2017;24(3):601-607.

49. Petersen W, Hansen U. Blood and lymph supply of the anterior cruciate ligament: Cadaver study by immunohistochemical and histochemical methods. *Journal of orthopaedic science*. 1997;2(5):313-318.
50. Kurosaka M, Yoshiya S, Mizuno T, Mizuno K. Spontaneous healing of a tear of the anterior cruciate ligament. A report of two cases. *J Bone Joint Surg Am*. 1998;80(8):1200-1203.
51. Nawabi DH, Patel RV, Hall-Craggs M, Haddad FS. MRI-confirmed tear and spontaneous healing of the anterior cruciate ligament. *Injury Extra*. 2006;37(3):125-128.
52. Costa-Paz M, Ayerza MA, Tanoira I, Astoul J, Muscolo DL. Spontaneous healing in complete ACL ruptures: A clinical and MRI study. *Clin Orthop Relat Res*. 2012;470(4):979-985.
53. Fujimoto E, Sumen Y, Ochi M, Ikuta Y. Spontaneous healing of acute anterior cruciate ligament (ACL) injuries - conservative treatment using an extension block soft brace without anterior stabilization. *Arch Orthop Trauma Surg*. 2002;122(4):212-216.
54. Ihara H, Miwa M, Deya K, Torisu K. MRI of anterior cruciate ligament healing. *J Comput Assist Tomogr*. 1996;20(2):317-321.
55. van der List JP, DiFelice GS. Primary repair of the anterior cruciate ligament: A paradigm shift. *Surgeon*. 2017;15(3):161-168.
56. Jonsson T, Peterson L, Renstrom P. Anterior cruciate ligament repair with and without augmentation. A prospective 7-year study of 51 patients. *Acta Orthop Scand*. 1990;61(6):562-566.
57. van der List JP, Mintz DN, DiFelice GS. The location of anterior cruciate ligament tears: A prevalence study using magnetic resonance imaging. *Orthop J Sports Med*. 2017.
58. Ardern CL, Webster KE, Taylor NF, Feller JA. Return to sport following anterior cruciate ligament reconstruction surgery: A systematic review and meta-analysis of the state of play. *Br J Sports Med*. 2011;45(7):596-606.
59. Hu J, Qu J, Xu D, Zhang T, Zhou J, Lu H. Clinical outcomes of remnant preserving augmentation in anterior cruciate ligament reconstruction: A systematic review. *Knee Surg Sports Traumatol Arthrosc*. 2014;22(9):1976-1985.
60. Mulford JS, Hutchinson SE, Hang JR. Outcomes for primary anterior cruciate reconstruction with the quadriceps autograft: A systematic review. *Knee Surg Sports Traumatol Arthrosc*. 2013;21(8):1882-1888.
61. Millett PJ, Wickiewicz TL, Warren RF. Motion loss after ligament injuries to the knee. Part i: Causes. *Am J Sports Med*. 2001;29(5):664-675.
62. van der List JP, DiFelice GS. Preservation of the anterior cruciate ligament: A treatment algorithm based on tear location and tissue quality. *Am J Orthop (Belle Mead NJ)*. 2016;45(7):E393-E405.
63. van der List JP, DiFelice GS. Range of motion and complications following primary repair versus reconstruction of the anterior cruciate ligament. *Knee*. 2017.
64. DiFelice GS, van der List JP. Regarding "acute proximal anterior cruciate ligament tears: Outcomes after arthroscopic suture anchor repair versus anatomic single-bundle reconstruction". *Arthroscopy*. 2017;33(4):693-694.
65. Bigoni M, Gaddi D, Gorla M, Munegato D, Pungitore M, Piatti M, Turati M. Arthroscopic anterior cruciate ligament repair for proximal anterior cruciate ligament tears in skeletally immature patients: Surgical technique and preliminary results. *Knee*. 2017;24(1):40-48.
66. Smith JO, Yasen SK, Palmer HC, Lord BR, Britton EM, Wilson AJ. Paediatric ACL repair reinforced with temporary internal bracing. *Knee Surg Sports Traumatol Arthrosc*. 2016;24(6):1845-1851.

# Chapter 4

**Age, activity level and meniscus injury, but not tear location, tibial slope or anterolateral ligament injury predict coping with anterior cruciate ligament injury**

Jelle P. van der List

Frans J.A. Hagemans

Hendrik A. Zuiderbaan

Cornelis F. van Dijke

Maarten V. Rademakers

Arthur van Noort

Gino M.M.J. Kerkhoffs

*Knee. 2021 Mar;30(2):222-232.*

## **Abstract**

### **Introduction**

Early recognition of potential predictors on the success of conservative treatment of anterior cruciate ligament (ACL) is important, as appropriate treatment can be applied to each individual patient. The goal of this study is to assess the patient demographic and radiological parameters that predict coping with ACL injuries.

### **Methods**

All patients presenting with a complete ACL injury between 2014 and 2018 at our clinic were included. The role of patient demographics (age, gender, activity level, meniscus injury and time from injury to clinic), and ACL tear location, bone bruises, tibial slope, and anterolateral ligament (ALL) injury were assessed on the success of conservative treatment using univariate and multivariate analyses.

### **Results**

Sixty-five patients (32%) were copers and 141 (68%) were non-copers. Univariate analysis showed that copers were significantly older (40 vs. 27 years,  $p < 0.001$ ), had lower preinjury activity level (Tegner 5.7 vs. 6.5,  $p < 0.001$ ) and less often lateral meniscus tears (16% vs. 5%,  $p = 0.019$ ) but not medial meniscus tears (17% vs. 14%,  $p = 0.609$ ) than non-copers. Multivariate analysis revealed that increasing age ( $p < 0.001$ ), Tegner level  $\leq 6$  ( $p = 0.003$ ) and no meniscus injury ( $p = 0.045$ ) were independent predictors of coping with ACL deficiency.

### **Conclusions**

Older age, participation in lower activity sports levels and absence of meniscus injury were predictive of coping with ACL deficiency, whereas there was no such role for tear location, tibial slope, lateral bone bruise presence, ALL injury or gender. These findings might help to identify potential copers and guide surgeons early in the optimal treatment for patients with ACL injury.

## Introduction

Anterior cruciate ligament (ACL) injury is a common injury with an estimated incidence of more than 200,000 injuries in the United States,<sup>1-3</sup> and these ACL injuries can either be treated operatively or conservatively. With conservative treatment,<sup>4,5</sup> patients will undergo neuromuscular training (NMT) under the guidance of a physical therapist,<sup>4,6,7</sup> and will only undergo ACL reconstruction if persistent knee instability is present (so called 'non-copers'). Studies have shown that approximately 40 to 50% of patients can be successful with NMT and are considered 'copers' with their ACL deficiency.<sup>4-6,8,9</sup>

This approach of initial conservative treatment has the advantage that surgery is only performed in patients that truly need surgical stabilization. This not only reduces surgical costs, but also prevents potential surgical complications for patients.<sup>5</sup> On the other hand, there are also disadvantages with this approach. If ACL reconstruction is needed after failed conservative treatment, this will be performed in the delayed setting which increases the risk of additional meniscal and cartilage damage,<sup>10-12</sup> it will delay the total time from injury to return to sports due to the months of failed conservative treatment, and will have higher indirect costs when compared to early ACL reconstruction.<sup>13</sup> It is therefore important to early identify which patients are potential copers and potential non-copers with their ACL deficiency.

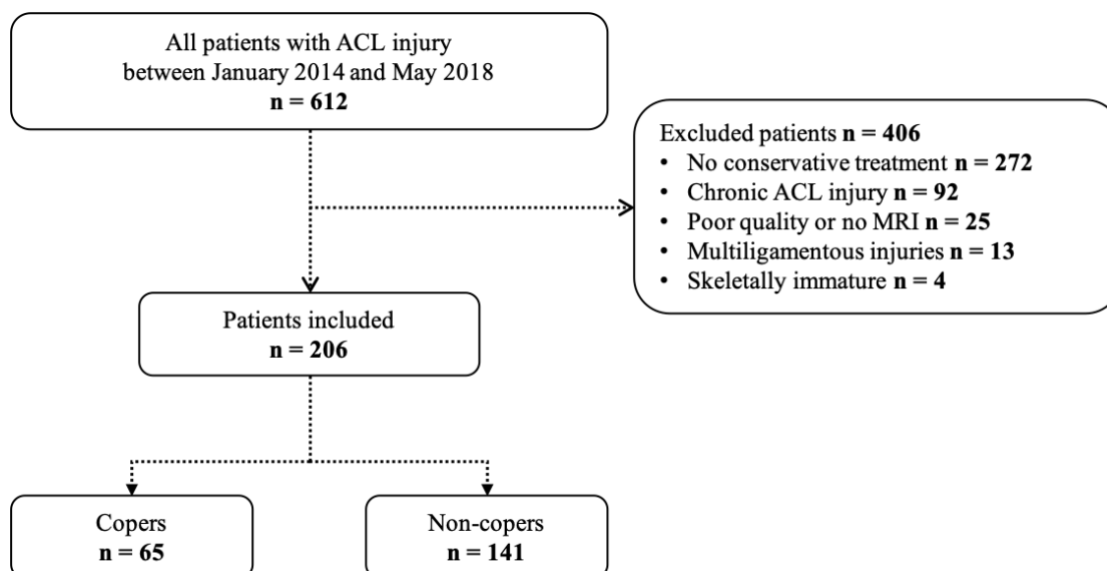
Some studies have assessed the role of patient demographics on the success of conservative treatment of ACL injuries,<sup>6,8,9</sup> but no studies have assessed the role of potential imaging factors, such as tear location, tibial slope or injury to the anterolateral ligament (ALL) on this. First, ACL tear location could play a role on coping with ACL injury as studies have shown that there is better vascularity<sup>14</sup> and healing potential in the proximal part of the ACL,<sup>15</sup> and therefore some groups have advocated to primarily repair proximal tears.<sup>16-21</sup> As primary repair is performed in the acute setting, patients do not have the possibility to undergo conservative treatment and it is possible that these patients with proximal tears respond well to NMT treatment, as the ligament might have sufficient distal remnant length to reattach to the notch<sup>15,22</sup> or femoral insertion<sup>23-25</sup> and provide stability that results in coping. It is therefore important to assess if tear location plays a predictive role on the success of conservative treatment. Furthermore, several studies have shown that large lateral posterior tibial slope has a predictive role on ACL injury,<sup>26-29</sup> on graft rupture following ACL reconstruction<sup>30,31</sup> and ACL revision surgery,<sup>32</sup> and it is therefore also possible that tibial slope plays a role on coping with ACL deficiency with conservative treatment.<sup>33</sup> However, this has not yet been assessed in clinical studies.<sup>34</sup> Another factor that has recently been shown to play a role on knee stability in the setting of ACL deficiency and ACL reconstruction is ALL injury,<sup>35-37</sup> and it is possible that presence of ALL injury predicts the failure of conservative treatment but this has also not been assessed in clinical studies. Finally, it has been suggested that different bone bruise patterns exist with different injury mechanisms<sup>38</sup> but no studies have assessed the correlation between bone bruising patterns and coping with ACL deficiency.

Early recognition of these potential predictors on the success of conservative treatment of ACL injuries is important, as this might help surgeons to start patient-specific treatment for potential copers and non-copers. The goal of this study was thus to assess the role of tear location, ALL injury and tibial slope, along with other patient characteristics on the success of conservative treatment of acute ACL injuries. We hypothesized that older age, lower activity level and absence of meniscal injury along with presence of proximal tears, of lateral bone bruises and absence of ALL injury and less posterior slope were correlated with success of conservative treatment.

## Materials and methods

### Study design

For this retrospective study, institutional board approval was obtained. All patients presenting to our orthopaedic surgery department between January 1<sup>st</sup> 2014 and May 31<sup>th</sup> 2018 with an ACL injury within 3 months of their injury were identified, and patients were excluded for not undergoing conservative treatment, poor quality or no MRI, multi-ligamentous knee injury, and if treatment decision was influenced by skeletally maturity status (details in Figure 1). This resulted in a group of 206 skeletally mature patients with an MRI-confirmed, complete, isolated ACL injury within 3 months of presentation and that were initially treated with conservative treatment. The baseline characteristics of the included versus excluded patients are shown in Table 1.



**Figure 1.** Flowchart of inclusion and exclusion of this study

## Conservative treatment

Conservative treatment under the guidance of a physical therapist was based on the principle of NMT, as is widely described,<sup>4,6,7</sup> and consisted of three phases. In the first phase, the goal was to restore range of motion (ROM), control swelling and start isometric muscle training. In the second phase, the goal was to further improve muscle strength, progress to light sport-specific exercises, obtain  $\geq 80\%$  of the quadriceps and hamstring muscle strength when compared to the contralateral side and  $\geq 80\%$  for hop tests. In the third phase, the goal was to advance to have symmetric patterns of running and sport-specific exercises, improve  $\geq 90\%$  of strength and hop tests compared to the contralateral side, and return to sports. Patients were seen in clinic at 6 weeks and 3 months after start of conservative treatment and were assessed for pain, stability, giving way and progress of NMT. If symptoms were mild, no or rarely giving way occurred and patients were satisfied with NMT progress, patients continued conservative treatment and were seen back 6 weeks later or were discharged from follow-up. If patients had symptomatic instability (multiple giving way episodes despite NMT), or they could not return to their wished activity levels despite NMT progress, the option of ACL reconstruction was discussed and surgery was scheduled.

**Table 1.** Patient demographics for included and excluded patients

	Study cohort N = 206	Excluded patients N = 406	Included vs. excluded
Age (yrs) *	31.2 ± 13.6	29.9 ± 13.2	0.285 <sup>a</sup>
Male gender **	109 (52.9%)	261 (64.3%)	<b>0.007<sup>b</sup></b>
Right side **	107 (51.9%)	222 (54.7%)	0.521 <sup>b</sup>
Tegner level *	6.2 ± 1.0	6.5 ± 1.1	<b>0.003<sup>a</sup></b>
Time injury to clinic (mo) ***	1.4 ± 1.0	17.9 ± 39.2	<b>&lt;0.001<sup>a</sup></b>
Any meniscus tear **	69 (33.5%)	182 (44.8%)	<b>0.007<sup>b</sup></b>
- MM tear only **	31 (15.0%)	87 (21.4%)	0.059 <sup>b</sup>
- LM tear only **	26 (12.6%)	65 (16.0%)	0.267 <sup>b</sup>
- MM and LM tear **	12 (5.8%)	30 (7.4%)	0.470 <sup>b</sup>

Yrs indicates years; mo, months; MM, medial meniscus; LM, lateral meniscus

\* indicates data displayed in mean ± standard deviation; \*\*, in N (%); \*\*\*, in median (interquartile range)

<sup>a</sup> indicates independent t-test; <sup>b</sup>, chi square test

## **Surgical treatment**

All patients underwent NMT and had full ROM prior to surgery. Standard anatomic ACL reconstruction was performed using autograft hamstring tendon, independent femoral tunnel drilling, proximal graft fixation with a cortical button and tibial graft fixation with an interference screw. Postoperative rehabilitation consisted of a similar protocol as conservative NMT treatment with the three phases of control of swelling and return of ROM, muscular strengthening and light sport-specific exercises, and more extensive sport-specific exercises as mentioned above.<sup>39</sup>

## **Data collection**

All patient files were retrospectively reviewed for patient demographic information and treatment. Demographic information consisted of age, gender, side, Tegner activity level, time from injury to presentation. Tegner activity level were both presented as the raw score, and as a binary outcome of participating in higher level sports defined as a Tegner activity score of  $\geq 7$ .<sup>40,41</sup> Radiological information was reviewed for presence of meniscus injury and other ligamentous injuries.

It was reviewed when patients started conservative treatment and if they had successfully completed conservative treatment (discharged from follow-up without surgery) or were scheduled for ACL reconstruction and thus failed conservative treatment. If patients were discharged from follow-up and had not undergone surgery in our hospital, patients or their general practitioner were contacted to assess if future ACL reconstruction was performed in other hospitals. Patients without ACL reconstruction after two years were defined as “copers” and patients that were scheduled for or underwent ACL reconstruction were defined as “non-copers”.

## **Imaging evaluation**

All magnetic resonance imaging (MRI) scans were performed with 1.5T magnets and had 3mm slice thickness, and were conducted with the knee extended and the patient in supine position. Three independent raters (JPL, FAH and HAZ) performed tibial slope measurements on MRI, one rater with experience in measuring ACL tear location performed ACL tear location measurements (JPL) and one experienced musculoskeletal radiologist rated ALL injury (CvD). All patients were de-identified and randomized for blinded measurements.

Tear location of the ACL was measured using a previously validated method by our group,<sup>42</sup> which has an interobserver and intra-observer reliability of 0.92 – 0.96 and 0.91 – 0.97, respectively. The sagittal image best showing the distal remnant and proximal remnant was selected. The distal remnant length was measured using a digital ruler from the point of the anterior tibial insertion to the mid-section of the torn proximal part of the distal remnant. The proximal remnant length was measured from the most superior point of the femoral insertion on the lateral femoral condyle to the mid-section of the torn distal part of the proximal

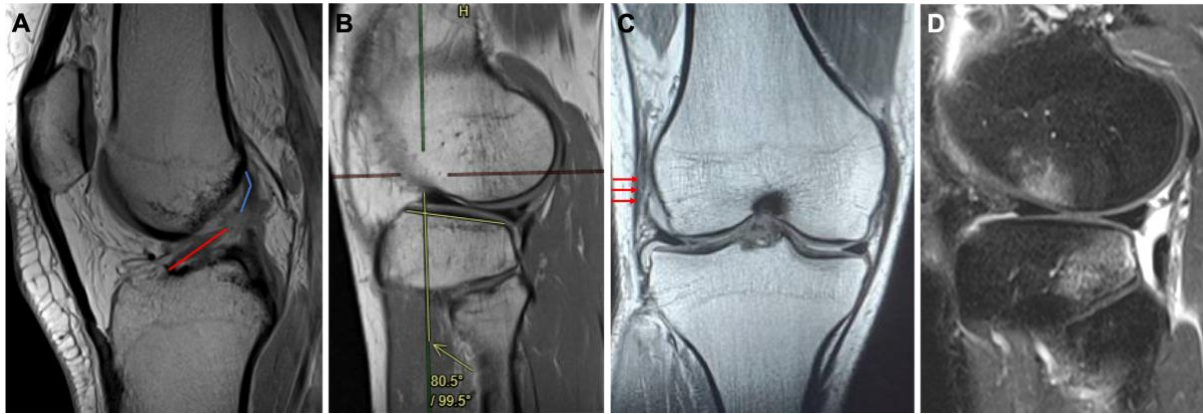

remnant (Figure 2A). Tear location was calculated as the length of the distal remnant divided by the sum of the proximal and distal remnant length and presented as percentage of the total remnant length.

Tibial slope of the medial and lateral plateau were measured on the sagittal images on MRI using a previously validated method,<sup>43</sup> which has an interobserver and intra-observer reliability of 0.79 and 0.89, respectively, and variability of 1.08° and 1.18°, respectively.<sup>44</sup> The sagittal image where the posterior cruciate ligament attached to the tibia was identified and using two horizontal lines at a 5cm distance the longitudinal tibial axis was determined.<sup>44</sup> On the axial images the center of the lateral plateau was then determined, and at this level on the sagittal images a line was drawn along the subchondral bone of the lateral tibial plateau. The lateral tibial slope was measured as the angle between this lateral tibial plateau line and longitudinal tibial axis line (Figure 2C). This measurement was then repeated for the medial side with a similar method.

Presence of bone bruises was assessed using a previously reported method with an intra-observer reliability of 0.92.<sup>38</sup> The sagittal proton-density fat-suppression (PD-FS) images were reviewed and bone bruises in the lateral femoral condyle (LFC), lateral tibial plateau (LTP), medial femoral condyle (MFC) and medial tibial plateau (MTP) were graded as none, minimal (only at subchondral bone), moderate (from articular surface to physeal scar) and severe (from articular surface beyond physeal scar).<sup>45,46</sup>

ALL injury was assessed using a previously reported method with an interobserver and intra-observer reliability for ALL presence of 1 and 1, respectively, and for differentiation partial/complete injury of 0.64 and 0.60 – 0.75, respectively, and an accuracy for ALL presence of 88.5% and partial/complete injury of 61.5%.<sup>47</sup> Coronal images were reviewed and the ALL was defined as the low signal band originating from the lateral condylar femoral region that crosses the proximal surface of the lateral collateral ligament deep to the iliotibial band to its insertion between Gerdy's tubercle and the fibular head. The ALL were considered abnormal when there were irregular contours, a wavy aspect, or areas of discontinuity (Figure 2B). If full-thickness tears were identified, it was scored as a complete injury and otherwise it was scored as partial injury.



**Figure 2.** A, an example of measuring the tear location is shown, which can be calculated by dividing the distal remnant (in red) by the sum of the distal (in red) and proximal remnant (in blue) and is expressed in percentage. B, an example of measuring lateral tibial slope is shown. C, an example of assessing ALL injury is shown on a coronal T1 image as indicated by the arrows with a partial femoral ALL injury. D, an example of assessing lateral bone bruises is shown with a minimal lateral femoral condyle bone bruise and moderate lateral tibial plateau bone bruise.

### Statistical analysis

SPSS version 26.0 was used for the statistical analysis (IBM Software, Armonk, NY, USA). First, patient demographics were assessed for all included and excluded patients in order to assess potential selection bias. Baseline demographics, and radiologic measurements were then compared between copers and non-copers. Continuous data were presented in mean  $\pm$  standard deviation and compared using independent t-tests and nominal data were presented in number (percentage; %) and compared using chi-square tests, or Fisher's exact test if one of the expected cells was  $<5$ . Tibial slope was presented as continuous data and additionally also as the proportion of patients with a lateral tibial slope of  $\geq 9^\circ$  as this threshold has been identified as clinically relevant by previous studies.<sup>32,34</sup> The statistical analyses were performed for the entire cohort and for the subgroup of patients without meniscus injuries to better inform surgeons on different clinical scenarios. Correlation between age and tear location was performed using Pearson correlation analysis.

Multivariate logistic regression was then performed to assess independent predictors of coping with ACL injury and data was reported in Odds Ratio (OR) [95% CI]. Any meniscus tears rather than lateral meniscus tears were included in the multivariate analysis because of the low incidence of lateral meniscus tears (Table 2). All statistical tests were two-sided and a p-value of  $<0.05$  was considered significant. Based on the literature,<sup>28,31,34</sup> sample size calculation for tibial slope revealed that 35 patients would be needed in each group to be sufficiently powered for a  $2^\circ$  difference between two groups with an alpha of 0.05, a power of 80% and a standard deviation of  $3^\circ$ .

## Results

### Baseline characteristics

Mean age of the 206 included patients was 31 years, 53% was male and 52% had an injury to the right knee. Tegner activity level was  $6.2 \pm 1.0$  and 50% of patients participated in higher level sports. Patients presented at mean  $1.4 \pm 1.0$  months following injury at our department, and 33% of patients had a concomitant meniscus injury with their ACL injury. Mean follow-up was  $3.4 \pm 1.1$  years (range 1.9 – 5.7 years) following presentation at our department. This study cohort consisted of more female patients, patients with lower Tegner activity scale and fewer patients with meniscus injuries, specifically medial meniscus injuries, compared to the excluded patients (Table 1).

### Copers versus non-copers: univariate analysis

Sixty-five patients (32%) were copers with their ACL injury, whereas 142 patients (68%) failed conservative treatment and underwent ACL reconstruction. Copers were significantly older than non-copers (40 vs. 27 years,  $p < 0.001$ ), and had lower preinjury activity level (Tegner 5.7 vs. 6.5,  $p < 0.001$ ). Similarly, only 22% of copers were participating in higher level sports compared to 64% of non-copers ( $p < 0.001$ ). Non-copers more often had lateral meniscus tears when compared to copers (16% vs. 5%,  $p = 0.019$ ), but not medial meniscus tears (Table 2). No difference in follow-up was noted between both groups ( $p = 0.729$ ).

No difference was noted between copers and non-copers in distal remnant length (both 27 mm,  $p = 0.490$ ) or tear location (69% vs. 67%, respectively  $p = 0.092$ ). Copers had a shorter proximal remnant length than non-copers (12 vs. 13 mm, respectively,  $p = 0.048$ ). There was also no difference in the proportion of patients with a tear in the proximal quarter between copers and non-copers (23% vs. 18%,  $p = 0.383$ ). Finally, there was a weak but significant positive correlation between older age and more proximal tears (correlation coefficient 0.169,  $p=0.015$ ).

No statistically significant or clinically relevant difference was noted between copers and non-copers in medial tibial slope (4.1 vs. 4.6°, respectively,  $p = 0.351$ ) or lateral tibial slope (5.7 vs. 6.3°, respectively,  $p = 0.194$ ). No differences were also noted in mean slope, difference between medial and lateral slope or proportion of patients with large lateral tibial slope (Table 2).

Regarding the presence of bone bruises, it was noted that copers had significantly less often bone bruises on the lateral femoral condyle when compared to non-copers (35% vs. 66%, respectively,  $p < 0.001$ ). No differences in presence of bone bruises in the other compartments were noted between both groups.

**Table 2.** Patient demographics and radiological characteristics in all patients and between copers and non-copers

	All patients N = 206	Copers N = 65	Non-copers N = 141	Copers vs. non- copers
<b>Patient demographics</b>				
Age (yrs) *	31.2 ± 13.6	39.6 ± 13.6	27.4 ± 11.7	<0.001 <sup>a</sup>
Male gender **	109 (52.9%)	28 (43.1%)	81 (57.4%)	0.055 <sup>b</sup>
Tegner level *	6.2 ± 1.0	5.7 ± 1.1	6.5 ± 0.9	<0.001 <sup>a</sup>
High Tegner level **	104 (50.5%)	14 (21.5%)	90 (63.8%)	<0.001 <sup>b</sup>
Time injury to clinic (mo)*	1.4 ± 1.0	1.3 ± 1.0	1.4 ± 1.0	0.534 <sup>a</sup>
Any meniscus tear **	69 (33.5%)	18 (27.7%)	51 (36.2%)	0.231 <sup>b</sup>
- MM tear only **	31 (15.0%)	11 (16.9%)	20 (14.2%)	0.609 <sup>b</sup>
- LM tear only **	26 (12.6%)	3 (4.6%)	23 (16.3%)	<b>0.019<sup>c</sup></b>
- MM and LM tear **	12 (5.8%)	4 (6.2%)	8 (5.7%)	>0.999 <sup>c</sup>
<b>Tibial slope</b>				
Medial slope *	4.4 ± 3.0°	4.1 ± 2.7°	4.6 ± 3.1°	0.351 <sup>a</sup>
Lateral slope *	6.1 ± 3.4°	5.7 ± 3.5°	6.3 ± 3.3°	0.194 <sup>a</sup>
Mean slope *	5.3 ± 2.8°	4.9 ± 2.7°	5.5 ± 2.9°	0.209 <sup>a</sup>
Difference slope *	1.7 ± 2.8°	1.5 ± 3.1°	1.8 ± 2.7°	0.580 <sup>a</sup>
Lateral slope ≥9° **	50 (24.3%)	12 (18.5%)	38 (27.0%)	0.187 <sup>b</sup>
<b>Anterolateral ligament</b>				
Visualized **	198 (96.1%)	60 (92.3%)	138 (97.9%)	0.055 <sup>b</sup>
- Intact **	100 (50.3%)	25 (41.0%)	75 (54.3%)	
- Partial injury**	79 (39.7%)	28 (45.9%)	51 (37.0%)	0.204 <sup>b</sup>
- Complete injury **	20 (10.1%)	8 (13.1%)	12 (8.7%)	
<b>Tear location</b>				
Distal remnant length *	27 ± 5 mm	27 ± 5 mm	27 ± 5 mm	0.490 <sup>a</sup>
Proximal remnant length *	13 ± 4 mm	12 ± 3 mm	13 ± 4 mm	<b>0.048<sup>a</sup></b>
Tear location *	67 ± 9%	69 ± 8%	67 ± 9%	0.092 <sup>a</sup>
Tear proximal 25% **	39 (18.9%)	14 (21.5%)	25 (17.7%)	0.517 <sup>b</sup>

Yrs indicates years; mo, months; MM, medial meniscus; LM, lateral meniscus

\* indicates data displayed in median with interquartile; \*\*, in N (%); \*\*\*, in mean ± standard deviation

<sup>a</sup> indicates independent t-test; <sup>b</sup>, chi square test; <sup>c</sup>, Fisher's exact test

Table 3. Patient demographics and radiological characteristics in patients without any meniscus injuries and between copers and non-copers in this subgroup

	<b>All patients without meniscus injury</b> N = 137	<b>Copers without meniscus injury</b> N = 47	<b>Non-copers without meniscus injury</b> N = 90	<b>Copers vs. non-copers</b>
<b>Patient demographics</b>				
<b>Age (yrs) *</b>	30.3 ± 13.0	39.3 ± 13.4	25.6 ± 10.0	<b>&lt;0.001<sup>a</sup></b>
<b>Male gender **</b>	67 (48.9%)	17 (36.2%)	50 (55.6%)	<b>0.031<sup>b</sup></b>
<b>Tegner level *</b>	6.3 ± 0.9	5.8 ± 0.9	6.5 ± 0.9	<b>&lt;0.001<sup>a</sup></b>
<b>High Tegner level **</b>	70 (51.1%)	9 (19.1%)	61 (67.8%)	<b>&lt;0.001<sup>b</sup></b>
<b>Time injury to clinic (mo)*</b>	1.2 ± 1.0	1.1 ± 1.1	1.3 ± 1.0	0.491 <sup>a</sup>
<b>Tibial slope</b>				
<b>Medial slope *</b>	4.5 ± 2.8	4.1 ± 2.6	4.7 ± 2.9	0.258 <sup>a</sup>
<b>Lateral slope *</b>	6.3 ± 3.3	5.7 ± 3.5	6.6 ± 3.2	0.161 <sup>a</sup>
<b>Mean slope *</b>	5.4 ± 2.7	4.9 ± 2.6	5.6 ± 2.8	0.151 <sup>a</sup>
<b>Difference slope *</b>	1.8 ± 2.8	1.6 ± 3.2	1.9 ± 2.6	0.593 <sup>a</sup>
<b>Lateral slope ≥9° **</b>	35 (25.5%)	9 (19.1%)	26 (28.9%)	0.215 <sup>b</sup>
<b>Anterolateral ligament</b>				
<b>Visualized **</b>	129 (94.2%)	42 (89.4%)	87 (96.7%)	0.083 <sup>b</sup>
- Intact **	68 (52.3%)	18 (41.9%)	50 (57.5%)	
- Partial injury**	49 (37.7%)	20 (46.5%)	29 (46.5%)	0.242 <sup>b</sup>
- Complete injury **	13 (10.0%)	8 (9.2%)	5 (11.6%)	
<b>Tear location</b>				
<b>Distal remnant length *</b>	26 ± 4	26 ± 4	26 ± 4	0.500 <sup>a</sup>
<b>Proximal remnant length *</b>	13 ± 4	12 ± 3	13 ± 4	0.159 <sup>a</sup>
<b>Tear location *</b>	67 ± 8%	68 ± 8%	66 ± 8%	0.104 <sup>a</sup>
<b>Tear proximal 25% **</b>	20 (14.6%)	9 (19.1%)	11 (12.2%)	0.276 <sup>b</sup>

Yrs indicates years; mo, months; MM, medial meniscus; LM, lateral meniscus

\* indicates data displayed in median with interquartile; \*\*, in N (%); \*\*\*, in mean ± standard deviation

<sup>a</sup> indicates independent t-test; <sup>b</sup>, chi square test; <sup>c</sup>, Fisher's exact test

No difference between copers and non-copers was noted in the presence of partial ALL injury (41% vs. 54%, respectively) or complete ALL injury (13% vs. 9%, respectively) (overall  $p = 0.204$ ). Of all injuries, 51% were tibial injuries (8% bony avulsion (Segond fracture), 43% ligamentous injury), 43% were femoral injuries and 8% were both tibial and femoral ALL injuries.

Similar findings were noted for the subgroup of patients without meniscus injury (Table 3), in which 47 patients (34%) were copers and 90 patients (66%) were non-copers. Copers within this subgroup were also older than non-copers (39 vs. 26 years,  $p < 0.001$ ), more often female (64% vs. 44%,  $p = 0.031$ ), had lower preinjury activity level (Tegner 5.8 vs. 6.5,  $p < 0.001$ ) and lower proportion of patients with high activity level (68% vs. 19%,  $p < 0.001$ ). No differences in tear location, tibial slope or ALL injury were noted between copers and non-copers in this subgroup.

#### Copers versus non-copers: multivariate analysis

Multivariate binary logistic regression analysis showed that older age ( $p < 0.001$ ), participating in Tegner level sports  $< 7$  ( $p = 0.003$ ) and absence of meniscus injuries ( $p = 0.045$ ) were predictive of coping with ACL deficiency. ACL tear location, tibial slope, presence of lateral bone bruises, and ALL injury were not found to be significant predictors of coping with ACL deficiency when corrected for the other variables (Table 4).

**Table 4.** Multivariate binary logistic analysis of variables predicting successful conservative treatment with ACL injury (coping)

Variables	Variables	All patients	
		N = 206	
		OR (LB - UB 95% CI)	P-value
Age (years)	Continuous	<b>1.06 (1.02 - 1.09)</b>	<b>&lt;0.001</b>
Tegner activity	$\geq 7$ vs. $< 7$	<b>0.29 (0.17 - 0.67)</b>	<b>0.003</b>
Any meniscus tear	No vs. yes	<b>0.45 (0.21 - 0.98)</b>	<b>0.045</b>
Tear location	Continuous	1.03 (0.98 - 1.08)	0.255
Gender	Female vs. Male	1.45 (0.66 - 3.20)	0.361
ALL injury*	No vs. yes	1.33 (0.66 - 2.69)	0.423
Lateral tibial slope	Continuous	1.02 (0.91 - 1.11)	0.785

OR indicates odds ratio; LB - UB 95% CI, lower bound – upper bound 95% confidence interval; ALL, anterolateral ligament.

\*Partial and complete injury to the ALL was considered as ALL injury

For all patients:  $R^2 = 0.322$ ,  $p < 0.001$ ; for patients  $> 25$  years of age:  $R^2 = 0.297$ ,  $p < 0.001$

## Discussion

This study assessed the predictive role of patient demographics, tear location, tibial slope and ALL injury on the success of conservative treatment of ACL injury. Data in this study showed that older age, Tegner activity level and absence of meniscus injury were the only independent predictors of coping with ACL deficiency, whereas there was no role for tear location, tibial slope and ALL injury. These findings can be used by orthopaedic surgeons to assess the likelihood of patients coping with their ACL injury and either start conservative or directly operative treatment for ACL injuries depending on patient demographic or radiological factors.

ACL injuries can either be treated conservatively or operatively and mostly depends on patient factors. Initial conservative treatment can be attempted in patients with ACL injuries and has the advantage of giving patients a chance to become copers, which is estimated to occur in 40-50% of patients,<sup>4-6,8,9,48</sup> and this consequently reduces the number of required ACL reconstructions along with surgical costs and potential complications.<sup>5</sup> However, attempting conservative treatment also has disadvantages, as in 50-60% of patients ACL reconstruction is ultimately required and delaying ACL reconstruction increases the risk of additional meniscal and cartilage damage,<sup>10-12</sup> it will delay the total time from injury to full recovery for patients who want to return to sports, and is associated with higher indirect costs when compared to early ACL reconstruction.<sup>13</sup> It is therefore important to assess what are predictors for successful conservative treatment of ACL injuries, so that appropriate treatment can be started for each patient.

Age and activity level were found to be the strongest predictors of coping with ACL deficiency in this study. This is similar to the study by Eitzen et al. that noted that patients failing conservative treatment of ACL injury were younger than copers and that there was a higher proportion of patients with level I activity in the non-copers group.<sup>49</sup> These findings are not surprising as it is well known that younger patients are more often participating in higher knee-demanding sports and consequently also have a higher risk of ACL injury.<sup>50</sup> Older patients, on the other hand, are more likely to adjust their activity level in order to prevent surgery. Another factor that may play a role, might be the severity of the injury in younger and older groups. It is possible that older and less active patients had lower energy knee injuries and less injury of their secondary stabilizers - or less overall damage -, and as a result are better copers than young patients that more often have higher-energy knee injuries. An argument for this hypothesis is the lower incidence of LFC bone bruises in the coping group that has a higher age and lower activity levels.

In a previous study by our group, we have noted that patients younger than 25 and patients younger than 40 with high activity level had a high likelihood of failing conservative treatment.<sup>8</sup> In these patients, surgeons should consider early ACL reconstruction as there are certain advantages. Delaying surgery in these patients not only causes a longer time from injury to final return to sports due to the extra weeks to months of NMT despite the low

likelihood of success in these groups, but also increases the risk of additional meniscal and cartilage damage that is noted with delayed ACL reconstruction.<sup>10-12</sup> Furthermore, in these younger patients there are lower indirect costs by short sick-day leave when early surgery is performed.<sup>13</sup> Based on historical studies, some may argue that early surgery increases the risk of arthrofibrosis, but several recent randomized controlled trials and prospective studies have shown that there is no increased risk of arthrofibrosis with early arthroscopic surgery,<sup>51,52</sup> while some have even suggested that there is less quadriceps muscle atrophy, better functional testing and less pain after six months.<sup>53,54</sup>

Although there had been no interest in the location of ACL tears for decades, recently several studies have examined the role of primary repair for proximal ACL tears<sup>16-21</sup> and therefore the interest in tear location has increased.<sup>55-58</sup> Proximal tears in these cohorts are treated with primary repair in an early setting, and the overall results are generally good.<sup>16-21</sup> Primary repair of proximal tears has been advocated for selective patients with these tear types, since proximal ACL regions have better vascularity than midsubstance regions<sup>14</sup> and therefore proximal tears have healing potential that is similar to medial collateral ligament tears.<sup>15</sup> On the other hand, these same arguments can be used for treating proximal tears conservatively, as these tears might have better chance of healing or reattachment with the better vascularity. This is supported by case reports or small case series that have shown healing of predominantly proximal ACL tears,<sup>22-25</sup> but this could not be confirmed in this study. Although there was a significant difference in proximal remnant length between copers and non-copers (albeit small with 1 mm) and a trend towards a more proximal tear location in the copers compared to the non-copers group, these differences were not present in the multivariate regression analysis. This can be explained by the confounding factor of age that was present as there was a significant correlation between older age and more proximal tear location in this cohort ( $p = 0.015$ ). As copers are generally older patients than non-copers, the tear location might have seemed a significant factor in univariate analysis but multivariate analysis showed that age is the significant and relevant predictor of coping and not tear location. Other cohorts have also reported that there is a correlation between older age and more proximal tear location,<sup>56, 59</sup> although the reason for this remains unknown.

It was hypothesized in this study that tibial slope would play a predictive role on the success of conservative treatment but this was not found in this study. There are possible explanations for these findings. First of all, it was noted that age and Tegner activity were both independent predictors of the success of conservative treatment and it seems that those factors are more relevant than tibial slope. Furthermore, the number of patients with a lateral tibial slopes of  $\geq 9^\circ$  were fairly small, and it is possible that larger cohorts with these extreme slopes would find a significant role on failing conservative treatment. Also, it is possible that a selection bias has occurred in this study as a large group of patients were excluded for undergoing direct operative treatment. It is possible that these patients potentially had a larger tibial slope, and consequently were more symptomatic with more giving way symptoms or a more severe ACL injury and were therefore scheduled for surgery without first undergoing conservative



treatment. Future prospective studies in which all patients with ACL injuries are included and followed are needed to repeat this analysis.

ALL injury was also not found to be a significant predictor of success of conservative treatment of ACL injuries. First of all, the number of patients that had successful coping in this study was only 65, and that makes analysis of the role of ALL on successful coping difficult. Furthermore, it is possible that, similar to tibial slope, there has been a selection bias in this study with more exclusion of patients with ALL injury. Future studies assessing ALL injury, clinical preoperative pivot shift and final coping with ACL injury are necessary to further investigate this.

For gender, univariate analysis showed a trend towards more females in the coping group and suggested that females might be better copers, but multivariate analysis showed that there was no predictive role for gender. This can be explained by the confounding effect of age on gender and coping, as female patients in this study were significantly older ( $35 \pm 15$  years) compared to male patients ( $28 \pm 11$  years,  $p < 0.001$ ), and multivariate analysis showed that an independent predictive role for gender could not be identified in this study. This is similar to the study by Eitzen et al. that found a higher proportion of female patients in the coping group in univariate analysis but not in multivariate analysis.<sup>49</sup>

In this study, meniscus injury was found to be an independent predictor of failing conservative treatment and undergoing ACL reconstruction. In the univariate analysis, it was noted that non-copers had significantly more lateral meniscus tears when compared to copers while this was not the case for medial meniscus tears. This could be explained by the fact that lateral meniscus tears in the setting of ACL deficiency cause a higher degree of rotational instability as displayed in the pivot shift test whereas medial meniscus tears cause a higher degree of anterior tibial translation (ATT) as displayed in the Lachman test.<sup>60, 61</sup> It is possible that medial meniscus tears and thus increased ATT can be stabilized with NMT or at least do not have symptomatic giving way, whereas patients with lateral meniscus tears have more rotational instability, and that this might be more difficult to stabilize with NMT, and they consequently have more symptoms of giving way and more dissatisfaction with the function of their ACL deficient knee.<sup>62, 63</sup> Similar findings were noted with a higher proportion of patients with concomitant lateral meniscus injury in the excluded group, which were mainly excluded due to direct operative treatment (Table 1). These findings, however, need to be confirmed in larger cohort studies, especially since the number of lateral meniscus tears was relatively low.

Finally, it should be noted that the goal of this study was not to assess the percentage of copers and non-copers following ACL injury, and the percentage of copers (32%) was relatively low in this study compared to other studies (40 – 50%).<sup>4-6,8,9</sup> In this study, (older) patients without MRI were excluded and this may have resulted in a lower incidence of copers. A previous study by our group that had the goal of assessing the percentage of copers with ACL injury, found a percentage of 40%,<sup>8</sup> which is comparable with the literature.<sup>4-6,9,48</sup>

Limitations are present in this study. A potential selection bias might be present in this study, as not all patients with ACL injury might have presented to our clinic (copers might have presented to their general practitioner and a referral might have felt unnecessary given their good coping). Nonetheless, we believe that this group is a representative group of patients that present with acute or subacute tears in the orthopaedic department of a hospital. Secondly, this is a retrospective study and potential confounders and other biases might also have been present. Also, small number of patients with lateral meniscus tears and large tibial slopes were present in this study, and future studies assessing the role of these secondary stabilizers is needed, especially as these factors are correlated with pivot shift mechanism and giving way symptoms in patients, and might be an important reason for failing conservative treatment.

## **Conclusions**

This study assessed the predictive role of patient demographics and radiological parameters on the success of conservative treatment of ACL injuries, and noted that older age, lower activity level and absence of meniscus injuries were independent predictors of coping with ACL deficiency, while no predictive role for tear location, tibial slope, bone bruises, or ALL injury were found. These findings can be used for consulting patients on the likelihood of success of conservative treatment of ACL injuries, and can help surgeons indicating patients for conservative treatment or early ACL reconstruction based on these patient demographics and radiological parameters.

## **Conflict of interest**

All authors report no conflict of interest

## References

1. Lyman S, Koulouvaris P, Sherman S, Do H, Mandl LA, Marx RG. Epidemiology of anterior cruciate ligament reconstruction: Trends, readmissions, and subsequent knee surgery. *J Bone Joint Surg Am*. 2009;91(10):2321-2328.
2. Sanders TL, Maradit Kremers H, Bryan AJ, Larson DR, Dahm DL, Levy BA, Stuart MJ, Krych AJ. Incidence of anterior cruciate ligament tears and reconstruction: A 21-year population-based study. *Am J Sports Med*. 2016;44(6):1502-1507.
3. Gianotti SM, Marshall SW, Hume PA, Bunt L. Incidence of anterior cruciate ligament injury and other knee ligament injuries: A national population-based study. *J Sci Med Sport*. 2009;12(6):622-627.
4. Frobell RB, Roos EM, Roos HP, Ranstam J, Lohmander LS. A randomized trial of treatment for acute anterior cruciate ligament tears. *N Engl J Med*. 2010;363(4):331-342.
5. Frobell RB, Roos HP, Roos EM, Roemer FW, Ranstam J, Lohmander LS. Treatment for acute anterior cruciate ligament tear: Five year outcome of randomised trial. *BMJ*. 2013 Jan 24;346:f232.
6. Eitzen I, Moksnes H, Snyder-Mackler L, Risberg MA. A progressive 5-week exercise therapy program leads to significant improvement in knee function early after anterior cruciate ligament injury. *J Orthop Sports Phys Ther*. 2010 Nov;40(11):705-721.
7. van Melick N, van Cingel RE, Brooijmans F, Neeter C, van Tienen T, Hullegie W, Nijhuis-van der Sanden MW. Evidence-based clinical practice update: Practice guidelines for anterior cruciate ligament rehabilitation based on a systematic review and multidisciplinary consensus. *Br J Sports Med*. 2016 Dec;50(24):1506-1515.
8. van der List JP, Hagemans FJA, Hofstee DJ, Jonkers FJ. The role of patient characteristics on the success of nonoperative treatment of anterior cruciate ligament injuries. *Am J Sports Med*. 2020;48(7):1657-1664.
9. Hurd WJ, Axe MJ, Snyder-Mackler L. Influence of age, gender, and injury mechanism on the development of dynamic knee stability after acute acl rupture. *J Orthop Sports Phys Ther*. 2008 Feb;38(2):36-41.
10. Fithian DC, Paxton EW, Stone ML, Luetzow WF, Csintalan RP, Phelan D, Daniel DM. Prospective trial of a treatment algorithm for the management of the anterior cruciate ligament-injured knee. *Am J Sports Med*. 2005;33(3):335-346.
11. Karikis I, Ahlen M, Sernert N, Ejerhed L, Rostgard-Christensen L, Kartus J. The long-term outcome after early and late anterior cruciate ligament reconstruction. *Arthroscopy*. 2018 Jun;34(6):1907-1917.
12. Sommerfeldt M, Goodine T, Raheem A, Whittaker J, Otto D. Relationship between time to acl reconstruction and presence of adverse changes in the knee at the time of reconstruction. *Orthop J Sports Med*. 2018;6(12):232596711881391.
13. von Essen C, McCallum S, Barenus B, Eriksson K. Acute reconstruction results in less sick-leave days and as such fewer indirect costs to the individual and society compared to delayed reconstruction for acl injuries. *Knee Surg Sports Traumatol Arthrosc*. 2019 02/14;28(7):2044-2052.
14. Toy BJ, Yeasting RA, Morse DE, McCann P. Arterial supply to the human anterior cruciate ligament. *J Athl Train*. 1995;30(2):149-152.
15. Nguyen DT, Ramwadhoebe TH, van der Hart CP, Blankevoort L, Tak PP, van Dijk CN. Intrinsic healing response of the human anterior cruciate ligament: An histological study of reattached acl remnants. *J Orthop Res*. 2014;32(2):296-301.
16. Achtnich A, Herbst E, Forkel P, Metzclaff S, Sprenker F, Imhoff AB, Petersen W. Acute proximal anterior cruciate ligament tears: Outcomes after arthroscopic suture anchor repair versus anatomic single-bundle reconstruction. *Arthroscopy*. 2016;32(12):2562-2569.
17. van der List JP, DiFelice GS. Primary repair of the anterior cruciate ligament: A paradigm shift. *Surgeon*. 2017;15(3):161-168.
18. Hoffmann C, Friederichs J, von Ruden C, Schaller C, Buhren V, Moessmer C. Primary single suture anchor re-fixation of anterior cruciate ligament proximal avulsion tears leads to good functional mid-term results: A preliminary study in 12 patients. *J Orthop Surg Res*. 2017;12(1):171.
19. Heusdens CHW, Hopper GP, Dossche L, Roelant E, Mackay GM. Anterior cruciate ligament repair with independent suture tape reinforcement: A case series with 2-year follow-up. *Knee Surg Sports Traumatol Arthrosc*. 2019;27(1):60-67.

20. Hoogeslag RAG, Brouwer RW, Boer BC, de Vries AJ, Huis in 't Veld R. Acute anterior cruciate ligament rupture: Repair or reconstruction? Two-year results of a randomized controlled clinical trial. *Am J Sports Med.* 2019;47(3):567-577.
21. Kosters C, Glasbrenner J, Spickermann L, Kittl C, Domnick C, Herbort M, Raschke MJ, Schliemann B. Repair with dynamic intraligamentary stabilization versus primary reconstruction of acute anterior cruciate ligament tears: 2-year results from a prospective randomized study. *Am J Sports Med.* 2020 Apr;48(5):1108-1116.
22. Crain EH, Fithian DC, Paxton EW, Luetzow WF. Variation in anterior cruciate ligament scar pattern: Does the scar pattern affect anterior laxity in anterior cruciate ligament-deficient knees? *Arthroscopy.* 2005;21(1):19-24.
23. Fujimoto E, Sumen Y, Ochi M, Ikuta Y. Spontaneous healing of acute anterior cruciate ligament (acl) injuries - conservative treatment using an extension block soft brace without anterior stabilization. *Arch Orthop Trauma Surg.* 2002 May;122(4):212-216.
24. Hetsroni I, Delos D, Fives G, Boyle BW, Lillemoe K, Marx RG. Nonoperative treatment for anterior cruciate ligament injury in recreational alpine skiers. *Knee Surg Sports Traumatol Arthrosc.* 2013 Aug;21(8):1910-1914.
25. Costa-Paz M, Ayerza MA, Tanoira I, Astoul J, Muscolo DL. Spontaneous healing in complete acl ruptures: A clinical and mri study. *Clin Orthop Relat Res.* 2012;470(4):979-985.
26. Wordeman SC, Quatman CE, Kaeding CC, Hewett TE. In vivo evidence for tibial plateau slope as a risk factor for anterior cruciate ligament injury: A systematic review and meta-analysis. *Am J Sports Med.* 2012 Jul;40(7):1673-1681.
27. Andrade R, Vasta S, Sevivas N, Pereira R, Leal A, Papalia R, Pereira H, Espregueira-Mendes J. Notch morphology is a risk factor for acl injury: A systematic review and meta-analysis. *JISAKOS.* 2016;1(2):70-81.
28. DePhillipo NN, Zeigler CG, Dekker TJ, Grantham WJ, Aman ZS, Kennedy MI, LaPrade RF. Lateral posterior tibial slope in male and female athletes sustaining contact versus noncontact anterior cruciate ligament tears: A prospective study. *Am J Sports Med.* 2019;47(8):1825-1830.
29. Bayer S, Meredith SJ, Wilson K, de Sa D, Pauyo T, Byrne K, McDonough CM, Musahl V. Knee morphological risk factors for anterior cruciate ligament injury: A systematic review. *J Bone Joint Surg Am.* 2020 Jan 21;102(8):703-718.
30. Christensen JJ, Krych AJ, Engasser WM, Vanhees MK, Collins MS, Dahm DL. Lateral tibial posterior slope is increased in patients with early graft failure after anterior cruciate ligament reconstruction. *Am J Sports Med.* 2015;43(10):2510-2514.
31. Jaecker V, Drouven S, Naendrup JH, Kanakamedala AC, Pfeiffer T, Shafizadeh S. Increased medial and lateral tibial posterior slopes are independent risk factors for graft failure following acl reconstruction. *Arch Orthop Trauma Surg.* 2018 Oct;138(10):1423-1431.
32. Napier RJ, Garcia E, Devitt BM, Feller JA, Webster KE. Increased radiographic posterior tibial slope is associated with subsequent injury following revision anterior cruciate ligament reconstruction. *Orthop J Sports Med.* 2019 Nov;7(11):2325967119879373.
33. Sharifi M, Shirazi-Adl A, Marouane H. Computation of the role of kinetics, kinematics, posterior tibial slope and muscle cocontraction on the stability of acl-deficient knee joint at heel strike – towards identification of copers from non-copers. *J Biomech.* 2018;77:171-182.
34. Rahnemai-Azar AA, Abebe ES, Johnson P, Labrum J, Fu FH, Irrgang JJ, Samuelsson K, Musahl V. Increased lateral tibial slope predicts high-grade rotatory knee laxity pre-operatively in acl reconstruction. *Knee Surg Sports Traumatol Arthrosc.* 2016;25(4):1170-1176.
35. Getgood AMJ, Bryant DM, Litchfield R, Heard M, McCormack RG, Rezansoff A, Peterson D, Bardana D, MacDonald PB, Verdonk PCM, Spalding T, Group SS, Willits K, Birmingham T, Hewison C, Wanlin S, Firth A, Pinto R, Martindale A, O'Neill L, Jennings M, Daniluk M, Boyer D, Zomar M, Moon K, Pritchett R, Payne K, Fan B, Mohan B, Buchko GM, Hiemstra LA, Kerslake S, Tynedal J, Stranges G, McRae S, Gullett L, Brown H, Legary A, Longo A, Christian M, Ferguson C, Mohtadi N, Barber R, Chan D, Campbell C, Garven A, Pulsifer K, Mayer M, Simunovic N, Duong A, Robinson D, Levy D, Skelly M, Shanmugaraj A, Howells F, Tough M, Spalding T, Thompson P, Metcalfe A, Asplin L, Dube A, Clarkson L, Brown J, Bolsover A, Bradshaw C, Belgrove L, Millan F, Turner S, Verdugo S, Lowe J, Dunne D, McGowan K,

- Suddens CM, Declercq G, Vuylsteke K, Van Haver M. Lateral extra-articular tenodesis reduces failure of hamstring tendon autograft anterior cruciate ligament reconstruction: 2-year outcomes from the stability study randomized clinical trial. *Am J Sports Med.* 2020 Feb;48(2):285-297.
36. Sonnery-Cottet B, Saithna A, Cavalier M, Kajetanek C, Temponi EF, Daggett M, Helito CP, Thauinat M. Anterolateral ligament reconstruction is associated with significantly reduced acl graft rupture rates at a minimum follow-up of 2 years. *Am J Sports Med.* 2017 Feb 01;45(7):1547-1557.
  37. Porter M, Shadbolt B. Modified iliotibial band tenodesis is indicated to correct intraoperative residual pivot shift after anterior cruciate ligament reconstruction using an autologous hamstring tendon graft: A prospective randomized controlled trial. *Am J Sports Med.* 2020 Apr;48(5):1069-1077.
  38. Viskontas DG, Giuffre BM, Duggal N, Graham D, Parker D, Coolican M. Bone bruises associated with acl rupture. *Am J Sports Med.* 2017;36(5):927-933.
  39. van Grinsven S, van Cingel REH, Holla CJM, van Loon CJM. Evidence-based rehabilitation following anterior cruciate ligament reconstruction. *Knee Surg Sports Traumatol Arthrosc.* 2010 2010/08/01;18(8):1128-1144.
  40. Eshuis R, Lentjes GW, Tegner Y, Wolterbeek N, Veen MR. Dutch translation and cross-cultural adaptation of the lysholm score and tegner activity scale for patients with anterior cruciate ligament injuries. *J Orthop Sports Phys Ther.* 2016 Nov;46(11):976-983.
  41. Hendrix ST, Barrett AM, Chrea B, Replogle WH, Hydrick JM, Barrett GR. Relationship between posterior-inferior tibial slope and bilateral noncontact acl injury. *Orthopedics.* 2017;40(1):e136-e140.
  42. Vermeijden HD, Cerniglia B, Mintz DN, Rademakers MV, Kerkhoffs G, van der List JP, DiFelice GS. Distal remnant length can be measured reliably and predicts primary repair of proximal anterior cruciate ligament tears. *Knee Surg Sports Traumatol Arthrosc.* 2020 Oct 15.
  43. Hashemi J, Chandrashekar N, Gill B, Beynon BD, Slauterbeck JR, Schutt RC, Mansouri H, Dabezies E. The geometry of the tibial plateau and its influence on the biomechanics of the tibiofemoral joint. *J Bone Joint Surg Am.* 2008;90(12):2724-2734.
  44. Lipps DB, Wilson AM, Ashton-Miller JA, Wojtys EM. Evaluation of different methods for measuring lateral tibial slope using magnetic resonance imaging. *Am J Sports Med.* 2012 Dec;40(12):2731-2736.
  45. Brittberg M, Winanski CS. Evaluation of cartilage injuries and repair. *J Bone Joint Surg Am.* 2003;85(suppl\_2):58-69.
  46. Marot V, Corin B, Reina N, Murgier J, Berard E, Cavaignac E. Femoral and tibial bone bruise volume is not correlated with all injury or rotational instability in patients with acl-deficient knee. *Knee Surg Sports Traumatol Arthrosc.* 2020.
  47. Monaco E, Helito CP, Redler A, Argento G, De Carli A, Saithna A, Helito PVP, Ferretti A. Correlation between magnetic resonance imaging and surgical exploration of the anterolateral structures of the acute anterior cruciate ligament-injured knee. *Am J Sports Med.* 2019 Apr;47(5):1186-1193.
  48. Kvist J, Filbay S, Andersson C, Ardern CL, Gauffin H. Radiographic and symptomatic knee osteoarthritis 32 to 37 years after acute anterior cruciate ligament rupture. *Am J Sports Med.* 2020 Aug;48(10):2387-2394.
  49. Eitzen I, Moksnes H, Snyder-Mackler L, Engebretsen L, Risberg MA. Functional tests should be accentuated more in the decision for acl reconstruction. *Knee Surg Sports Traumatol Arthrosc.* 2010;18(11):1517-1525.
  50. Nicholls M, Aspelund T, Ingvarsson T, Briem K. Nationwide study highlights a second peak in acl tears for women in their early forties. *Knee Surg Sports Traumatol Arthrosc.* 2018 Feb;26(2):648-654.
  51. Deabate L, Previtali D, Grassi A, Filardo G, Candrian C, Delcogliano M. Anterior cruciate ligament reconstruction within 3 weeks does not increase stiffness and complications compared with delayed reconstruction: A meta-analysis of randomized controlled trials. *Am J Sports Med.* 2019;48(5):1263-1272.
  52. Kwok CS, Harrison T, Servant C. The optimal timing for anterior cruciate ligament reconstruction with respect to the risk of postoperative stiffness. *Arthroscopy.* 2013 Mar;29(3):556-565.
  53. Eriksson K, von Essen C, Jonhagen S, Barenius B. No risk of arthrofibrosis after acute anterior cruciate ligament reconstruction. *Knee Surg Sports Traumatol Arthrosc.* 2018;26(10):2875-2882.
  54. von Essen C, Eriksson K, Barenius B. Acute acl reconstruction shows superior clinical results and can be performed safely without an increased risk of developing arthrofibrosis. *Knee Surg Sports Traumatol Arthrosc.* 2019;28(7):2036-2043.

55. van der List JP, DiFelice GS. Role of tear location on outcomes of open primary repair of the anterior cruciate ligament: A systematic review of historical studies. *Knee*. 2017;24(5):898-908.
56. van der List JP, Mintz DN, DiFelice GS. The location of anterior cruciate ligament tears: A prevalence study using magnetic resonance imaging. *Orthop J Sports Med*. 2017;5(6):2325967117709966.
57. Henle P, Roder C, Perler G, Heitkemper S, Egli S. Dynamic intraligamentary stabilization (dis) for treatment of acute anterior cruciate ligament ruptures: Case series experience of the first three years. *BMC Musculoskelet Disord*. 2015;16:27.
58. Krismer AM, Gousopoulos L, Kohl S, Ateschrang A, Kohlhof H, Ahmad SS. Factors influencing the success of anterior cruciate ligament repair with dynamic intraligamentary stabilisation. *Knee Surg Sports Traumatol Arthrosc*. 2017;25(12):3923-3928.
59. van der List JP, Jonkergouw A, van Noort A, Kerkhoffs G, DiFelice GS. Identifying candidates for arthroscopic primary repair of the anterior cruciate ligament: A case-control study. *Knee*. 2019 Jun;26(3):619-627.
60. Musahl V, Citak M, O'Loughlin PF, Choi D, Bedi A, Pearle AD. The effect of medial versus lateral meniscectomy on the stability of the anterior cruciate ligament-deficient knee. *Am J Sports Med*. 2010 Aug;38(8):1591-1597.
61. Hoshino Y, Miyaji N, Nishida K, Nishizawa Y, Araki D, Kanzaki N, Kakutani K, Matsushita T, Kuroda R. The concomitant lateral meniscus injury increased the pivot shift in the anterior cruciate ligament-injured knee. *Knee Surg Sports Traumatol Arthrosc*. 2019 Feb;27(2):646-651.
62. Monaco E, Maestri B, Conteduca F, Mazza D, Iorio C, Ferretti A. Extra-articular acl reconstruction and pivot shift. *Am J Sports Med*. 2014;42(7):1669-1674.
63. Kocher MS, Steadman JR, Briggs K, Zurakowski D, Sterett WI, Hawkins RJ. Determinants of patient satisfaction with outcome after anterior cruciate ligament reconstruction. *J Bone Joint Surg Am*. 2002 Sep;84(9):1560-1572.

# Chapter 5

## **The location of anterior cruciate ligament tears: a prevalence study using magnetic resonance imaging**

Jelle P. van der List

Douglas N. Mintz

Gregory S. DiFelice

*Orthop J Sports Med.* 2017 Jun; 5(6):2325967117709966.

## **Abstract**

### **Background**

Over the past decade, there has been a resurgence of interest in anterior cruciate ligament (ACL) preservation. Proximal and distal avulsion tears have been treated with arthroscopic primary repair, while augmented repair, remnant tensioning, primary repair with biological scaffold, and remnant preservation have been proposed for different types of midsubstance tears. Currently, the incidence of these different tear types is unknown.

### **Purpose**

To propose a magnetic resonance imaging (MRI) classification system for different tear types based on clinical relevance and to assess the distribution of these different ACL tear types.

### **Study Design**

Case series; Level of evidence, 4.

### **Methods**

A retrospective search in an institutional radiographic database was performed for patients who underwent knee MRI at our institution between June 2014 and June 2016. Patients with reports of chronic tears, partial tears, multiligamentous injuries, and age <18.0 years were excluded. Tear types were graded as proximal avulsion (distal remnant length >90% of total ligament length, type I), proximal (75%-90%, type II), midsubstance (25%-75%, type III), distal (10%-25%, type IV), and distal avulsion (<10%, type V). An orthopaedic surgeon, a radiologist, and a research fellow graded the tear type on 30 MRIs to determine reliability, and the research fellow graded all MRIs. Inter- and intraobserver reliability were measured using kappa statistics.

### **Results**

A total of 353 patients (57% male; mean age, 37.1 years; range, 18.1-81.2 years) were included. Interobserver reliability was 0.670 (95% confidence interval, 0.505-0.836), and intraobserver reliability ranged from 0.741 to 0.934. Incidence of type I tears was 16%, type II tears 27%, type III tears 52%, type IV tears 1%, and type V tears 3% (2.5% with bony avulsion). Type I tears were more common in patients older than 35 years compared with those younger than 35 years (23% vs 8%;  $P < .001$ ).

### **Conclusion**

This classification system was reliable in assessing tear location in acute ACL injuries. Type I tears were seen in 16%, type II in 27%, and type III in 52% of patients in our cohort. These data suggest that there may be greater potential application for ACL preservation techniques.



## Introduction

In the 1970s and 1980s, treatment of anterior cruciate ligament (ACL) injuries consisted of open primary repair and the short-term outcomes were excellent.<sup>1,2</sup> Several authors, however, noted that the results deteriorated at longer-term follow-up<sup>3-5</sup> Sherman et al. were the first to use multivariate analysis to find an explanation for the deterioration of their results of open primary ACL repair at mid-term follow-up.<sup>5</sup> They categorized ACL tears into four tear types, and found that patients with type I (proximal avulsion) tears were associated with better outcomes when compared to type III or IV (midsubstance) tears. Over the ensuing years, several studies indeed showed excellent results of open primary repair when performed on patients with only proximal (type I) tears.<sup>6-8</sup> Despite these findings, open primary repair was abandoned in the 1990s.<sup>9,10</sup>

More recently, there has been a resurgence of interest in ACL preservation which has several advantages, such as: maintaining proprioception, preserving the biology and minimizing surgical morbidity,<sup>11-13</sup> faster recovery,<sup>14</sup> and experimental findings, such as restoring native kinematics<sup>15</sup> and preventing of osteoarthritis<sup>16</sup>. Learning from the findings of Sherman et al. and benefiting from modern advances, such as arthroscopy and early range of motion, DiFelice et al. were the first to report excellent outcomes of arthroscopic primary repair of proximal (type I) ACL tears<sup>11</sup>. More recently, others have confirmed these findings.<sup>17,18</sup> Similarly, other surgeons have proposed preservation techniques for different tear types, such as augmented repair, repair with biological scaffold, remnant tensioning, remnant preservation, and distal repair.<sup>19-23</sup>

With this resurgence of interest in arthroscopic primary repair and other ACL preservation techniques, it is important to know the incidence of different tear types, but this is currently not known due to ligament debriding in all cases with the current gold standard of ACL reconstruction. Therefore, we aimed to (I) propose a grading system for different tear types based on clinical relevance and feasibility, and (II) assess the distribution of different tear types in patients with acute ACL tears. We hypothesized that midsubstance tears are the most common tear type, and that type I tears occur in 10-20% of adult patients with acute ACL injuries.

## **Methods**

### **Patient selection**

Following institutional review board approval from our institution (Hospital for Special Surgery, #16009), a search was performed in the electronic radiology patient archiving and communication system (PACS) (Sectra Workstation IDS7, version 16.1, Sectra AB, Linköping, Sweden) for patients who underwent knee MRI at our institution for ACL injuries between June 3, 2014 and June 2, 2016. The reports by radiologists were screened for the diagnosis of an ACL tear. A total of 710 MRIs with ACL tears were identified. Patients were then excluded if they had partial tears (n = 67), had non-acute tears, defined as >1 month delay between injury and MRI (n = 207), were paediatric patients, defined as younger than 18.0 years of age (n = 76), or had multiligamentous knee injuries (n = 7). After applying these exclusion criteria, a total of 353 adult patients with an acute isolated complete ACL tear that underwent MRI at our institution were identified.

### **MRI measurements**

MRI was performed with a 1.5-T or 3.0-T superconducting magnet (GE Medical Systems, Milwaukee, WI, USA) using a standardized institutional protocol. ACL tear locations were assessed from two-dimensional fast-spin echo images acquired along three anatomic planes (sagittal, coronal, axial) (TR/TE 4,000 to 6,000 milliseconds/25 to 30 milliseconds; ETL 8 to 16; bandwidth, 32 - 62.5 kHz over entire frequency range; acquisition matrix, 512x256-416; number of excitations, 1 to 2; field of view, 15 to 16 cm; slice thickness, 3.5 mm with no gap). An additional sagittal inversion recovery sequence was obtained (TR/TE 5000-8000/18, ETL 8-16, TI 150-180, bandwidth 32-62.5, 256 x192, 1 or 2 NEX, FOV 16-18cm, slice thickness 3.5-4.0 cm). Examinations were performed in the supine position with a pillow under the knee supporting it in extension and slight external rotation. The quadriceps was relaxed and no anesthesia was used in any patient. The extremity was secured in a commercial extremity coil (8-channel knee coil, MedRad, Warrendale, PA, USA) to ensure a consistent extremity position for all patients.

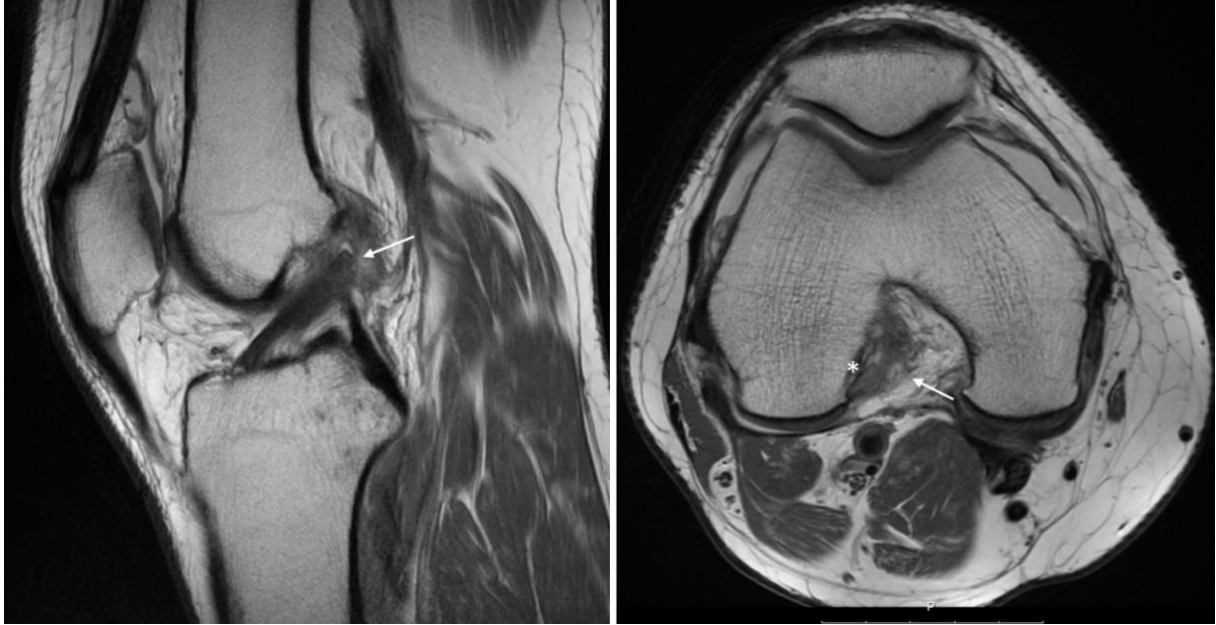
The sagittal, coronal and axial planes were viewed in order to assess the ACL tear location. The ligament was first viewed on the sagittal plane and was followed from distal to proximal in order to assess the tear location. Coronal and sagittal planes were then critically reviewed to confirm the tear location. If a spiral tear pattern was noted, the middle of the spiral part was defined as the tear location. If the distal remnant was sagged in, which means that the ligament is wavy, because it is not tensioned towards the femur, and therefore not reaches the proximal remnant, an assessment was made for the original distal and proximal remnant lengths, and thus the original tear location (some sagging of the ligament is seen in Figure 9). If needed, a digital ruler was used to assess the exact tear location.

## **Classification system**

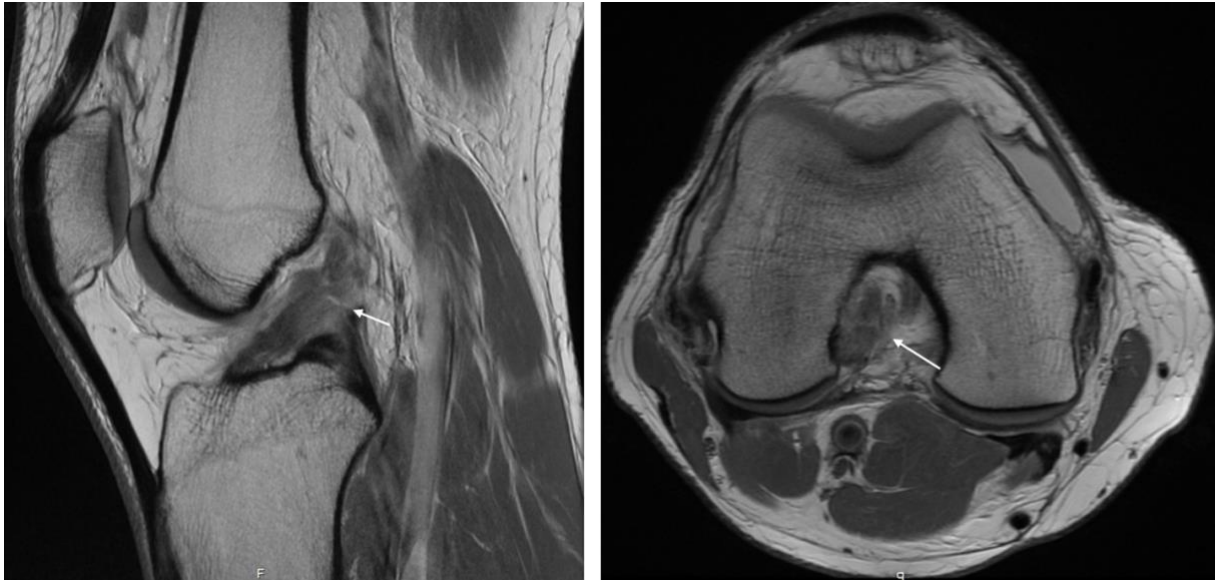
All tears were classified as one of following tear types: type I tear (proximal avulsion tear, located at >90% of distal-proximal length) (Figure 1), type II tear (proximal tear, located at 75 – 90% of distal-proximal length) (Figure 2), type III tear (midsubstance tear, located at 25 – 75% of distal-proximal length) (Figure 3), type IV tear (distal tear, located at 10 – 25% of distal-proximal length) (Figure 4), or type V tear (distal avulsion tear, located at <10% of distal-proximal length). Type I tears and type V tears were further classified as soft tissue avulsion tears (Figure 5) or bony avulsion tears (Figure 6). If it was noted that the different parts of the ligament were torn at different levels, the locations of the individual anteromedial and posterolateral bundles were noted. This classification was partially based on the tear locations as classified by Sherman et al.,<sup>5</sup> and partially on a recently published ACL preservation treatment algorithm,<sup>24,25</sup> in which type I tears were treated with arthroscopic primary repair,<sup>11,17</sup> type II tears with augmented repair,<sup>19,21,24</sup> type III and type IV tears with ACL reconstruction with remnant tensioning and preservation, respectively,<sup>19,20</sup> and type V tears with primary repair or a variety of fixation options for soft tissue avulsion or bony avulsion types, respectively.<sup>22,26</sup>

## **Measurement protocol**

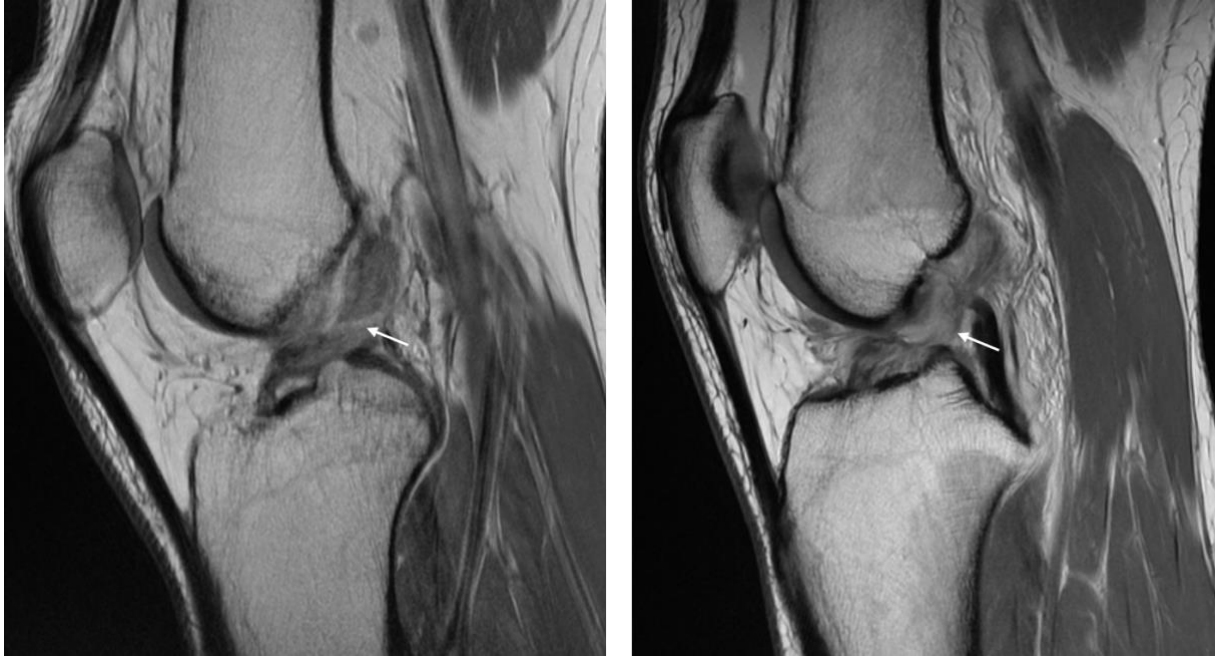First, thirty patients were randomly selected for the assessment of interobserver and intra-observer reliability of this classification method. An orthopaedic surgeon experienced in ligament preservation (G.S.D.), a musculoskeletal radiologist with >15 years of experience (D.N.M.), and a research fellow (J.P.L.) graded the tear location in these thirty patients. The orthopaedic surgeon and research fellow were using the tear type classification for 6 months prior to the start of this study, while the radiologist had not worked with this specific classification prior to this study. Three weeks after initial assessment, the three observers repeated the measurements to assess the intra-observer reliability. Finally, the research fellow graded all 353 patients to assess the incidence of the tear types.



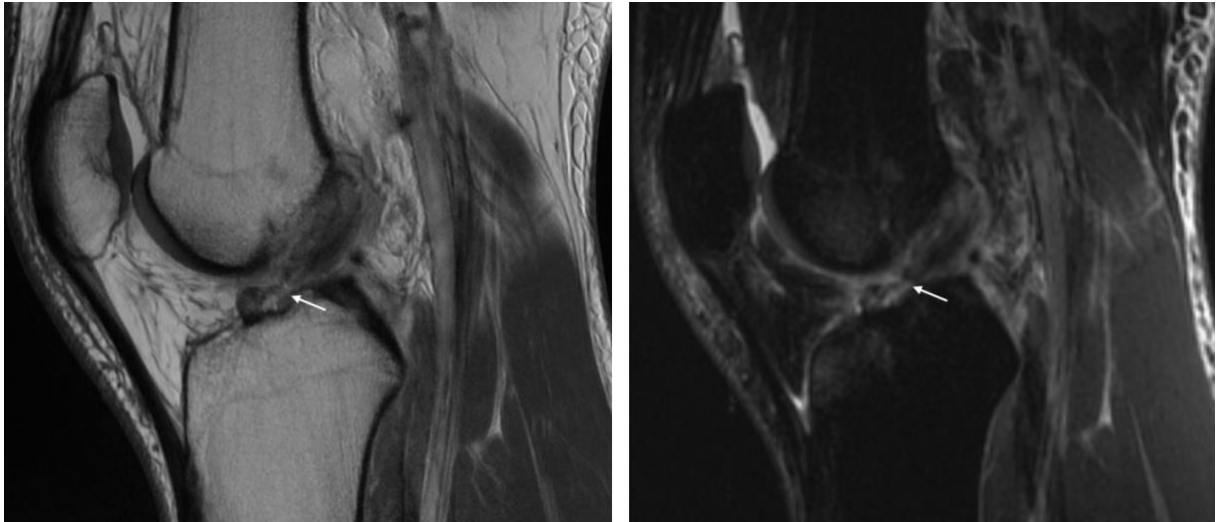
**Figure 1.** A type I tear (arrow) is shown on the sagittal T1 view (left) and axial T1 view (right).



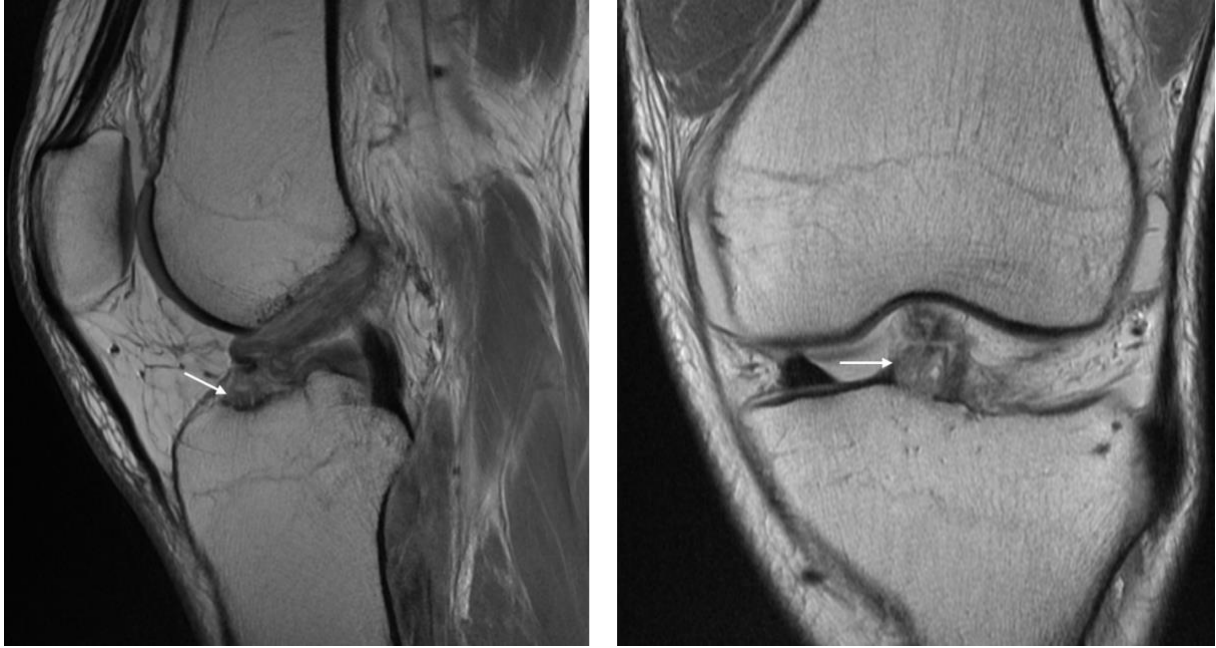
**Figure 2.** A type II tear (arrow) is shown on the sagittal T1 view (left) and axial T1 view (right).



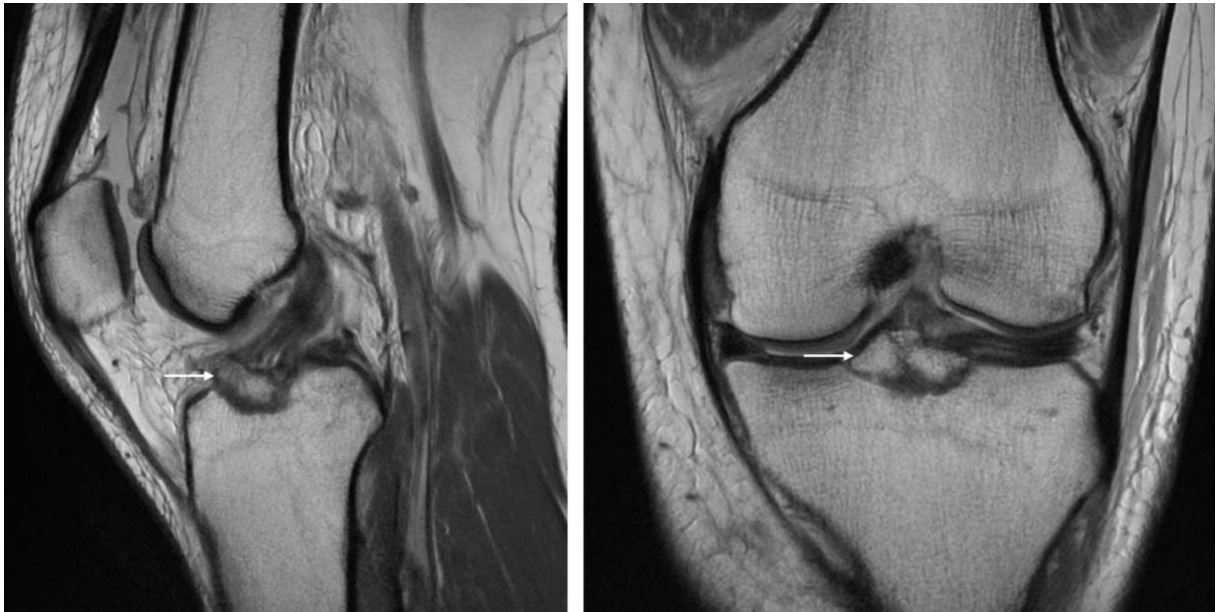
**Figure 3.** A type III tear (arrow) is shown on the sagittal T1 view (left) and another more complex type III tear (arrow) is shown on the sagittal T1 view (right).



**Figure 4.** A type IV tear (arrow) is shown on the sagittal T1 view (left) and sagittal T2 view (right).



**Figure 5.** A type V soft tissue avulsion tear (arrow) is seen on the sagittal T1 view (left) and coronal T1 view (right).



**Figure 6.** A type V bony avulsion (arrow) is seen on the sagittal T1 view (left) and coronal T1 view (right).

## **Data collection**

Additional collected data from the MRI intake info were gender, side of injury, injury mechanism, and date of birth, date of injury, and date of MRI in order to calculate age and delay from injury to MRI. Subgroups were: <35 years of age and >35 years of age (mean age was 37 years), males, females, and all injury mechanism groups with >30 patients.

## **Statistical analysis**

Statistical analysis was performed using SPSS version 21.0 (IBM Software, Armonk, NY, USA). Interobserver reliability of the three observers was calculated using Fleiss' kappa, and intra-observer reliability was calculated using Cohen's kappa. Kappa was reported with 95% confidence intervals (CI). Interpretation of kappa values was based upon guidelines outlined by Landis and Koch,<sup>27</sup> and represent poor (<0.00), slight (0.00 – 0.20), fair (0.21 – 0.40), moderate (0.41 – 0.60), substantial (0.61 – 0.80) or almost perfect (0.81 – 1.00) agreement. Incidence of the different tear types was displayed in percentages for the total group and the different subgroups. Chi-square tests were used to compare the incidence of tear types in different subgroups. A *p*-value of <0.05 was considered statistically significant.

## Results

### Study cohort

A total of 353 patients could be included. Patients had a mean  $\pm$  SD age of  $37.1 \pm 12.9$  years (range 18.1 – 81.2 years), 57% was male and 51% had an ACL tear in their right knee. Mean  $\pm$  SD delay from injury to MRI was  $8 \pm 7$  days (range 0 – 31 days). Most common injury mechanisms were skiing (39%), soccer (13%), and basketball (11%) in this cohort.

### Interobserver and intraobserver reliability

Interobserver reliability for the classification system between the three observers was substantial with a kappa value of 0.670 (95% CI 0.505 – 0.836). Intra-observer reliability for the orthopaedic surgeon was 0.934 (95% CI 0.807 – 1.000), for the radiologist 0.741 (95% CI 0.463 – 1.000), and for the research fellow 0.875 (95% CI 0.710 – 1.000).

### Incidence of different tear types

In the total group, type I tears were seen in 16% of patients, type II tears in 27%, type III tears in 52%, type IV tears in 1%, and type V tears were seen in 3% of patients (Table 1). In 1% of the tears, the tear locations of both bundles differed. All type I tears in this cohort were soft tissue avulsion tears. Type V tears were more commonly bony avulsion (2.5%) than soft tissue avulsion tears (0.6%).

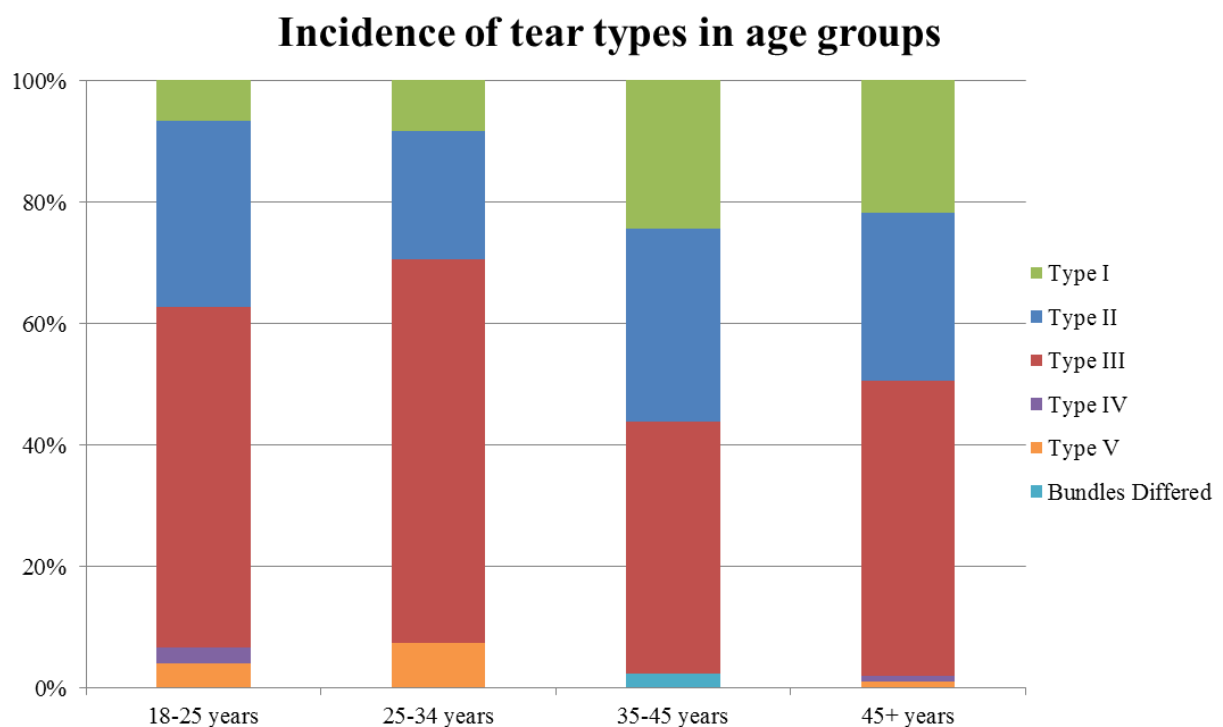
### Subgroup analyses

In patients older than 35 years of age, type I tears were significantly more frequently seen when compared to younger patients (23% vs. 8%,  $p < 0.001$ ). Type III tears (60% vs. 45%,  $p = 0.006$ ) and type V tears (6% vs. 1%,  $p = 0.007$ ) were more frequently seen in younger patients. Incidence of the tear types in different age groups is shown in Figure 7.



<b>Tear type</b>	<b>Location</b>	<b>Incidence</b>
Type I	>90%	16%
Type II	75 – 90%	27%
Type III	25 –75%	52 %
Type IV	10 – 25%	1%
Type V	<10%	3%
Bundles differed*	-	1%
<b>Total</b>	-	<b>100%</b>

\*In these tear types the anteromedial and posterolateral bundle were torn at different locations.  
Tear location indicates the length of distal remnant as percentage of ligament length



**Figure 7.** The incidence of the different tear types is seen in the different age groups. It can be noted that type I tears were more commonly seen in patients older than 35 years when compared to patients younger than 35 years ( $p < 0.001$ ), while Type III tears and type V tears were more commonly seen in patients younger than 35 years ( $p = 0.006$  and  $p = 0.007$ , respectively).

With regard to gender, a trend towards a higher incidence of type I tears was noted in females (19%) when compared to males (13%,  $p = 0.115$ ). No differences in other tear types between both genders were seen.

Skiing, basketball and soccer were injury mechanisms with >30 patients and these were further analyzed. Although a trend of higher incidence of type I tears was noted with skiing (17%) and soccer (18%) injuries when compared to basketball injuries (12%), no significant differences between the groups were noted for any tear types (Table 2).

**Table 2.** Incidence of tear types based on MRI in our cohort stratified by injury mechanism

<b>Tear type</b>	<b>Location</b>	<b>Skiing (n = 139)</b>	<b>Soccer (n = 44)</b>	<b>Basketball (n = 43)</b>
Type I	>90%	17%	18%	12%
Type II	75 – 90%	27%	23%	30%
Type III	25 –75%	50%	59%	56%
Type IV	10 – 25%	1%	0%	0%
Type V	<10%	4%	0%	2%
Bundles differed*	-	1%	0%	0%
Total	-	100%	100%	100%

No significant differences were noted between each of the groups ( $p > 0.05$ ).

\* In these tear types the anteromedial and posterolateral bundle were torn at different locations.

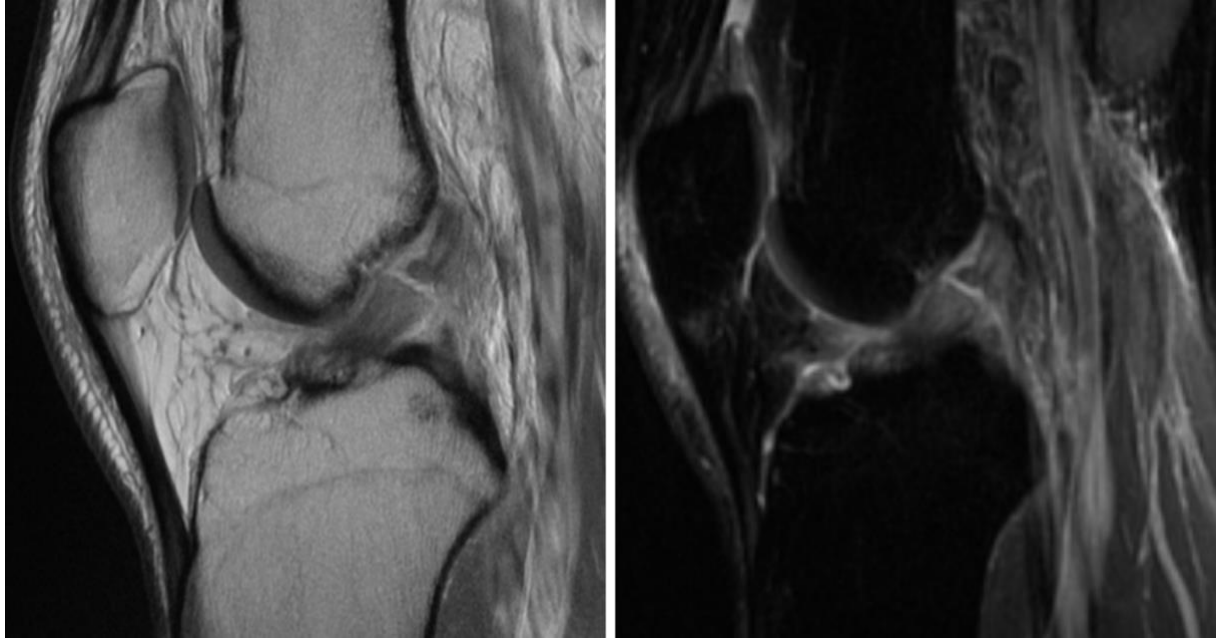
Tear location indicates the length of distal remnant as percentage of ligament length

## Discussion

In this study, we proposed a tear type classification on MRI, and assessed the incidence of the different tear types in adult patients using this tear type classification. Substantial interobserver and substantial to nearly perfect intra-observer reliability was found with this measurement method. It was noted that 16% of tears were type I tears and that these were more commonly seen in patients older than 35 years. Type II tears occurred in 27%, whereas type III tears were most commonly seen (52%). Type IV (1%) and type V tears (3%) were not frequently seen in this cohort. This study was the first study assessing ACL tear type incidence using MRI, and these findings may help the orthopaedic surgeon in making a preoperative assessment of which ACL preservation technique might be possible.

In this study, we have validated a classification system with five tear locations, which was based on both feasibility (of measurement) and clinical relevance. In the initial tear type classification of Sherman et al., four different tear types were described for the upper (proximal) half of the ligament. This would result in seven tear types if these types were mirrored to the lower (distal) half of the ligament (tears at the 50% location result in only 1 type when mirrored). Although this classification is very specific, the multiple options lead to disagreement between the observers in our previous experience, while there was no additive value for clinical practice (no different ACL preservation treatments between proximal – mid third junction tears, middle third tears, and mid – distal junction tears.<sup>24,25</sup> Therefore, the Sherman classification was modified in which these three tear types were considered midsubstance tears. This improved the clinical application of the classification system, while increasing agreement between observers. Another frequently used method to describe the tear location is to describe the tear location as proximal, middle and distal thirds. This classification, however, is not specific enough as there is no differentiation between type I and type II tears. Furthermore, many tears occur around the junction of the proximal and middle third (22% in the study of Sherman et al.), which can lead to a high disagreement between observers, as these tears need to be categorized as proximal or as middle thirds.

With this in mind, we decided to use the classification system as was earlier proposed: there is no confusion about tears at the junction of proximal and middle third (these are considered midsubstance tears), and the tear types can be correlated with ACL preservation techniques.<sup>24,25</sup> Although the intra-observer reliability was good in this study (substantial to almost perfect), the interobserver reliability was substantial. Disagreement between observers mainly occurred with the type II – type III tears (Figure 8). Difficulty was seen with the assessment of the original tear location when the ligament was sagged, or when the tear had a spiral pattern. This can explain the substantial interobserver reliability. Ultimately, arthroscopy is needed to assess the possibility of using ACL preservation techniques with these tear types as tissue quality is a critical determinant.



**Figure 8.** This case is an example of a tear around the proximal – mid third junction, which had a decreased interobserver reliability. After measuring the length of both remnants, this tear was graded as a type III tear. Some slight “sagging” of the ligament can be seen at the distal insertion, which creates a small gap between the proximal and distal remnant.

The main findings in this study were that 43% of the ACL tears were proximal quarter tears, of which 16% were type I tears and 27% were type II tears, whereas the majority (52%) of the tears were located in the midsubstance of the ligament. Since the current gold standard of reconstruction resects the entirety of the torn ligament, there really has been little interest in this topic, and we could identify no studies reporting the incidence of different tear types using MRI. Therefore, we feel it is of additional value to compare our findings with studies in the historical literature that assessed the tear location intra-operatively. Sherman et al. in their paper noted that 13 out of 50 patients (26%) had type I tears, 15 out of 50 (30%) had type II tears, while 22 out of 50 (44%) had type III or IV tears. The incidence of type I and type II tears was slightly higher when compared to this current study, which might be explained by a combination of factors, such as: the small number of patients in their cohort ( $n = 50$ ), the treatment bias in their study (they assessed the tear location only in operated patients), or the regional selection bias in our study. The incidence of type III and IV tears in the study by Sherman et al. (44%) was quite similar to the incidence of midsubstance tears (type III) tears in this current study (52%).

Other historical studies have reported the incidence of tear locations in proximal, middle and distal thirds during surgery. Grontvedt et al. performed a randomized clinical trial between 1986 and 1988 in which patients were treated with primary repair or augmented repair and they reported that in the total study 104 out of 147 patients (71%) had proximal third tears.<sup>9</sup> This is significantly higher than the findings in our study (incidence of type I and II tears: 43%).

This may, however, be explained by the fact that many patients have a tear at the junction of proximal third and middle third (22% according to the study of Sherman et al.). These patients may have been classified as proximal third tear in their study whereas they are considered middle third tears in our study. Several other historical clinical studies, similar to our study, reported that most tears were midsubstance tears.<sup>2,28-31</sup>

Results in this study showed that the incidence of type I tears were significantly higher in patients older than 35 years, while there was a trend of more type I tears in females. We can only speculate on the reasons for these findings. A possible explanation is that the tear location depends on the severity of the injury. It is possible that with low-energy injuries the ligament tends to avulse off the wall, while with high-impact injuries, the ligament is more commonly disrupted in the mid-substance. Another possible explanation may be that the mechanism of injury is associated with different tear type; for example, a hyperextension injury could theoretically be more commonly associated with proximal tears than valgus mechanisms. In our study, no correlation between tear location and sports of injury was found. However, the exact injury mechanism (e.g., valgus, hypertension etc.) was not retrieved. Although many studies have found correlations between valgus or internal rotation movement and ACL tears, and have speculated on correlations between injury mechanism and ACL injuries,<sup>32-34</sup> no other studies in the literature could be identified that suggested a correlation between injury mechanism and different tear types. Future biomechanical or retrospective studies could shine more light on the correlation of injury mechanisms and tear types.

Several limitations exist in this study. First of all, the location of ACL tears was assessed on MRI, and these results cannot be extrapolated as the percentage of patients that are eligible for primary repair or other preservation techniques. Tissue quality is an important factor for preservation techniques, and this was not assessed in this study. Furthermore, the correlation between tear types on MRI and arthroscopy is not known, and further studies are therefore needed to assess this. Despite this limitation, outcomes in this study are valuable and may help the orthopaedic surgeon in making a preoperative assessment whether patients might be eligible for primary repair or other preservation techniques. Secondly, it is currently unknown if patients with different tear types have a different sense of instability, and thus perhaps a different delay from injury to MRI. It is possible that patients with proximal tears have a delayed presentation, since the remnant can reattach to the femoral notch or PCL with these tear types, providing some form of stability.<sup>35-38</sup> This can lead to less urgency to seek medical care, which contains a potential selection bias. It was only possible to include acute tears because that remnant tissue may retract or reabsorb in the non-acute setting and is therefore less visible on MRI.<sup>39,40</sup> We believe that only assessing acute tears is, however, appropriate, especially since preservation techniques are generally performed in the acute setting.<sup>17,41</sup> Finally, another selection bias cannot be excluded in this study. A relatively high number of patients had skiing injuries, which could have influenced the tear type distribution.

Studies in other geographic regions, with a different mix of sporting activities, are necessary to confirm our tear type distribution.

## **Conclusions**

In this study a tear type classification was proposed for acute complete ACL injuries using MRI. It was noted that 43% of the tears were in the proximal quarter of which 16% were type I tears and 27% were type II tears, while type III tears were most common in our cohort (52%). Type I tears were more commonly seen in older patients, while type III and V tears were more frequently seen younger than 35 years. Future studies are necessary to correlate these MRI findings to arthroscopic findings to identify what percentage of patients is eligible for ACL preservation surgery and primary ACL repair surgery.

## **Conflict of interest**

One or more of the authors has declared a potential conflict of interest outside this work, as specified in the OJSM Conflict of Interest statement.

## References

1. Feagin JA, Abbott HG, Rokous JR. The isolated tear of the anterior cruciate ligament. *J Bone Joint Surg Am.* 1972;54(6):1340-1341.
2. Marshall JL, Warren RF, Wickiewicz TL. Primary surgical treatment of anterior cruciate ligament lesions. *Am J Sports Med.* 1982;10(2):103-107.
3. Feagin JA, Jr., Curl WW. Isolated tear of the anterior cruciate ligament: 5-year follow-up study. *Am J Sports Med.* 1976;4(3):95-100.
4. Kaplan N, Wickiewicz TL, Warren RF. Primary surgical treatment of anterior cruciate ligament ruptures. A long-term follow-up study. *Am J Sports Med.* 1990;18(4):354-358.
5. Sherman MF, Lieber L, Bonamo JR, Podesta L, Reiter I. The long-term followup of primary anterior cruciate ligament repair. Defining a rationale for augmentation. *Am J Sports Med.* 1991;19(3):243-255.
6. Bram J, Plaschy S, Lutolf M, Leutenegger A. [the primary cruciate ligament suture--is the method outdated? Results in follow-up of 58 patients]. *Z Unfallchir Versicherungsmed.* 1994;87(2):91-109.
7. Genelin F, Trost A, Primavesi C, Knoll P. Late results following proximal reinsertion of isolated ruptured ACL ligaments. *Knee Surg Sports Traumatol Arthrosc.* 1993;1(1):17-19.
8. van der List JP, DiFelice GS. Role of tear location on outcomes of open primary repair of the anterior cruciate ligament: A systematic review of historical studies. *Knee.* 2017.
9. Grontvedt T, Engebretsen L, Benum P, Fasting O, Molster A, Strand T. A prospective, randomized study of three operations for acute rupture of the anterior cruciate ligament. Five-year follow-up of one hundred and thirty-one patients. *J Bone Joint Surg Am.* 1996;78(2):159-168.
10. van der List JP, DiFelice GS. Primary repair of the anterior cruciate ligament: A paradigm shift. *Surgeon.* 2016;15(3):161-168.
11. DiFelice GS, Villegas C, Taylor SA. Anterior cruciate ligament preservation: Early results of a novel arthroscopic technique for suture anchor primary anterior cruciate ligament repair. *Arthroscopy.* 2015;31(11):2162-2171.
12. Murray MM. Current status and potential of primary ACL repair. *Clin Sports Med.* 2009;28(1):51-61.
13. Adachi N, Ochi M, Uchio Y, Iwasa J, Ryoke K, Kuriwaka M. Mechanoreceptors in the anterior cruciate ligament contribute to the joint position sense. *Acta Orthop Scand.* 2002;73(3):330-334.
14. van der List JP, DiFelice GS. Range of motion and complications following primary repair versus reconstruction of the anterior cruciate ligament. *Knee.* 2017.
15. Fleming BC, Carey JL, Spindler KP, Murray MM. Can suture repair of ACL transection restore normal anteroposterior laxity of the knee? An ex vivo study. *J Orthop Res.* 2008;26(11):1500-1505.
16. Murray MM, Fleming BC. Use of a bioactive scaffold to stimulate anterior cruciate ligament healing also minimizes posttraumatic osteoarthritis after surgery. *Am J Sports Med.* 2013;41(8):1762-1770.
17. Achtnich A, Herbst E, Forkel P, Metzclaff S, Sprenger F, Imhoff AB, Petersen W. Acute proximal anterior cruciate ligament tears: Outcomes after arthroscopic suture anchor repair versus anatomic single-bundle reconstruction. *Arthroscopy.* 2016;32(12):2562-2569.
18. Smith JO, Yasen SK, Palmer HC, Lord BR, Britton EM, Wilson AJ. Paediatric ACL repair reinforced with temporary internal bracing. *Knee Surg Sports Traumatol Arthrosc.* 2016;24(6):1845-1851.
19. Jung YB, Jung HJ, Siti HT, Lee YS, Lee HJ, Lee SH, Cheon HY. Comparison of anterior cruciate ligament reconstruction with preservation only versus remnant tensioning technique. *Arthroscopy.* 2011;27(9):1252-1258.
20. Hong L, Li X, Zhang H, Liu X, Zhang J, Shen JW, Feng H. Anterior cruciate ligament reconstruction with remnant preservation: A prospective, randomized controlled study. *Am J Sports Med.* 2012;40(12):2747-2755.
21. Mackay GM, Blyth MJ, Anthony I, Hopper GP, Ribbans WJ. A review of ligament augmentation with the internalbrace: The surgical principle is described for the lateral ankle ligament and ACL repair in particular, and a comprehensive review of other surgical applications and techniques is presented. *Surg Technol Int.* 2015;26:239-255.
22. Leeberg V, Lekdorf J, Wong C, Sonne-Holm S. Tibial eminentia avulsion fracture in children - a systematic review of the current literature. *Dan Med J.* 2014;61(3):A4792.

23. Murray MM, Flutie BM, Kalish LA, Ecklund K, Fleming BC, Proffen BL, Micheli LJ. The bridge-enhanced anterior cruciate ligament repair (bear) procedure: An early feasibility cohort study. *Orthop J Sports Med.* 2016;4(11):2325967116672176.
24. van der List JP, DiFelice GS. Preservation of the anterior cruciate ligament: A treatment algorithm based on tear location and tissue quality. *Am J Orthop (Belle Mead NJ).* 2016;45(7):E393-E405.
25. van der List JP, DiFelice GS. Preservation of the anterior cruciate ligament: Surgical techniques. *Am J Orthop (Belle Mead NJ).* 2016;45(7):E406-414.
26. Sheth MR, Tapasvi SR, Patil SS. Primary repair of tibial-sided avulsion of the anterior cruciate ligament. *Arthrosc Tech.* 2016;5(4):E901-906.
27. Landis JR, Koch GG. The measurement of observer agreement for categorical data. *Biometrics.* 1977;33(1):159-174.
28. Liljedahl SO, Lindvall N, Wetterfors J. Early diagnosis and treatment of acute ruptures of the anterior cruciate ligament; a clinical and arthrographic study of forty-eight cases. *J Bone Joint Surg Am.* 1965;47(8):1503-1513.
29. Sgaglione NA, Warren RF, Wickiewicz TL, Gold DA, Panariello RA. Primary repair with semitendinosus tendon augmentation of acute anterior cruciate ligament injuries. *Am J Sports Med.* 1990;18(1):64-73.
30. Straub T, Hunter RE. Acute anterior cruciate ligament repair. *Clin Orthop Relat Res.* 1988;227:238-250.
31. Cross MJ, Wootton JR, Bokor DJ, Sorrenti SJ. Acute repair of injury to the anterior cruciate ligament. A long-term followup. *Am J Sports Med.* 1993;21(1):128-131.
32. Johnson SC. Anterior cruciate ligament injury in elite alpine competitors. *Med Sci Sports Exerc.* 1995;27(3):323-327.
33. Pappas E, Zampeli F, Xergia SA, Georgoulis AD. Lessons learned from the last 20 years of ACL-related in vivo-biomechanics research of the knee joint. *Knee Surg Sports Traumatol Arthrosc.* 2013;21(4):755-766.
34. Speer KP, Warren RF, Wickiewicz TL, Horowitz L, Henderson L. Observations on the injury mechanism of anterior cruciate ligament tears in skiers. *Am J Sports Med.* 1995;23(1):77-81.
35. Crain EH, Fithian DC, Paxton EW, Luetzow WF. Variation in anterior cruciate ligament scar pattern: Does the scar pattern affect anterior laxity in anterior cruciate ligament-deficient knees? *Arthroscopy.* 2005;21(1):19-24.
36. Fowler PJ, Regan WD. The patient with symptomatic chronic anterior cruciate ligament insufficiency. Results of minimal arthroscopic surgery and rehabilitation. *Am J Sports Med.* 1987;15(4):321-325.
37. Vahey TN, Broome DR, Kayes KJ, Shelbourne KD. Acute and chronic tears of the anterior cruciate ligament: Differential features at mr imaging. *Radiology.* 1991;181(1):251-253.
38. van der List JP, DiFelice GS. Successful arthroscopic primary repair of a chronic anterior cruciate ligament tear 11 years following injury. *HSS J.* 2017;13(1):90-95.
39. O'Donoghue DH, Rockwood CA, Jr., Frank GR, Jack SC, Kenyon R. Repair of the anterior cruciate ligament in dogs. *J Bone Joint Surg Am.* 1966;48(3):503-519.
40. Magarian EM, Fleming BC, Harrison SL, Mastrangelo AN, Badger GJ, Murray MM. Delay of 2 or 6 weeks adversely affects the functional outcome of augmented primary repair of the porcine anterior cruciate ligament. *Am J Sports Med.* 2010;38(12):2528-2534.
41. DiFelice GS, van der List JP. Arthroscopic primary repair of proximal anterior cruciate ligament tears. *Arthrosc Tech.* 2016;5(5):E1057-E1061.



# Chapter 6

## **Preoperative magnetic resonance imaging predicts eligibility for arthroscopic primary anterior cruciate ligament repair**

Jelle P. van der List

Gregory S. DiFelice

*Knee Surg Sports Traumatol Arthrosc.* 2018 Feb;26(2):660-671.

## **Abstract**

### **Purpose**

To assess the role of preoperative magnetic resonance imaging (MRI) on the eligibility for arthroscopic primary anterior cruciate ligament (ACL) repair.

### **Methods**

All patients undergoing ACL surgery between 2008 and 2017 were included. Patients underwent arthroscopic primary repair if sufficient tissue length and quality was present, or they underwent single-bundle ACL reconstruction. Preoperative MRI tear locations were graded with the modified Sherman classification: type I (>90% distal remnant length), type II (75-90%), or type III (25-75%). MRI tissue quality was graded as good, fair, or poor. Arthroscopy videos were reviewed for tissue length and quality, and final treatment.

### **Results**

Sixty-three repair patients and 67 reconstruction patients were included. Repair patients had more often type I tears (41% vs. 4%,  $p<0.001$ ), and good tissue quality (89% vs. 12%,  $p<0.001$ ). Preoperative MRI tear location and tissue quality predicted eligibility for primary repair: 90% of all type I tears, and 88% of type II tears with good tissue quality were repaired, while only 23% of type II tears with fair tissue quality, 0% of type II tears with poor tissue quality, and 14% of all type III tears could be repaired.

### **Conclusions**

This study showed that tear location and tissue quality on preoperative MRI can predict eligibility for arthroscopic primary ACL repair. These findings may guide the orthopaedic surgeon on the preoperative assessment for arthroscopic primary repair of proximal ACL tears.

### **Level of Evidence**

Level IV

## Introduction

The first surgical treatment of anterior cruciate ligament (ACL) injuries consisted of open primary repair.<sup>1-6</sup> The initial short-term outcomes in the 1970s and 1980s were promising,<sup>7-9</sup> but Feagin and Curl were the first to note a deterioration of these results at mid-term follow-up.<sup>10</sup> Despite many improvements, such as using non-absorbable sutures,<sup>11,12</sup> the results remained unpredictable at mid-term follow-up,<sup>13</sup> and the technique was ultimately abandoned.<sup>6</sup>

At the end of the primary repair era, in 1991, Sherman et al. attempted to find an explanation for the deterioration of their results at mid-term follow-up by performing an extensive subgroup analysis.<sup>14</sup> They categorized ACL tears by tear location and tissue quality, and noted that better outcomes were associated with proximal (type I) tears and good tissue quality compared to midsubstance tears and poor tissue quality. Subsequently, several authors reported excellent outcomes of open primary repair when selectively treating patients with proximal tears and good tissue quality.<sup>15-17</sup> Despite these results, reconstructive surgery had become the standard operative treatment for all ACL injuries.<sup>6</sup>

More recently, there has been a renewed interest in primary ACL repair using arthroscopy. DiFelice et al. was the first to report excellent outcomes of arthroscopic primary repair in patients with proximal (type I) tears and good tissue quality,<sup>18</sup> and others confirmed these findings.<sup>19-22</sup> These studies, similar to the study of Sherman et al. in 1991, emphasized that patient selection is critical for good results of arthroscopic primary ACL repair.<sup>18-23</sup> With the usage of magnetic resonance imaging (MRI), a preoperative assessment can be made for which patients might be eligible for arthroscopic primary repair, but knowledge on the predictive role of MRI is currently lacking.

Therefore, the goal of this study was to assess the predictive role of preoperative MRI on the eligibility for arthroscopic primary repair of proximal ACL tears. The research questions were (I) what tear types were seen on preoperative MRI in patients that were eligible and not eligible for primary repair, and (II) can a preoperative assessment for arthroscopic primary ACL repair be made using MRI. The hypotheses were that (I) different tear location and tissue quality were seen on preoperative MRI in patients eligible and not eligible for primary repair, and (II) preoperative MRI could be used to predict eligibility for primary repair. Findings in this study may help the orthopaedic surgeon in making a preoperative assessment of the eligibility of primary repair and provide insight in the incidence of repairable ACL tears.

## Materials and Methods

A retrospective search was performed in the database of the senior author (G.S.D.) for patients undergoing ACL surgery between April 2008 and January 2017. Patients were excluded if preoperative MRI was unavailable or of insufficient quality ( $n = 72$ ), arthroscopy images and videos were unavailable or of insufficient quality ( $n = 12$ ), or both were unavailable or of insufficient quality ( $n = 7$ ). Furthermore, patients were excluded when time between injury and MRI was  $>3$  months ( $n = 11$ ), or time between MRI and arthroscopic surgery was  $>3$  months ( $n = 18$ ). Finally, patients were excluded for distal bony avulsion tears ( $n = 3$ ), as this study focused on proximal ACL repair eligibly. A total of 130 patients met the exclusion and inclusion criteria and could be included.

### Baseline characteristics of included patients

Included patients had a median age of 31 years (range 14 – 66 years) and BMI of 25 kg/m<sup>2</sup> (range 18 – 44 kg/m<sup>2</sup>). Most patients were males (60%), and had right-sided injuries (57%). Sixty-three patients (48%) underwent arthroscopic primary repair, and 67 (52%) patients underwent reconstruction. No significant differences between the repair group and reconstruction group were found with regard to age, BMI, gender, side of injury, injury mechanism or time from MRI to surgery, although repair patients had shorter time from injury to MRI than the reconstruction patients (5 vs. 9 days,  $p = 0.015$ ) (Table 1).

### Surgical techniques

During this period, all included patients preoperatively agreed to the same treatment algorithm: patients would undergo primary ACL repair if sufficient length and tissue quality was noted intraoperatively, or they would undergo single-bundle ACL reconstruction. All surgeries were performed by the senior author (G.S.D.). Arthroscopic primary repair was performed with suture anchor fixation of both the anteromedial and posterolateral bundle, as previously described.<sup>22, 24</sup> An InternalBrace (Arthrex, Naples, FL, USA) was added to the repair in 62% of patients since the availability of this technique to protect the healing of the ligament, as previously described.<sup>25</sup> Single-bundle anatomic ACL reconstruction was performed in the reconstruction group using soft tissue autografts (21%), allografts (58%) or hybrid (autograft/allograft, 3%), or bone-patellar tendon-bone autografts (18%).

**Table 1.** Baseline characteristics of all patients in this study cohort, and stratified by final treatment

<b>Factor</b>	<b>All patients n = 130</b>	<b>Repair n = 63</b>	<b>Reconstruction n = 67</b>	<b>P-value *</b>
<b>Age (years; median (range))</b>	31 (14 – 66)	34 (14 – 66)	26 (14 – 55)	n.s.
<b>BMI (kg/m<sup>2</sup>; median (range))</b>	25 (18 – 44)	24 (18 – 34)	25 (18 – 44)	n.s.
<b>Male gender (n (%))</b>	78 (60%)	36 (57%)	42 (63%)	n.s.
<b>Right side (n (%))</b>	74 (57%)	36 (57%)	38 (57%)	n.s.
<b>Injury to MRI (days; median (range))</b>	6 (0 – 91)	9 (1 – 90)	5 (0 – 91)	0.015
<b>MRI to surgery (days; median (range))</b>	24 (1 – 91)	16 (1 – 91)	27 (4 – 89)	n.s.
<b>Injury Mechanisms (n (%))</b>				n.s.
Skiing	29 (22%)	18 (29%)	11 (16%)	
Basketball	18 (14%)	10 (16%)	8 (12%)	
Soccer	18 (14%)	6 (10%)	12 (18%)	
Football	8 (6%)	2 (3%)	6 (9%)	
Rugby	8 (6%)	5 (8%)	3 (4%)	
Martial Arts	4 (3%)	2 (3%)	2 (3%)	
Motor Vehicle Accident	4 (3%)	0 (0%)	4 (6%)	
Lacrosse	4 (3%)	3 (5%)	1 (1%)	
Jump from Height	3 (2%)	2 (3%)	1 (1%)	
Gym	3 (2%)	3 (5%)	0 (0%)	
Other/Unspecified	27 (24%)	12 (19%)	19 (28%)	

\* Independent t-tests were performed for continuous variables, and chi-square tests (or Fisher's exact tests when less than 5 patients were in one of the cells) were performed for nominal data

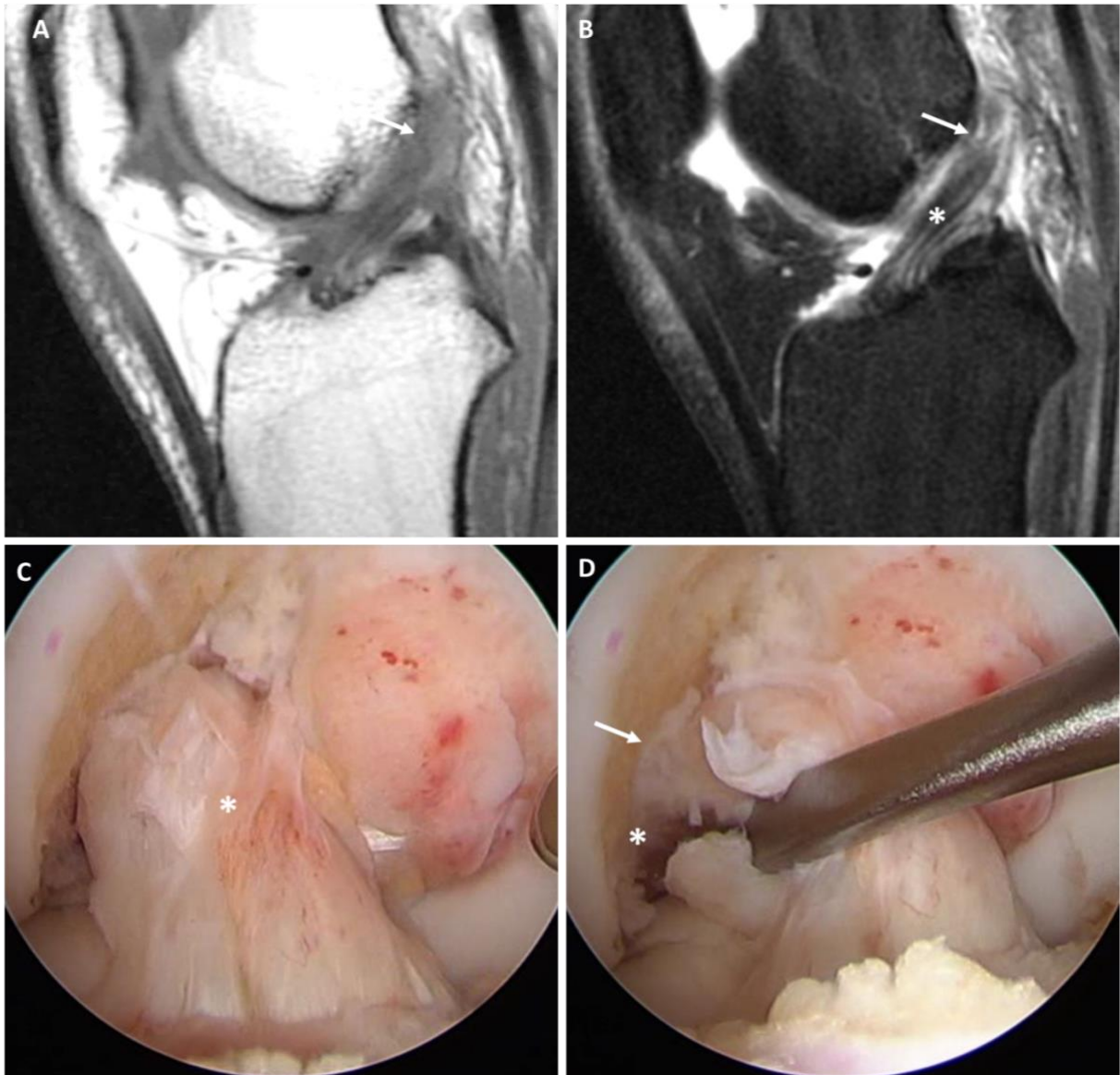
## Data collection

First, general data was collected, including date of birth, date of injury, date of MRI, date of surgery, age, gender, BMI, side of injury, and injury mechanism. Then, tear location and tissue quality of all patients were reviewed on preoperative MRI using the modified Sherman classification by van der List et al.<sup>26</sup> On the axial, coronal and sagittal views, the ACL was reviewed and the exact tear location was determined. Using a ruler, the length of the tibial and femoral remnants were measured and the tear location was classified as one of the following tear types (Table 2): type I proximal avulsion tear (distal remnant length >90%; Figure 1), type II proximal tear (75 – 90%; Figures 2, 3 and 4), or type III mid-substance tear (middle 25 – 75%; Figure 5).<sup>27-29</sup> This method has been shown to have substantial interobserver (Kappa 0.670) and substantial to nearly perfect intra-observer reliability (Kappa 0.741 – 0.934).<sup>26</sup> Tissue quality was graded as one of the following grades using the classification of Sherman et al.<sup>14</sup> (Table 2): good (when (nearly) all fibers were running in the same direction and the signal was homogenous; Figure 1 and 2), fair (when part of the fibers was running in same direction and the signal was mildly heterogeneous; Figures 3 and 5), or poor tissue quality (when most fibers were running in different directions and the signal as heterogeneous, Figure 4).

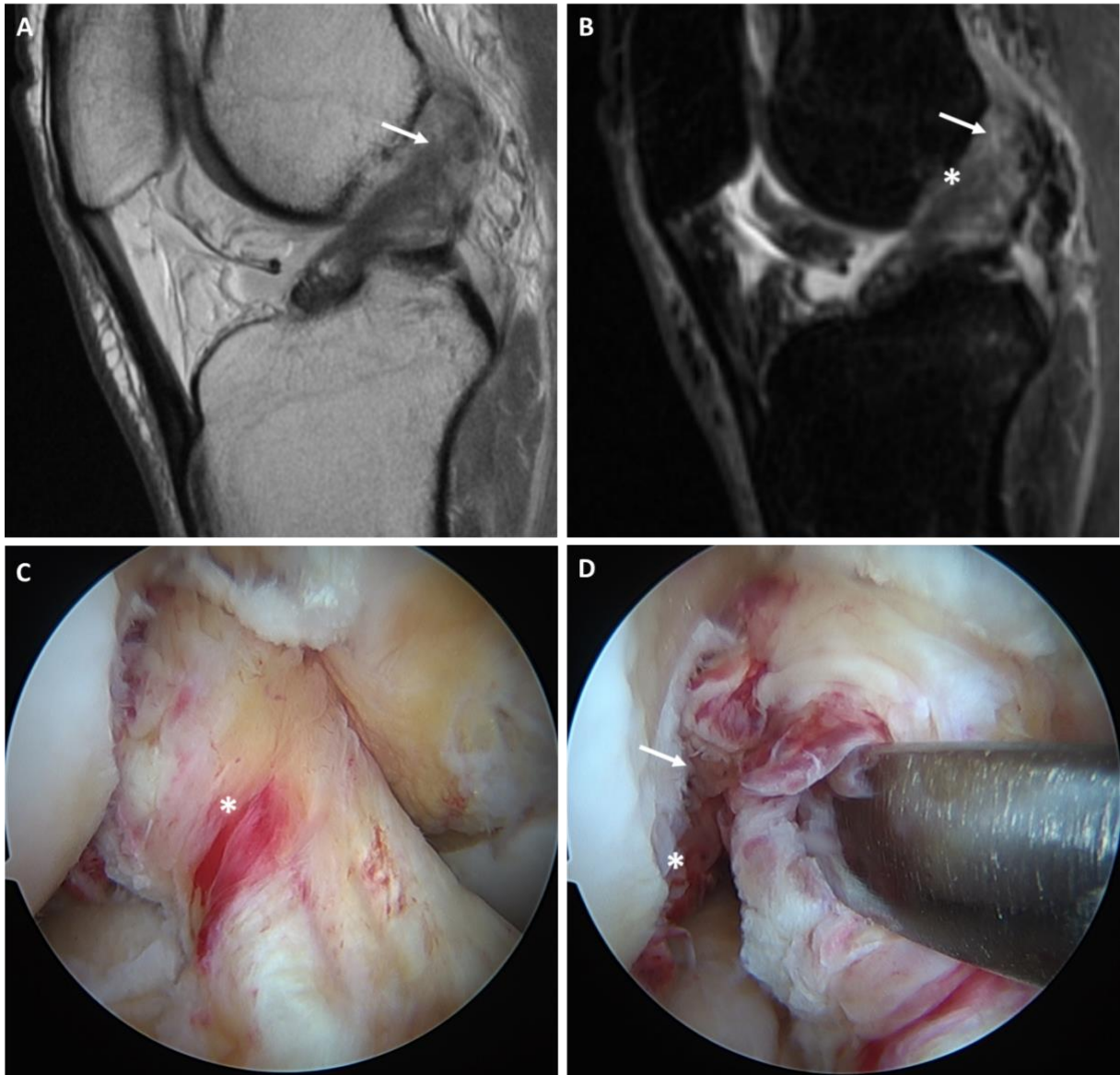
Next, the arthroscopic videos of all patients were reviewed, blinded for the MRI grading. Intraoperatively, the senior author recorded the assessment of tissue length and tissue quality using video in all patients. Tissue length was assessed by inspection of the tear location, probing the ligament, and tensioning the distal remnant proximally with a grasper. It was noted whether the tissue length was sufficient, or insufficient, for reinsertion onto the femoral wall. Tissue quality was assessed by inspection, by probing the ligament, and during suture passage. It was noted if the tissue quality was sufficient, or insufficient, for suture passage and tensioning towards the femoral wall. Finally, the ultimate treatment (repair or reconstruction) was assessed and noted. Institutional Review Board approval was obtained from the Hospital for Special Surgery (IRB #16006).

## Statistical analysis

Statistical analysis was performed using SPSS Version 24 (SPSS Inc., Armonk, NY, USA). Independent t-tests were used to compare continuous data, and chi-square tests were used to compare nominal data. A flowchart was created to assess what percentage of patients could ultimately be repaired based on the tear location and tissue quality based on preoperative MRI. Continuous data was presented in mean  $\pm$  standard deviation (SD). All tests were two-sided and a difference of  $p < 0.05$  was considered statistically significant. Sample size calculation revealed that 34 patients were needed in both groups in order to show a 20% difference with a power of 0.80 and a p-value of 0.05.

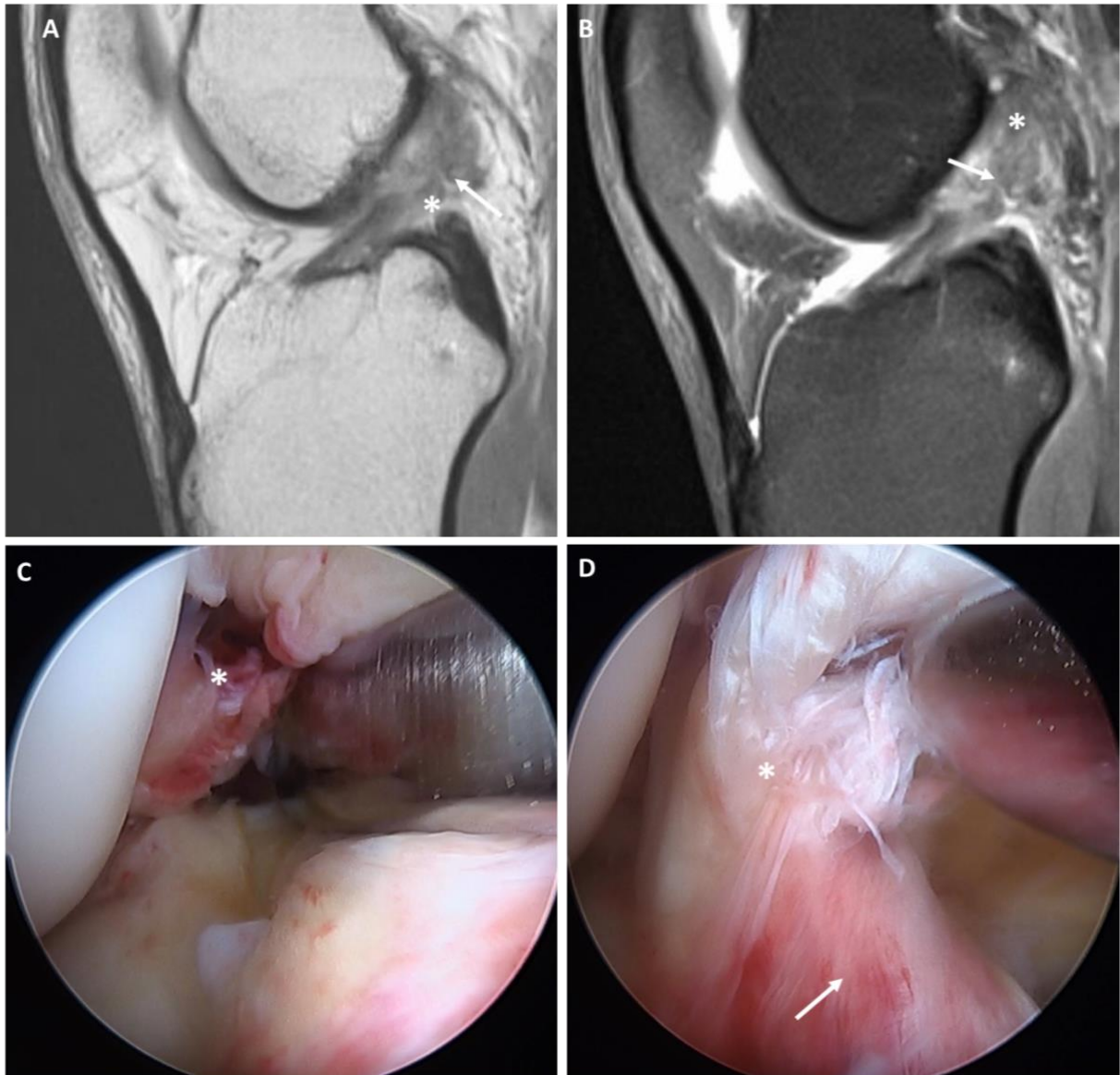


**Figure 1.** Sagittal T1 (A) and T2 (B) views show a type I proximal avulsion tear (arrows) with good tissue quality, characterized by homogeneous dark signal of fibers running in the same direction on T2 views (B). With arthroscopy, the tissue quality (asterix) is confirmed (C), and probing of the ligament (D) shows a proximal type I tear with sufficient tissue length and an empty femoral wall (asterix), although some scar tissue is found between the remnant and the wall (arrow). Primary repair was performed without the need of an InternalBrace.

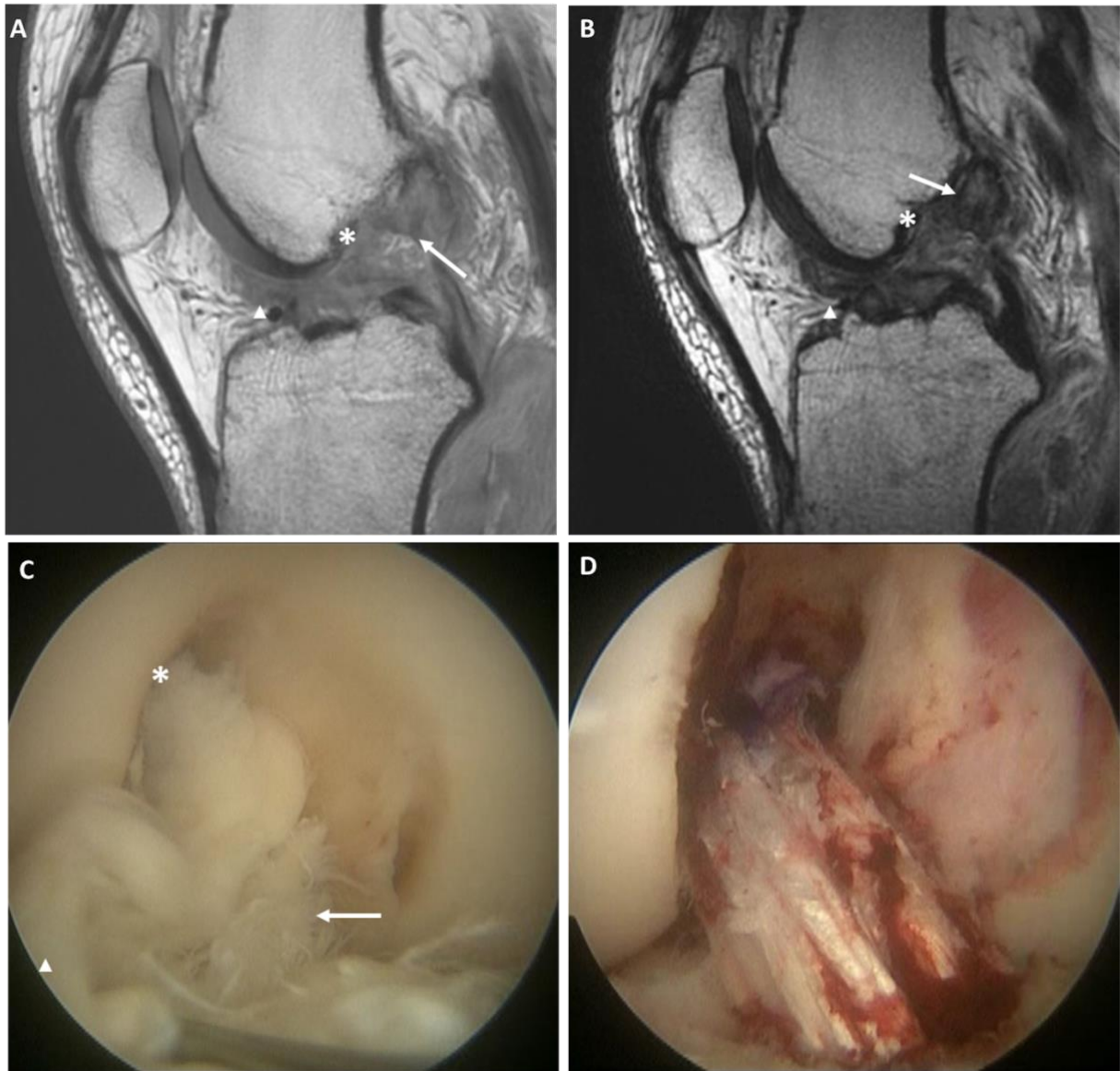


**Figure 2.** Sagittal T1 (A) and T2 (B) views show a type II proximal tear (arrows) with good tissue quality (asterix). Arthroscopy with probing (asterix) confirms that sufficient tissue length for primary repair is present (C). Some fibers of the posterolateral bundle are present on the femoral wall (D, arrow), which explains the discrepancy between a type II tear on MRI and a type I proximal avulsion tear on arthroscopy (asterix). Primary repair was performed and an InternalBrace was added.

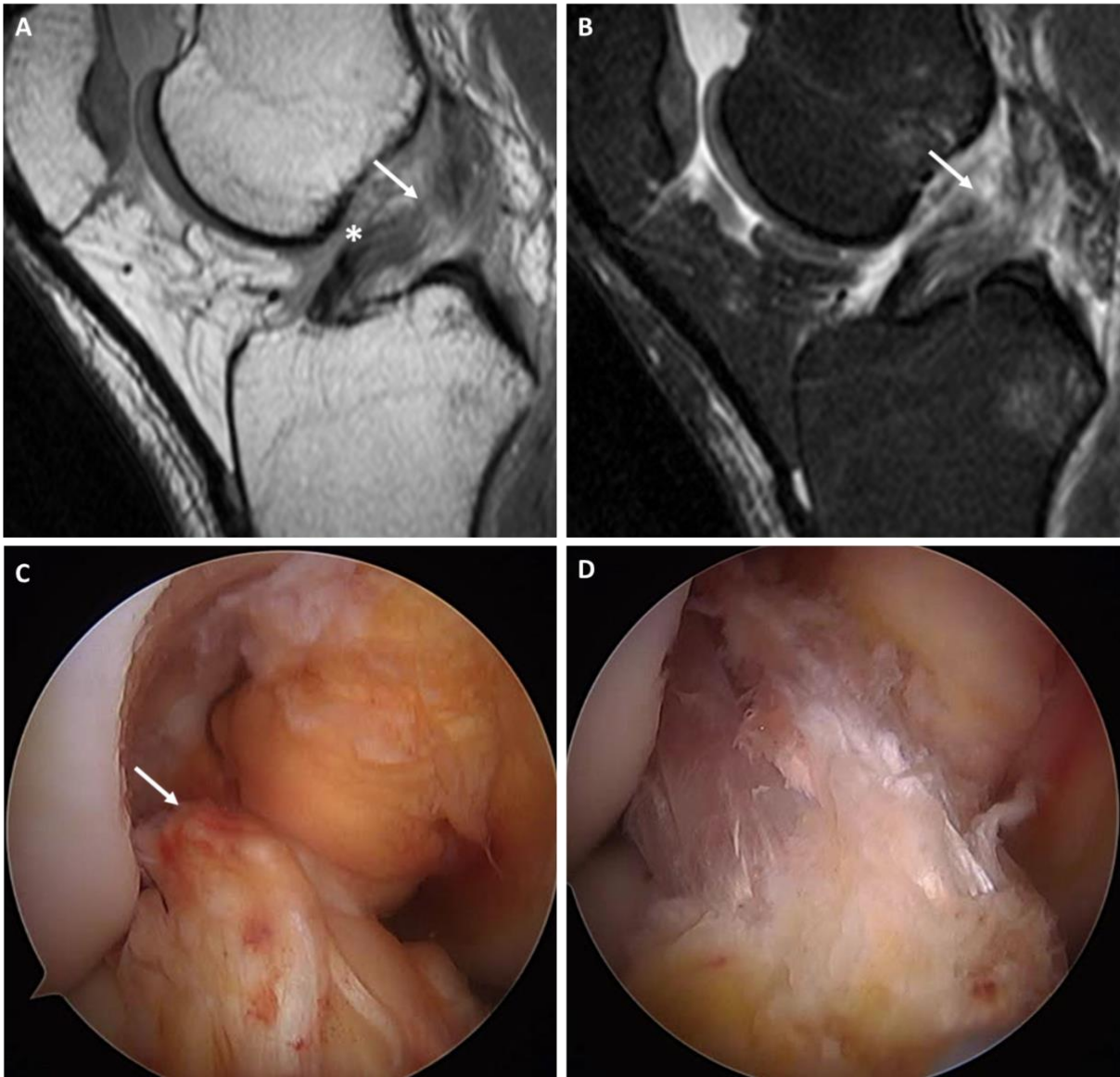




**Figure 3.** Sagittal T1 (A) and T2 (B) views show a type II proximal tear (arrows) with fair tissue quality (asterix in A) and some fibers on the femoral wall (asterix in B). Arthroscopy with probing (C) confirms that some fibers are present on the femoral wall (asterix), and that most of ligament has sufficient tissue quality (D, arrow) but is not perfect (asterix). This ligament could be repaired and was reinforced with an InternalBrace.



**Figure 4.** Sagittal T1 (A) and T2 (B) views show a type II proximal tear (arrows) with poor tissue quality (asterix) and partially flipped ligament (arrowhead). Arthroscopy (C) confirms the proximal tear (asterix) with poor and unrepairable tissue quality (arrow) and partially flipped ligament (arrowhead), after which ACL reconstruction (D) is performed.



**Figure 5.** Sagittal T1 (A) and T2 (B) views show a type III midsubstance tear (arrows) with good tissue quality (asterisk). Arthroscopy (C) confirms the midsubstance tear location, and ACL reconstruction is performed (D).

**Table 2.** The grading scales that were used to define the tear location and tissue quality of all patients on preoperative MRI

<b>Tear Location</b>	<b>Examples</b>	<b>Location of tear</b>			
Type I	Figure 1	>90% distal remnant length			
Type II	Figures 2, 3, 4	75-90% distal remnant length			
Type III	Figure 5	25-75% distal remnant length			
<b>Tissue quality</b>	<b>Examples</b>	<b>Direction fibers</b>	<b>Fluid in ligament</b>	<b>Signal T1</b>	<b>Signal T2</b>
Good	Figures 1, 2	Same direction	None	Homogenous	Low (dark)
Fair	Figures 3, 5	Most in same direction	Some	Mildly heterogeneous	Medium (dark-gray)
Poor	Figure 4	Different directions	Much	Heterogeneous	High (light-gray)

MRI indicates magnetic resonance imaging

## Results

### Preoperative MRI findings

In the total cohort, 22% of patients had a type I tear, 55% a type II tear, and 22% a type III tear. Most patients had good tissue quality (49%), while 28% had fair and 23% had poor tissue quality. The most commonly observed combinations of tear location and tissue quality were type I tears with good tissue quality (20%; Figure 1), type II with good tissue quality (26%; Figure 2), type II with fair tissue quality (17%; Figure 3), type II with poor tissue quality (14%; Figure 4) (Table 3).

Type I tears were more commonly seen in repair patients (41% vs. 4%,  $p < 0.001$ ), and type III tears were more commonly seen in reconstruction patients (37% vs. 6%,  $p < 0.001$ ), while there was no difference in incidence of type II tears in repair and reconstruction patients (52% vs. 58%, respectively,  $p = n.s.$ ). In the repair group, significantly more patients had good tissue quality compared to reconstruction patients (89% vs. 12%,  $p < 0.001$ ), while reconstruction patients had more often fair (43% vs. 11%,  $p < 0.001$ ) or poor (44% vs. 0%,  $p < 0.001$ ) tissue quality than repair patients.

### Predictive role of tear location on MRI

It was noted that 90% of all MRI type I tears, 47% of MRI type II tears and 14% of MRI type III tears were eligible for and treated with primary repair (Figure 1). One patient with an MRI type II tear was found eligible for primary repair but was converted to reconstruction after a significant gap was noted between the femoral wall and the repaired ligament after Internal Brace tensioning (Table 3).

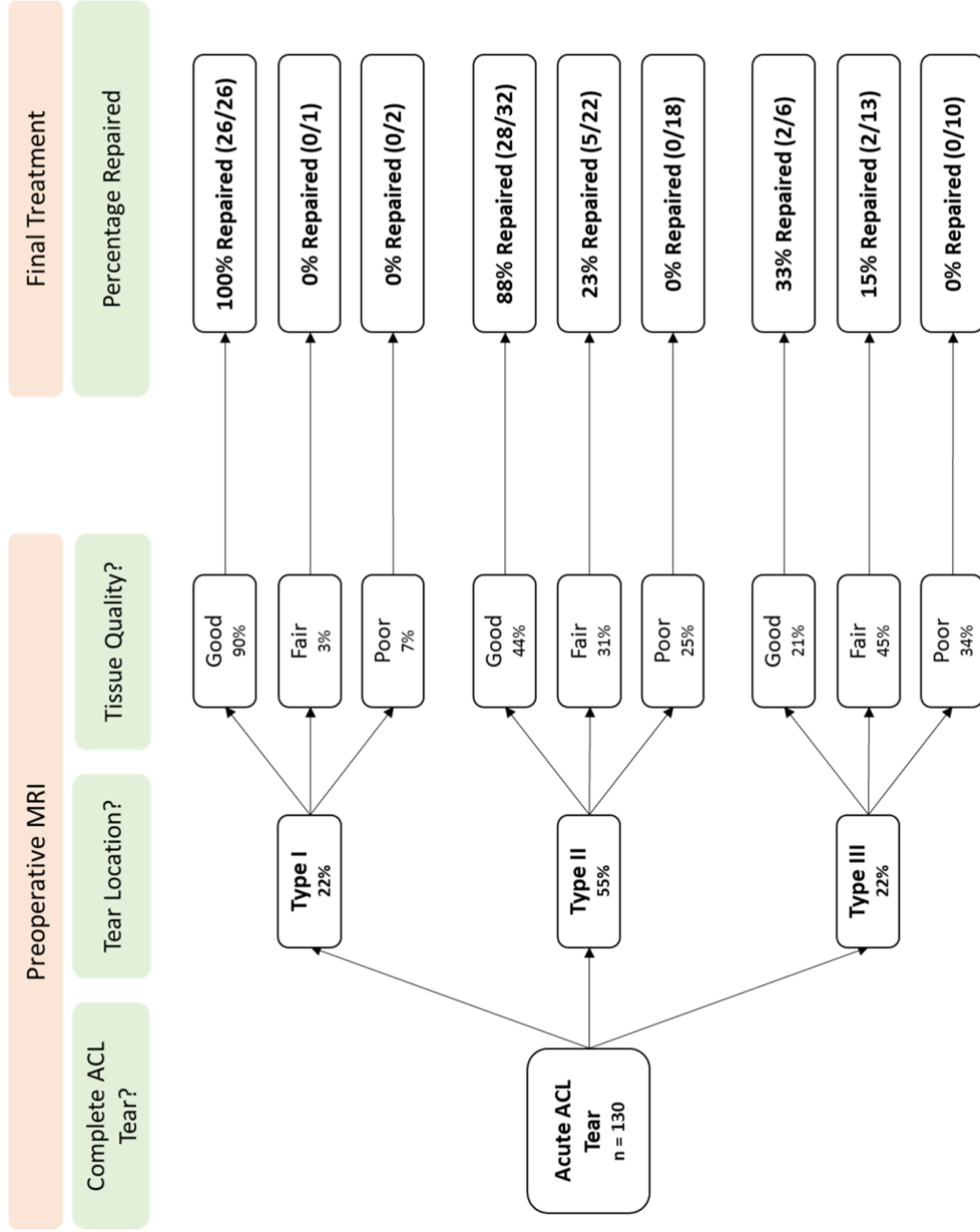
### Predictive role of combination of tear location and tissue quality on MRI

It was noted that all patients with type I tears with good tissue quality were repaired. Of all patients with type II tears, it was noted that 88% of patients with good tissue quality, 23% of patients with fair tissue quality, and 0% of patients with poor tissue quality were repaired. Finally, it was noted that 33% (2/6) patients with type III tears with good tissue quality, 15% of patients with type III tears with fair tissue quality, and no patients with type III tears and poor tissue quality were repaired (Figure 6).

**Table 3.** Incidence of tear location and tissue quality on preoperative MRI in this cohort

<b>MRI Grading</b>	<b>Total cohort n (%)</b>	<b>Repair n (%)</b>	<b>Reconstruction n (%)</b>	<b>P-value</b>
<b>Tear Location</b>				
Type I	29 (22%)	26 (41%)	3 (4%)	<0.001
Type II	72 (55%)	33 (52%)	39 (58%)	n.s.
Type III	29 (22%)	4 (6%)	25 (37%)	<0.001
<b>Tissue Quality</b>				
Good	64 (49%)	56 (89%)	8 (12%)	<0.001
Fair	36 (28%)	7 (11%)	29 (43%)	<0.001
Poor	30 (23%)	0 (0%)	30 (45%)	<0.001
<b>Tear Location &amp; Tissue Quality</b>				
Type I & Good	26 (20%)	26 (41%)	0 (0%)	<0.001
Type I & Fair	1 (1%)	0 (0%)	1 (1%)	n.s.
Type I & Poor	2 (2%)	0 (0%)	2 (3%)	n.s.
Type II & Good	32 (26%)	28 (44%)	4 (6%)	<0.001
Type II & Fair	22 (17%)	5 (8%)	17 (25%)	0.008
Type II & Poor	18 (14%)	0 (0%)	18 (27%)	<0.001
Type III & Good	6 (5%)	2 (3%)	4 (5%)	n.s.
Type III & Fair	13 (10%)	2 (3%)	11 (16%)	0.022
Type III & Poor	10 (8%)	0 (0%)	10 (15%)	0.002

MRI indicates preoperative magnetic resonance imaging



**Figure 6.** A flowchart, based on preoperative MRI tear location and tissue quality, shows the percentage of patients that were repaired per location and tissue quality.

## Discussion

The main findings of this study were that preoperative MRI provided important predictive information on the eligibility and possibility of arthroscopic primary repair of the proximal ACL tears. In this cohort, 90% of type I tears and 46% of type II tears could be repaired, while only 14% of type III tears were repairable. Using tear location and tissue quality on preoperative MRI, it was noted that 93% of patients with the combination of type I or II tears and good tissue quality could be repaired. These data can significantly aid the orthopaedic surgeon in making a preoperative assessment of arthroscopic primary repair of proximal ACL tears.

Sherman et al. were the first to note the role of tear location and tissue quality on the outcomes of open primary ACL repair in 1991.<sup>14</sup> Following their study, several authors reported on treating of proximal (type I) tears with open primary<sup>15, 16</sup> or augmented repair.<sup>30, 31</sup> Genelin et al. published the mid-term outcomes of open primary repair of proximal ACL tears, and found no deterioration of outcomes at mid-term follow-up in this selective group,<sup>16</sup> as opposed to several studies that noted deterioration at mid-term follow-up when performing primary repair in all tear types.<sup>10, 13, 32</sup> In these years, MRI was not widely available, and therefore no historical studies assessed the role of preoperative MRI on patient selection for primary repair of proximal ACL tears.<sup>33-35</sup> At the time that MRI became widely available, the operative treatment of ACL injuries had already shifted towards ACL reconstruction for all tear types, and thus, there was no clinical need for the assessment of tear location and tissue quality.

In 2015, twenty years after the last original studies on primary repair, DiFelice et al. renewed the interest in primary repair using arthroscopic surgery.<sup>18</sup> The authors reported excellent clinical outcomes at mean 3.5-year follow-up on the first 11 patients treated by arthroscopic suture anchor repair of proximal tears, with only one early failure (9%). Subsequently, others have reported similar promising outcomes of arthroscopic primary repair in adult<sup>19</sup> and paediatric patients.<sup>20, 21</sup> With the recent resurgence of interest in ACL preservation,<sup>27-29</sup> and especially primary ACL repair,<sup>18-21, 36</sup> and the modern availability of MRI, MRI can assist orthopaedic surgeons in making a preoperative assessment regarding the eligibility of arthroscopic primary ACL repair.

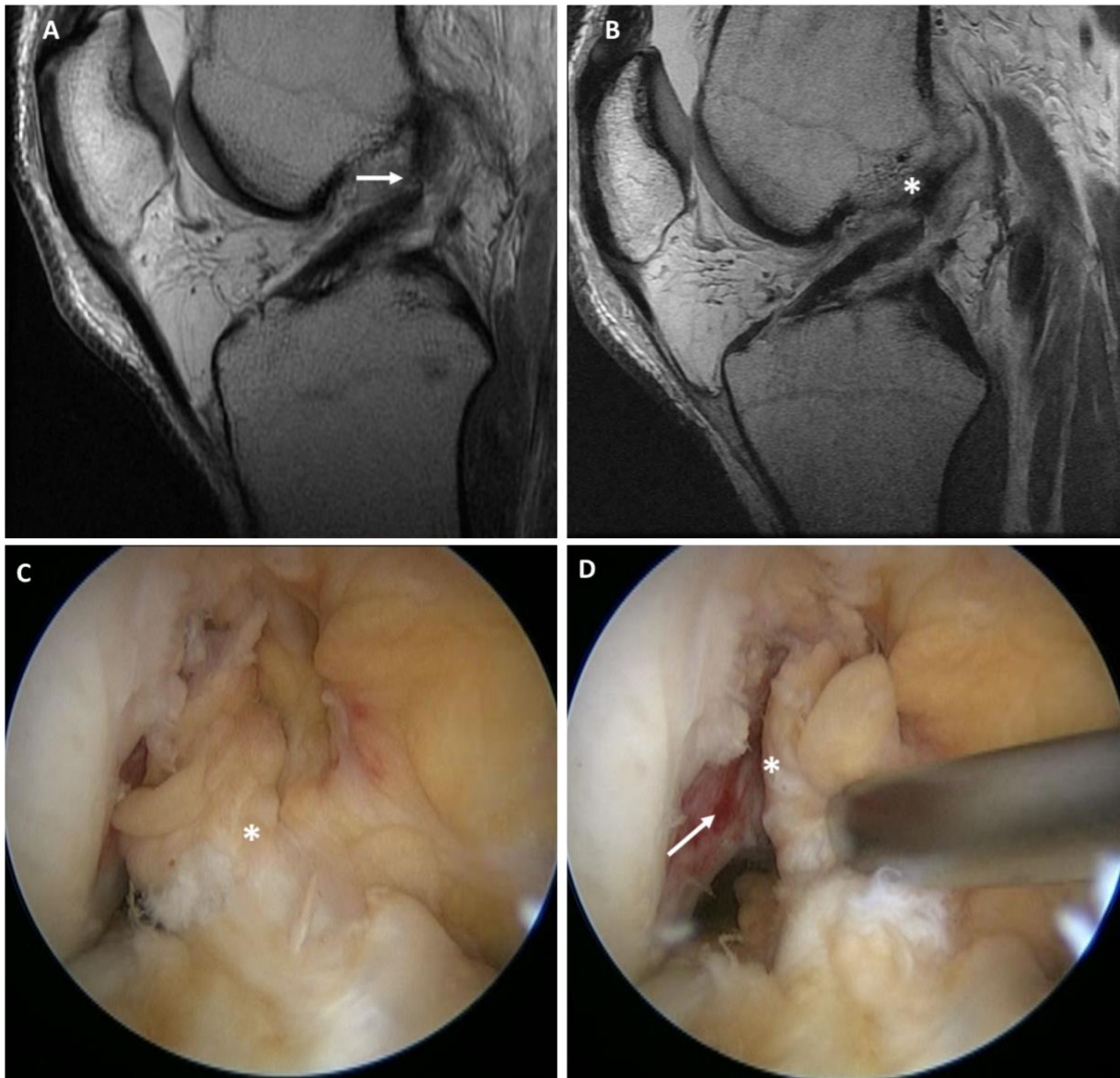
In this study, the classification system for tear location and tissue quality was partially based on recent publications on ACL preservation and primary ACL repair,<sup>27-29</sup> and partially on the historical study by Sherman et al.<sup>14</sup> A recent review summarized the available treatment options of ACL preservation using the same tear type classification, in which primary repair was discussed for type I tears, and primary repair or augmented repair for type II tears.<sup>28,29</sup> Furthermore, Murray et al. recently started a clinical trial with primary ACL repair with an additional biologic scaffold in patients with type III tears (<75% of distal remnant length). In a previous study, van der List et al. showed substantial interobserver reliability (Kappa 0.670) and substantial to nearly perfect intra-observer reliability (Kappa 0.741 – 0.934) using this



classification.<sup>26</sup> For tissue quality, a similar approach was used as the study by Sherman et al., in which the tear types were also graded in three categories.<sup>14</sup>

When only taking preoperative MRI tear location into account, it was noted that 90% of patients with type I tears could be treated with primary repair. Achtnich et al. recently compared the outcomes of arthroscopic primary repair with ACL reconstruction.<sup>19</sup> They included 22 patients in the repair group that all had type I tears on preoperative MRI, and performed primary repair in 21 patients (95%) that had sufficient tissue quality, which is similar to the percentage of patients with MRI type I tears that underwent primary repair in our cohort (90%). Of all patients with MRI type II tears, 46% were treated with primary repair. Taking a closer look at this 50:50 group in Table 3, it can be noted that 88% of the patients with MRI type II tears with good tissue quality could be repaired, while only 13% (5/40) of MRI type II tears with fair or poor tissue quality could be repaired. Reviewing these subgroups, the data suggests that the distal remnants of type II tears have sufficient length to be reinserted on the femoral wall, and that the possibility for primary repair mainly depends on the tissue quality. A possible reason for the finding that the distal remnant length of type II MRI tears was sufficient for primary repair is that some fibers from the posterolateral bundle are torn slightly more distal, which leaves some fibers attached on the femoral wall and this leads to a type II appearance on MRI. This tear pattern was frequently seen (Figure 2), and suggests that MRI can underestimate the distal remnant length. The finding that 88% of type II tears with good tissue quality was repaired, indicates that the tissue length of type II MRI tears is sufficient for reinsertion, and that repair of these tears mainly depends on tissue quality.

Another explanation for the finding that type II tears with good tissue quality on MRI can be repaired, is that sagittal images are likely not transecting the ligament along its anatomical course, and therefore they are not accurately displaying the location of the tear. In 22 patients, sagittal oblique and/or coronal oblique views were available, and in four of these cases, the tear type changed from type III (n = 1) or type II (n = 3) to a type I tear (example in Figure 7). Over the last decade, some studies have assessed the role of sagittal oblique and coronal oblique imaging for ACL injuries, and concluded that these can have additional value in the diagnosis for ACL tears.<sup>37-39</sup> Interestingly for primary repair, Kosaka et al. highlighted that especially the femoral attachment can be clearly visualized with these views<sup>38</sup> The findings in this current study show that obtaining sagittal oblique and coronal oblique views have additional value for assessing eligibility for arthroscopic primary ACL repair.



**Figure 7.** Sagittal T1 view (A) shows a type II proximal tear, but sagittal oblique ACL view (B) shows a type I proximal avulsion tear. Arthroscopy (C) confirms sufficient tissue quality for repair (although not optimal), and proximal type I avulsion type tear (D) with an empty wall (arrow) and avulsed distal remnant (asterix). Primary repair was performed and an InternalBrace was not needed.

One patient in the MRI type II group with good tissue quality was graded as eligible for primary repair but was ultimately not repaired (Figure 6). In this patient, an internal brace was added to the primary repair after the ACL was repaired to the femoral wall with suture anchors. Because the internal brace was inserted at the proximal end of the ACL remnant and was tensioned through the ligament, this resulted in the repaired ligament pulling off the femoral wall, and this resulted in a gap forming between the ligament and the femoral wall. A decision was made to convert the patient to an ACL reconstruction, as it was expected that healing would not occur due to this gap.<sup>40</sup>

Limitations are present in this study. First of all, the numbers in this study cannot be used for a true assessment of the tear type incidence, as patients are referred to the practice of the senior author for primary ACL repair surgery. Studies assessing the incidence of the different tear types in a cohort of consecutive patients are necessary. Secondly, it is currently not known if the differences in tissue quality affect the outcomes of primary repair at longer-term follow-up. However, the goal of this study was to assess the correlation of tear location and tissue quality on MRI with arthroscopy. Follow-up studies are necessary if differences in outcomes exist between these different groups. Thirdly, this study is a retrospective cohort study, and the nature of this study increases the risk of bias. A similar study using a prospective design is necessary to confirm these findings. Nonetheless, the data in this study are valuable for the orthopaedic surgeon and provides information for preoperative assessment on the possibility of primary ACL repair.

The findings in this study can guide the orthopaedic surgeon in making a preoperative assessment on whether primary ACL repair can be successfully performed. Patients with tears in the proximal quarter and good tissue quality can be informed that it is likely that arthroscopic primary repair can be performed and the advantages and disadvantages of the procedure should be explained in this subgroup of patients.

## **Conclusion**

This study showed that tear location and tissue quality on preoperative MRI could be used to predict the eligibility of primary ACL repair. More specifically, it was noted that 93% of patients with a type I or II tear (i.e., tear located at proximal 25% of ligament) and with good tissue quality were repairable. Furthermore, it was noted that sagittal and coronal oblique views provided additional information on tear location.

## References

1. O'Donoghue DH. Surgical treatment of fresh injuries to the major ligaments of the knee. *J Bone Joint Surg Am.* 1950;32(4):721-738.
2. O'Donoghue DH. An analysis of end results of surgical treatment of major injuries to the ligaments of the knee. *J Bone Joint Surg Am.* 1955;37(1):1-13.
3. Palmer I. On the injuries to the ligaments of the knee joint. *Acta Orthop Scand.* 1938;53.
4. Palmer I. On the injuries to the ligaments of the knee joint: A clinical study. 1938. *Clin Orthop Relat Res.* 2007;454:17-22.
5. Robson AW. Vi. Ruptured crucial ligaments and their repair by operation. *Ann Surg.* 1903;37(5):716-718.
6. van der List JP, DiFelice GS. Primary repair of the anterior cruciate ligament: A paradigm shift. *Surgeon.* 2017;15(3):161-168.
7. England RL. Repair of the ligaments about the knee. *Orthop Clin North Am.* 1976;7(1):195-204.
8. Feagin JA, Abbott HG, Rokous JR. The isolated tear of the anterior cruciate ligament. *J Bone Joint Surg Am.* 1972;54(6):1340-1341.
9. Liljedahl SO, Lindvall N, Wetterfors J. Early diagnosis and treatment of acute ruptures of the anterior cruciate ligament; a clinical and arthrographic study of forty-eight cases. *J Bone Joint Surg Am.* 1965;47(8):1503-1513.
10. Feagin JA, Jr., Curl WW. Isolated tear of the anterior cruciate ligament: 5-year follow-up study. *Am J Sports Med.* 1976;4(3):95-100.
11. Marshall JL, Warren RF, Wickiewicz TL. Primary surgical treatment of anterior cruciate ligament lesions. *Am J Sports Med.* 1982;10(2):103-107.
12. Marshall JL, Warren RF, Wickiewicz TL, Reider B. The anterior cruciate ligament: A technique of repair and reconstruction. *Clin Orthop Relat Res.* 1979;143:97-106.
13. Kaplan N, Wickiewicz TL, Warren RF. Primary surgical treatment of anterior cruciate ligament ruptures. A long-term follow-up study. *Am J Sports Med.* 1990;18(4):354-358.
14. Sherman MF, Lieber L, Bonamo JR, Podesta L, Reiter I. The long-term followup of primary anterior cruciate ligament repair. Defining a rationale for augmentation. *Am J Sports Med.* 1991;19(3):243-255.
15. Bram J, Plaschy S, Lutolf M, Leutenegger A. [The primary cruciate ligament suture - is the method outdated? Results in follow-up of 58 patients]. *Z Unfallchir Versicherungsmed.* 1994;87(2):91-109.
16. Genelin F, Trost A, Primavesi C, Knoll P. Late results following proximal reinsertion of isolated ruptured acl ligaments. *Knee Surg Sports Traumatol Arthrosc.* 1993;1(1):17-19.
17. van der List JP, DiFelice GS. Role of tear location on outcomes of open primary repair of the anterior cruciate ligament: A systematic review of historical studies. *Knee.* 2017;24(5):898-908.
18. DiFelice GS, Villegas C, Taylor SA. Anterior cruciate ligament preservation: Early results of a novel arthroscopic technique for suture anchor primary anterior cruciate ligament repair. *Arthroscopy.* 2015;31(11):2162-2171.
19. Achtnich A, Herbst E, Forkel P, Metzloff S, Sprenger F, Imhoff AB, Petersen W. Acute proximal anterior cruciate ligament tears: Outcomes after arthroscopic suture anchor repair versus anatomic single-bundle reconstruction. *Arthroscopy.* 2016;32(12):2562-2569.
20. Bigoni M, Gaddi D, Gorla M, Munegato D, Pungitore M, Piatti M, Turati M. Arthroscopic anterior cruciate ligament repair for proximal anterior cruciate ligament tears in skeletally immature patients: Surgical technique and preliminary results. *Knee.* 2017;24(1):40-48.
21. Smith JO, Yassen SK, Palmer HC, Lord BR, Britton EM, Wilson AJ. Paediatric ACL repair reinforced with temporary internal bracing. *Knee Surg Sports Traumatol Arthrosc.* 2016;24(6):1845-1851.
22. van der List JP, DiFelice GS. Successful arthroscopic primary repair of a chronic anterior cruciate ligament tear 11 years following injury. *HSS J.* 2017;13(1):90-95.
23. DiFelice GS, van der List JP. Regarding "acute proximal anterior cruciate ligament tears: Outcomes after arthroscopic suture anchor repair versus anatomic single-bundle reconstruction". *Arthroscopy.* 2017;33(4):693-694.
24. DiFelice GS, van der List JP. Arthroscopic primary repair of proximal anterior cruciate ligament tears. *Arthrosc Tech.* 2016;5(5):E1057-E1061.

25. Mackay GM, Blyth MJ, Anthony I, Hopper GP, Ribbans WJ. A review of ligament augmentation with the internal brace: The surgical principle is described for the lateral ankle ligament and ACL repair in particular, and a comprehensive review of other surgical applications and techniques is presented. *Surg Technol Int.* 2015;26:239-255.
26. van der List JP, Mintz DN, DiFelice GS. The location of anterior cruciate ligament tears: A prevalence study using magnetic resonance imaging. *Orthop J Sports Med.* 2017;5(6):2325967117709966.
27. Murray MM, Flutie BM, Kalish LA, Ecklund K, Fleming BC, Proffen BL, Micheli LJ. The bridge-enhanced anterior cruciate ligament repair (BEAR) procedure: An early feasibility cohort study. *Orthop J Sports Med.* 2016;4(11):2325967116672176.
28. van der List JP, DiFelice GS. Preservation of the anterior cruciate ligament: A treatment algorithm based on tear location and tissue quality. *Am J Orthop (Belle Mead NJ).* 2016;45(7):E393-E405.
29. van der List JP, DiFelice GS. Preservation of the anterior cruciate ligament: Surgical techniques. *Am J Orthop (Belle Mead NJ).* 2016;45(7):E406-414.
30. Grontvedt T, Engebretsen L. Comparison between two techniques for surgical repair of the acutely torn anterior cruciate ligament. A prospective, randomized follow-up study of 48 patients. *Scand J Med Sci Sports.* 1995;5(6):358-363.
31. Kdolsky R, Kwasny O, Schabus R. Synthetic augmented repair of proximal ruptures of the anterior cruciate ligament. Long-term results of 66 patients. *Clin Orthop Relat Res.* 1993;295:183-189.
32. Straub T, Hunter RE. Acute anterior cruciate ligament repair. *Clin Orthop Relat Res.* 1988;227:238-250.
33. Mink JH, Levy T, Crues JV, 3rd. Tears of the anterior cruciate ligament and menisci of the knee: MR imaging evaluation. *Radiology.* 1988;167(3):769-774.
34. Turner DA, Prodromos CC, Petasnick JP, Clark JW. Acute injury of the ligaments of the knee: Magnetic resonance evaluation. *Radiology.* 1985;154(3):717-722.
35. Widhalm HK, Surer L, Kurapati N, Guglielmino C, Irrgang JJ, Fu FH. Tibial ACL insertion site length: Correlation between preoperative mri and intra-operative measurements. *Knee Surg Sports Traumatol Arthrosc.* 2016;24(9):2787-2793.
36. van der List JP, DiFelice GS. Range of motion and complications following primary repair versus reconstruction of the anterior cruciate ligament. *Knee.* 2017; 24(4):798-807.
37. Barberie JE, Carson BW, Finnegan M, Wong AD. Oblique sagittal view of the anterior cruciate ligament: Comparison of coronal vs. Axial planes as localizing sequences. *J Magn Reson Imaging.* 2001;14(3):203-206.
38. Kosaka M, Nakase J, Toratani T, Ohashi Y, Kitaoka K, Yamada H, Komura K, Nakamura S, Tsuchiya H. Oblique coronal and oblique sagittal MRI for diagnosis of anterior cruciate ligament tears and evaluation of anterior cruciate ligament remnant tissue. *Knee.* 2014;21(1):54-57.
39. Park HJ, Lee SY, Park NH, Ahn JH, Chung EC, Kim SJ, Cha JG. Three-dimensional isotropic T2-weighted fast spin-echo (vista) knee MRI at 3.0 T in the evaluation of the anterior cruciate ligament injury with additional views: Comparison with two-dimensional fast spin-echo T2-weighted sequences. *Acta Radiol.* 2016;57(11):1372-1379.
40. van der List JP, DiFelice GS. Gap formation following primary repair of the anterior cruciate ligament: A biomechanical evaluation. *Knee.* 2016;24(2):243-249.



# Chapter 7

## **Identifying candidates for arthroscopic primary repair of the anterior cruciate ligament: a case-control study**

Jelle P. van der List

Anne Jonkergouw

Arthur van Noort

Gino M.M.J. Kerkhoffs

Gregory S. DiFelice

*Knee. 2019 Jun;26(3):619-627.*

## **Abstract**

### **Introduction**

There has been a recent resurgence of interest in arthroscopic primary repair of proximal anterior cruciate ligament (ACL) tears. Patient selection is critical but not much is currently known on what predicts the possibility of repair. Goal of this study was therefore to assess predictive factors for the possibility of arthroscopic primary ACL repair.

### **Methods**

In this retrospective case–control study, all patients undergoing ACL surgery in a ten-year interval were included. Patients were treated with primary repair if there was a proximal tear and good tissue quality, or otherwise underwent ACL reconstruction. Collected data were age, gender, BMI, injury-to-surgery delay, injury mechanism and concomitant injuries. Receiver operating characteristic curves were used to find cutoff values, and all significant dependent variables were used in multivariate logistic analysis to assess independent predictors for the possibility of primary repair.

### **Results**

Three hundred sixty-one patients were included, of which in 158 patients (44%) primary repair was possible. Multivariate analysis ( $R^2 = 0.340$ ,  $p = 0.001$ ) showed that age > 35 years (Odds ratio [OR] 4.2, 95% CI 2.4–7.5,  $p = 0.001$ ), surgery within 28 days (OR 3.3, 95% CI 1.9–5.7,  $p = 0.001$ ), and BMI <26 (OR 1.9, 95% CI 1.1–3.3,  $p = 0.029$ ) were predictive for the possibility of primary repair, and lateral meniscus injury presence decreased the likelihood of repair (OR 0.5, 95% CI 0.3–0.8,  $p = 0.008$ ).

### **Conclusions**

In this large cohort study, it was noted that 44% of patients had repairable ACL tears. Primary repair was more likely to be possible in older patients, patients with lower BMI and when surgery was performed within four weeks of injury.



## Introduction

Over the last decade, there has been a resurgence of interest in arthroscopic primary repair of the anterior cruciate ligament (ACL).<sup>1-6</sup> The concept of primary repair is not new and this technique was commonly performed in the 1970s and 1980s using an open approach and the short-term outcomes were promising.<sup>7-13</sup> After several authors noticed a deterioration of outcomes at mid-term follow-up,<sup>14-19</sup> the technique was abandoned and ACL reconstruction became the gold standard for ACL injuries in younger and active patients, which it still is today.<sup>20</sup>

Although the outcomes of ACL reconstruction are nowadays generally good with low graft rupture rates and satisfying functional outcomes in most patients,<sup>21-24</sup> ACL reconstruction also has disadvantages. These include significant donor site morbidity<sup>21-24</sup>, loss of the native ligament along with its proprioception<sup>25</sup>, disappointing return to sports rate<sup>26,27</sup> and not preventing osteoarthritis.<sup>28-30</sup> Furthermore, high failure rates and reoperation rates have been reported in younger patients<sup>31-33</sup> and revision surgery is often complicated and has inferior outcomes.<sup>34-36</sup> These disadvantages have led to the search for other surgical options for ACL tears including primary repair.<sup>1,37,38</sup>

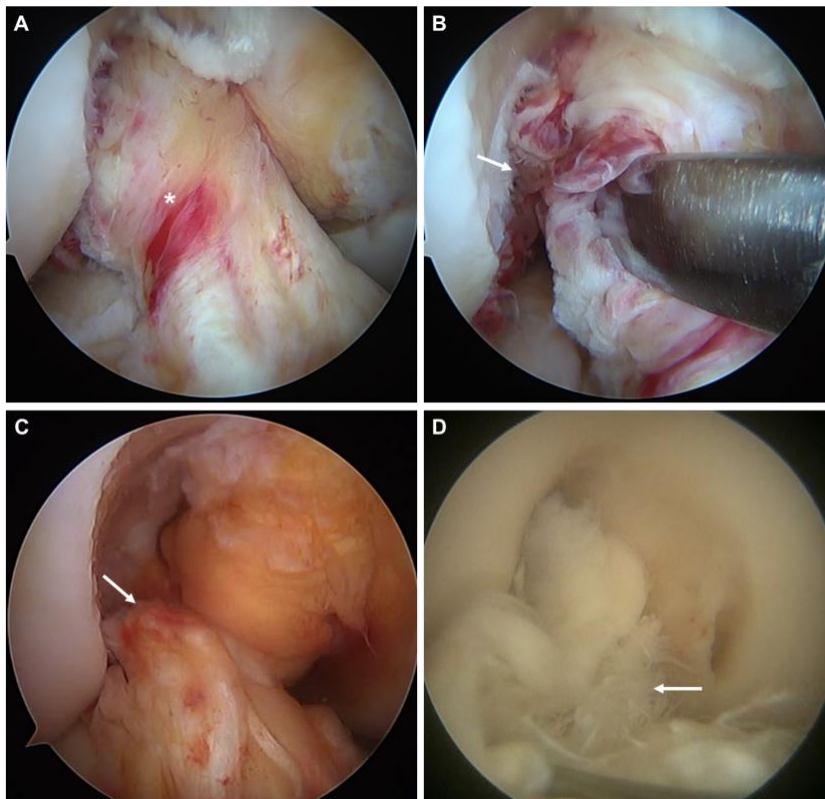
Recently, it has been suggested that the primary repair concept may historically have been prematurely abandoned for all patients as there is a subgroup of patients (i.e. with proximal tears) that have good outcomes of repair in both the historical<sup>19,20,39,40</sup> and modern literature.<sup>1-6,41</sup> This can be explained by the fact that there is better vascularity in the proximal part of the ligament<sup>42</sup> and thus good healing potential of these proximal tears<sup>43</sup>, while the vascularity of midsubstance tears is inferior and healing will not occur in these tear types.<sup>44, 45</sup> Potential advantages of primary repair are less invasive surgery with shorter operation time<sup>46</sup> and earlier regain of range of motion (ROM) than reconstruction,<sup>46</sup> and experimental studies that have suggested that primary repair may decrease the risk of osteoarthritis when compared to ACL reconstruction.<sup>47, 48</sup> Furthermore, no bridges are burned for reconstruction surgery in case primary repair fails. Potential disadvantages of primary repair are failure rates that may be higher than ACL reconstruction - basing on the historical data of all tear types<sup>39</sup> - and subsequent meniscal and chondral injuries that may occur with rerupture.

With this renewed interest, the indications of primary repair have been narrowed when compared to the historical literature: these are proximal tears (that can be reattached to the femoral insertion) and good tissue quality (that is most commonly seen in the (sub)acute phase of weeks after injury). With these new indications, several cohort studies have reported excellent outcomes of arthroscopic primary repair of proximal tears.<sup>1-6,49-51</sup> No studies, however, have yet assessed which patient or injury characteristics are associated with the possibility of primary repair. The goal of this study was therefore to assess which patients and injury characteristics are predictive of a repairable proximal tear. The hypothesis was that older age, skiing injury and early surgery would be predictive for the possibility of performing primary repair.

## Materials and methods

### Study design

Institutional review board approval was obtained for this retrospective case-control study. All consecutive patients that underwent surgical treatment for an ACL injury in a 10-year period (between April 1st 2008 and March 31st 2018) by the senior author (GSD) were included in this study (n = 406). Exclusion criteria consisted of true knee dislocations (n = 41), patients with partial ACL tears (n = 1) and with concomitant high tibial osteotomy (n = 2). Patients with knee dislocations were excluded but not patients with other concomitant ligamentous injuries outside the setting of knee dislocations, such as a patient with an ACL-MCL injury. All patients had an MRI confirmed ACL tear and underwent the following surgical treatment algorithm: intraoperatively it was decided that they would undergo arthroscopic primary ACL repair if (I) a proximal tear was present of which the distal portion was long enough for reattachment to the femoral footprint and (II) tissue quality was good enough for passage and withholding of sutures (Figure 1A and 1B), and if either of these conditions were not present, patients would undergo standard ACL reconstruction using bone-patellar tendon-bone, hamstring or allograft tissue (Figure 1C and 1D). The case-control study was designed to understand the patient and injury characteristics that were predictive of the ultimate treatment (repair or reconstruction).



**Figure 1.** A and B show an ACL tear with excellent tissue quality (asterisk in A) and a proximal avulsion tear that is long enough to reach the femoral wall with reattachment (arrow in B). C shows an ACL tear that is not of sufficient length to reach the femoral wall (arrow). D shows an ACL tear with poor tissue quality that will not withhold sutures (arrow).

## **Surgical technique**

The patient is placed in supine position and the operative leg is prepped and draped for knee arthroscopy. Standard anteromedial and anterolateral portals are created and a general inspection of the knee joint is performed. Then, a probe is used to assess the location of the tear and, if needed, a grasper is used to tension the distal remnant of the ACL proximally to assess if the remnant is long enough for reattachment to the femoral wall. If the remnant is deemed eligible for primary repair, sutures are passed through the ligament and the distal remnant is reinserted into the femoral wall as previously described.<sup>52-54</sup> If the ligament is not deemed eligible for primary repair, standard anatomic ACL reconstruction is performed. This was performed using an anteromedial portal drilling technique.

## **Data collection**

It was registered if patients ultimately underwent primary repair or reconstruction. Patient characteristics collected included age, gender, BMI, time from injury to surgery, and mechanism of injury (type of sport at injury and contact vs. non-contact). Injury characteristics included concomitant injury of the posterior cruciate ligament (PCL), medial collateral ligament (MCL), posteromedial corner (PMC), lateral collateral ligament (LCL), posterolateral corner (PLC), medial meniscus injury, lateral meniscus injury, and chondral injury in the medial tibiofemoral joint (MTFJ), lateral tibiofemoral joint (LTFJ) and patellofemoral joint. Only complete (grade 3) injuries of the ligaments were considered ligament tears for statistical analyses.

## **Statistical analysis**

Statistical analysis was performed using SPSS version 25.0 (IBM Software, Armonk, NY, USA). For continuous variables, Shapiro-Wilk tests were performed to assess normal distribution and no normal distribution was found for all parameters. Baseline characteristics were therefore reported in median with range for continuous variables and number with percentage for nominal variables. Receiver operating characteristic (ROC) curves were first used to find the cutoff values of the continuous variables (age, BMI and delay from injury to surgery). Then, variables between the two groups (repair and reconstruction) were compared using Mann-Whitney U test and using two-by-two tables with Pearson's Chi-square test (in case all cells were >5) or Fisher's exact test (in case one of the cells were <5). All significant dependent variables of these analyses were then used in a multivariate binary logistic regression analysis to assess independent predictors for primary repair, because only a limited number of variables can be used for multivariate analysis and only the potentially relevant (or statistically significant) factors were of interest. Year of surgery was also used as a variable to correct for experience and assess the learning curve effect of primary repair, as this cohort included the first 10 years of experience with arthroscopic primary repair for the senior author. All tests were two-sided and a p-value of <0.05 was considered statistically significant.

## Results

### Baseline characteristics

A total of 361 consecutive patients were included in this study with a median age of 28 years (range 13 – 64 years) and median BMI of 25 kg/m<sup>2</sup> (range 18 – 35 kg/m<sup>2</sup>), of which 59.8% were males. Median delay from injury to surgery was 47 days (range 3 days – 15 years). Most common injury was during soccer (23%), skiing (16%), basketball (13%) and football/rugby (11%), and most injuries were non-contact injuries (85%). Injury to the MCL/PMC was the most common concomitant ligamentous injury (7%). A total of 205 patients (57%) had meniscus injury: 28% had medial meniscus injury and 43% had lateral meniscus injury. Seventy-one patients (20%) had chondral damage. All baseline characteristics are displayed in Table 1. BMI was missing in 18 patients and data on contact vs. non-contact injury was missing in 14 patients.

**Table 1.** Baseline characteristics of the entire cohort and per treatment (repair vs. reconstruction)

Variables	All patients (n = 361)
Male gender (N (%))	216 (59.8%)
Age (years) (median; range)	28.2 (13 – 64)
BMI (kg/m <sup>2</sup> ) (median; range))	24.8 (17 – 47)
Delay (days) (median; range))	47 (3d– 15y)
Injury Mechanism (N (%))	
Basketball	47 (13.0%)
Football/Rugby	40 (11.1%)
Skiing	57 (15.8%)
Soccer	82 (22.7%)
Other	135 (37.4%)
Non-contact injury (N (%))	294 (84.7%)
Any concomitant injuries (N (%))	34 (9.4%)
PCL injury	0 (0.0%)
MCL/PMC injury	27 (7.5%)
LCL/PLC injury	5 (1.4%)
ALL injury	4 (1.1%)
Any meniscus injury	205 (56.8%)
Medial meniscus injury	102 (28.3%)
Lateral meniscus injury	156 (43.2%)
Any chondral damage	71 (19.7%)
Medial TF joint damage	38 (10.5%)
Lateral TF joint damage	16 (4.4%)
PF joint damage	29 (8.0%)

BMI missing in 18 patients; contact/non-contact information missing in 14 patients.

N indicates number; SD, standard deviation; BMI, body mass index; PCL, posterior cruciate ligament; MCL/PMC, medial collateral ligament/posteromedial corner; LCL/PLC, lateral collateral ligament/posterolateral corner; ALL, anterolateral ligament; TF, tibiofemoral; PF, patellofemoral.

## Univariate analysis

ROC curves revealed significant thresholds for age (35 years), BMI (26 kg/m<sup>2</sup>) and delay from injury to surgery (28 days), as is shown in Table 2.

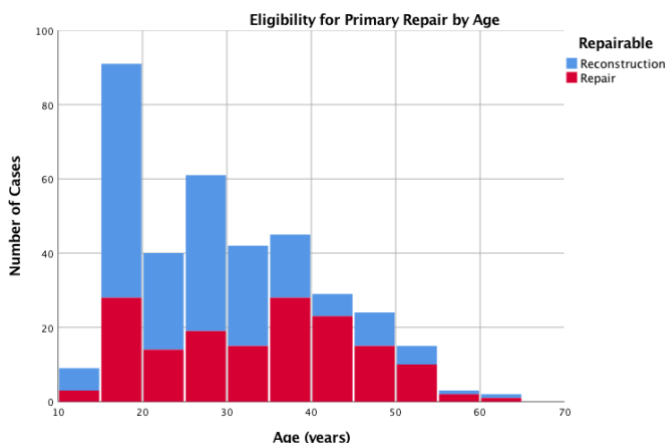
**Table 2.** ROC curves of determining threshold for eligibility for primary ACL repair

Variable	Threshold	AUC (95% CI LB – UB)	SE	P-value	Sensitivity	Specificity
Age	35 years	0.654 (0.596 – 0.712)	0.030	<0.001	0.665	0.571
BMI	26 kg/m <sup>2</sup>	0.569 (0.508 – 0.629)	0.031	0.029	0.759	0.270
Delay	28 days	0.655 (0.598 – 0.713)	0.029	<0.001	0.823	0.462

ROC indicates Receiver Operating Curves; BMI, body mass index; AUC, area under the curve; 95% CI LB – UB, 95% confidence interval lower bound – upper bound; SE, standard error

It was noted that a total of 158 patients (44%) had proximal tears that were eligible for primary repair and ultimately underwent arthroscopic primary ACL repair. The other 203 patients underwent ACL reconstruction of which 104 patients (57%) underwent autograft reconstruction (60 patients (30%) hamstring and 54 patients (27%) bone-patellar tendon-bone), 86 patients (42%) soft tissue allograft reconstruction and 3 patients (1%) hybrid grafts.

Patients that had repairable tears repair were more often females (47% vs. 35%,  $p = 0.023$ ), older (35 vs. 26 years,  $p < 0.001$ ), lower BMI (24 vs. 26 kg/m<sup>2</sup>,  $p = 0.029$ ) and were more often operated within 4 weeks after injury (46% vs. 18%,  $p < 0.001$ ) than patients that did not have repairable tears and ultimately underwent ACL reconstruction. Patients with repairable tears more often suffered skiing injuries (23% vs. 10%,  $p = 0.001$ ), less often football/rugby injuries (6% vs. 15%,  $p = 0.011$ ) than patients that underwent reconstruction, while no difference in non-contact injury was seen ( $p = 0.715$ ). Patients with repairable tears had less often meniscus injuries (47% vs. 65%,  $p = 0.001$ ) and lateral meniscus tears (35% vs. 50%,  $p = 0.004$ ). No differences in chondral damage between both cohorts were found. All univariate analyses are shown in Table 3. A distribution of the repair and reconstruction cases per age are displayed in Figure 2.



**Figure 2.** Histogram showing the number of primary repair and reconstruction cases per age

**Table 3.** Univariate analysis of variables predicting eligibility for primary ACL repair

Variables	Primary repair (n = 158)	Reconstruction (n = 203)	P-value*
Male gender	84 (53.2%)	132 (65.0%)	<b>0.023</b>
Age (years; median (range))	35.0 (14 – 60)	25.6 (13 – 64)	<b>&lt;0.001</b>
≤25 years	64 (40.5%)	136 (67.0%)	
25-35 years	16 (10.1%)	28 (13.8%)	<b>&lt;0.001</b>
≥35 years	78 (49.4%)	39 (19.2%)	
BMI (kg/m <sup>2</sup> ; median (range))	24.4 (18 – 35)	25.7 (17 – 47)	<b>0.029</b>
≤26 kg/m <sup>2</sup>	113 (71.5%)	104 (56.2%)	<b>0.003</b>
Delay (days; median (range))	32 (3 – 5499)	66 (4 – 4865)	<b>&lt;0.001</b>
≤28 days	73 (46.2%)	36 (17.7%)	<b>&lt;0.001</b>
Injury mechanism	30 (19.0%)	52 (25.6%)	0.136
Soccer	30 (19.0%)	52 (25.6%)	0.136
Skiing	36 (22.8%)	21 (10.3%)	<b>0.001</b>
Basketball	16 (10.1%)	31 (15.3%)	0.150
Football/rugby	10 (6.3%)	30 (14.8%)	<b>0.011</b>
Injury type (non-contact)	130 (85.5%)	164 (84.1%)	0.715
Concomitant injuries	18 (11.4%)	16 (7.9%)	0.257
PCL	0 (0.0%)	0 (0.0%)	-
MCL/PMC	15 (9.5%)	12 (5.9%)	0.864
LCL/PLC	2 (1.3%)	3 (1.5%)	>0.999
ALL	3 (1.9%)	1 (0.5%)	0.448
Any Meniscus injury	74 (46.8%)	131 (64.5%)	<b>0.001</b>
Medial Meniscus injury	38 (24.1%)	64 (31.5%)	0.118
Lateral Meniscus injury	55 (34.8%)	101 (49.8%)	<b>0.004</b>
Any Chondral damage	34 (21.5%)	37 (18.2%)	0.435
Medial TF joint	18 (11.4%)	20 (9.9%)	0.636
Lateral TF joint	6 (3.8%)	10 (4.9%)	0.605
PF joint	16 (10.1%)	13 (6.4%)	0.197

BMI indicates body mass index; MCL/PMC, medial collateral ligament/posteromedial corner; LCL/PLC, lateral collateral ligament/posterolateral corner; ALL, anterolateral ligament; MTFJ, medial tibiofemoral joint; LTFJ, lateral tibiofemoral joint; PF, patellofemoral, LB – UB 95% CI, lower bound – upper bound 95% confidence interval.

\* For continuous variables, Mann-Whitney U test is performed, while for nominal variables Chi-square tests of Fishers's exact tests were used.

## Multivariate analysis

All significant factors from univariate analysis were used for multivariate binary logistic regression analysis to find predictors for the possibility of primary ACL repair ( $R^2 = 0.340$ ,  $p < 0.001$ ). Patients were more likely to undergo primary repair if surgery was performed within 4 weeks of injury (OR 3.3,  $p < 0.001$ ), if they were older than 35 years compared to younger than 35 years (OR 4.2,  $p < 0.001$ ) and if BMI was under 26 kg/m<sup>2</sup> (OR 1.9,  $p = 0.029$ ). Patients were less likely to undergo primary repair if a lateral meniscus tear was present (OR 0.5,  $p = 0.008$ ). Furthermore, per year of surgical experience patients were 1.4 times more likely to undergo primary repair. Finally, skiing injury, football injury and gender were no predictors for the possibility of primary repair (Table 4).

**Table 4.** Multivariate binary logistic analysis of variables predicting eligibility for primary ACL repair

Variables	Variables (0 vs. 1)	OR (LB – UB 95% CI)	P-value
Age (years)	<35 vs. ≥35	<b>4.2 (2.4 – 7.5)</b>	<b>&lt;0.001</b>
Delay (days)	>28 vs. ≤28	<b>3.3 (1.9 – 5.7)</b>	<b>&lt;0.001</b>
Lateral meniscus injury	No vs. yes	<b>0.5 (0.3 – 0.8)</b>	<b>0.008</b>
BMI (kg/m <sup>2</sup> )	>26 vs. ≤26	<b>1.9 (1.1 – 3.3)</b>	<b>0.029</b>
Learning curve	Per year experience	<b>1.4 (1.2 – 1.6)</b>	<b>&lt;0.001</b>
Gender	Male vs. female	0.8 (0.4 – 1.3)	0.340
Skiing	No vs. yes	1.3 (0.6 – 2.7)	0.491
Football/rugby	No vs. yes	1.2 (0.5 – 2.8)	0.734

BMI indicates body mass index; OR, odds ratio; LB – UB 95% CI, lower bound – upper bound 95% confidence interval

$R^2 = 0.340$ ,  $p < 0.001$

## Discussion

The goal of this retrospective case-control study was to assess predictive factors of the eligibility of arthroscopic primary repair of proximal ACL tears. In this cohort, 43.8% of all tears were found to have proximal tears with sufficient tissue quality that were eligible for primary ACL repair and were repaired. Multivariate regression analysis showed that patients older than 35 years and patients with a BMI under 26 had a higher chance of undergoing repair, and that operation within 4 weeks of injury was independently correlated with a higher likelihood of repair.

In this cohort of patients with a mean age of 28 years, it was noted that 44% of patients had tears that were eligible for primary repair (i.e. they had a proximal tear with sufficient length for reattachment and sufficient tissue quality to withhold sutures). This percentage seems high when comparing these findings with studies reporting the incidence of repairable proximal ACL tears ranging from 7.6 to 11.4%.<sup>1,2,4,51</sup> However, these studies have all reported the incidence of repairable tears at the start of their surgical treatment. Similar to the current cohort of the senior author, there has been a significant learning curve (OR 1.4 per year of experience, equivalent to an OR of 28.9 over 10 years of experience) which can explain these differences. In the early years of this current cohort, approximately 8% of ACL tears were repaired by the senior author while this was approximately 40 – 50% in the latest years. Recent studies have shown that approximately 43% of all acute ACL tears are located in the proximal quarter on MRI<sup>55,56</sup> and that most of these tears are ultimately repairable intraoperatively<sup>57</sup>, but it is likely that the surgical experience of the senior author have resulted in a higher percentage of repairable tears at the end of the study period.

One of the significant predictors for eligibility for primary repair was older age, and specifically above 35 years of age. When reviewing the literature, similar findings can be noted in various studies on this topic. In their aforementioned ACL tear location study, Van der List et al. similarly noted that patients above 35 years of age had a significant higher incidence of proximal avulsion type tears on MRI (23%) when compared to patients under 35 years of age (8%).<sup>55</sup> Furthermore, several clinical studies reported mean age of primary repair patients to be ranging from 32 to 43 years of age,<sup>2-4</sup> which is higher than the average age in ACL reconstruction patients.<sup>26</sup> These studies show that there is a higher likelihood of proximal tears in older patients, and that there is also a higher likelihood of primary repair of these proximal tears in older patients. This can be valuable information, as ACL reconstruction can be an invasive procedure in these (often) lower demand patients and has a high risk of osteoarthritis in these older patients.<sup>28,29,58</sup>

Data in this study also showed a significantly higher likelihood of primary repair if surgery was performed within 4 weeks of injury (OR 3.3). Historical studies have shown that long delay between injury and surgery can cause retraction and scarring of the ligament, which can lead to suboptimal tissue quality and insufficient tissue length for reattachment to the femoral wall.<sup>59-62</sup> Although several studies have advocated for early repair and have given general



recommendations, such as performing repair within a few weeks of surgery, this is (to our knowledge) the first study assessing a cutoff value for the likelihood for primary repair. Generally, it is believed that performed ACL surgery within few weeks would increase the risk of arthrofibrosis, but recent studies have shown that the risk of arthrofibrosis is low in acute surgery if patients have good range of motion preoperatively<sup>63-65</sup>, and some studies have even suggested that the outcomes of acute reconstruction are better than delayed reconstruction.<sup>64</sup> Based on these findings, we recommend performed ACL surgery within 1 and 4 weeks following injury in order to have the highest likelihood of primary repair while decreasing the risk of stiffness (by not performing surgery in the first week and only when full ROM is present) in case primary repair was not possible.

It was noted in this study that there was an increased likelihood of primary repair in patients with BMI <26 when compared to patients with higher BMI. It is currently unclear why patients with lower BMI had more proximal tears in this study, and when reviewing the literature on primary repair and repair with dynamic intraligamentary stabilization, nothing is mentioned on the role of BMI on the eligibility of primary repair. Future prospective will be needed to clarify why patients with lower BMI have more proximal tears and/or better tissue quality.

It should also be mentioned that the range of delay in the repair group was 3 days to 15 years, which is interesting as it is generally recommended to perform primary early to prevent retraction and scarring of the ligament. Some authors have reported that 14 – 73% of patients with chronic tears (>3-6 months delay) had a reattachment of the ACL to the PCL.<sup>66-69</sup> With this reattachment, the length and tissue quality of the ACL are preserved, and in these chronic cases, the ACL can be dissected off the PCL and can be repaired.<sup>70</sup> Although these chronic cases were rare (median delay of repair from injury to surgery was 1 month), this shows that primary repair is possible in these chronic cases.

It was hypothesized that a higher likelihood of primary repair would be noted in patients with skiing injury when compared to high-energy football or rugby injuries. This was based on the many historical studies reporting on proximal tears in skiing injury mechanism<sup>19,71-74</sup>, and one study showing that the incidence of proximal tears in skiing population was 80%<sup>75</sup> while the estimated incidence of proximal tears is 42% in the general population in a recent MRI study.<sup>55</sup> The multivariate analyses in this current study did not find any role of sports injury mechanism on the likelihood of repairable proximal tears. Furthermore, no significant correlation between contact vs. non-contact injury and the possibility for primary repair were noted in this study, and therefore this hypothesis was rejected. It might be possible that the observation of higher likelihood of primary repair in skiers was confounded by the fact that these patients often have a higher age (and perhaps lower BMI) when compared to football/rugby patients, which was indeed shown in the multivariate regression analysis. No data could be collected on the mechanism of injury (e.g. hyperextension injury, valgus injury etc.) and it would be interesting to assess the role of the mechanism of injury on the tear

location and eligibility of primary repair in future studies. A different injury mechanism might perhaps also explain the lower incidence of lateral meniscus tears in the repair group.

Limitations were present in this study. First of all, this is a single surgeon case series who is experienced in ACL preservation surgery and future studies are needed to assess the external validation of these findings. Secondly, this is a retrospective study and the exact cause of delay from injury to surgery was not known, and a potential selection bias could therefore be present in this cohort with patients with proximal tears potentially undergoing surgery earlier than reconstruction surgery. However, since the senior author always attempted to repair the ligament regardless of delay, patient age or suggested tear location on MRI, the regression analysis is in our opinion still representative. Thirdly, there is a risk for selection bias in this study as some patients come to the clinic of the senior author for primary ACL repair, and it is possible that people with proximal tears are more often referred to the clinic than patients with midsubstance tears, and this might have influenced the incidence of repairable tears. Fourthly, and perhaps most importantly, only the eligibility for repair and no correlation with outcomes were assessed in this study, and no correlation has been made with failure rates or functional outcomes. Future studies are needed to assess the correlation between age, BMI, delay and other variables with the failure rates and functional outcomes of primary repair.

## **Conclusion**

This retrospective case-control study of 361 patients showed that 44% of all patients were intra-operatively deemed eligible for and underwent arthroscopic primary ACL repair. Independent predictors for the possibility of primary ACL repair were age above 35 years, BMI under 26, while presence of a lateral meniscus tear decreased the likelihood of repair. Furthermore, patients had a higher likelihood of primary repair if surgery was performed within 4 weeks of injury, and a significant learning curve for the eligibility of primary repair was noted. Future studies are needed to correlate these predictors with the outcomes of arthroscopic primary repair of proximal ACL tears.

## **Conflict of Interest**

Author J.P.L. and author G.S.D are a paid consultant for Arthrex (Arthrex, Naples, FL, USA). Author A.J., author G.M.M.J.K. and author A.N. have no conflict of interest.

## References

1. DiFelice GS, Villegas C, Taylor SA. Anterior cruciate ligament preservation: Early results of a novel arthroscopic technique for suture anchor primary anterior cruciate ligament repair. *Arthroscopy*. 2015;31(11):2162-2171.
2. Achtnich A, Herbst E, Forkel P, Metzloff S, Sprenker F, Imhoff AB, Petersen W. Acute proximal anterior cruciate ligament tears: Outcomes after arthroscopic suture anchor repair versus anatomic single-bundle reconstruction. *Arthroscopy*. 2016 Dec;32(12):2562-2569.
3. Hoffmann C, Friederichs J, von Ruden C, Schaller C, Buhren V, Moessmer C. Primary single suture anchor re-fixation of anterior cruciate ligament proximal avulsion tears leads to good functional mid-term results: A preliminary study in 12 patients. *J Orthop Surg Res*. 2017 Nov 13;12(1):171.
4. DiFelice GS, van der List JP. Clinical outcomes of arthroscopic primary repair of proximal anterior cruciate ligament tears are maintained at midterm follow-up. *Arthroscopy*. 2018;34(4):1085-1093.
5. Heusdens CHW, Hopper GP, Dossche L, Roelant E, Mackay GM. Anterior cruciate ligament repair with independent suture tape reinforcement: A case series with 2-year follow-up. *Knee Surgery, Sports Traumatology, Arthroscopy*. 2018 October 31.
6. Mukhopadhyay R, Shah N, Vakta R, Bhatt J. Acl femoral avulsion repair using suture pull-out technique: A case series of thirteen patients. *Chin J Traumatol*. 2018.
7. Feagin JA, Abbott HG, Rokous JR. The isolated tear of the anterior cruciate ligament. *J Bone Joint Surg Am*. 1972;54(6):1340-1341.
8. Cabitza P, Colombo A, Verdoia C. Follow-up of results obtained with o'donoghue's technique in the repair of recent lesions of the anterior cruciate ligament. *Minerva Ortop*. 1978;29(12):579-583.
9. Nixon JE. Acute injuries of the anterior cruciate ligament of the knee: Primary repair. *Bull N Y Acad Med*. 1980 Jun;56(5):483-487.
10. Marshall JL, Warren RF, Wickiewicz TL. Primary surgical treatment of anterior cruciate ligament lesions. *Am J Sports Med*. 1982;10(2):103-107.
11. Warren RF. Primary repair of the anterior cruciate ligament. *Clin Orthop Relat Res*. 1983 Jan-Feb(172):65-70.
12. Maccacci M, Spinelli M, Chiellini F, Buccolieri V. Notes on 53 cases of immediate suture of acute lesions of the anterior cruciate ligament. *Ital J Orthop Traumatol*. 1985;7(2):69-79.
13. Sherman MF, Bonamo JR. Primary repair of the anterior cruciate ligament. *Clin Sports Med*. 1988;7(4):739-750.
14. Feagin JA, Jr., Curl WW. Isolated tear of the anterior cruciate ligament: 5-year follow-up study. *Am J Sports Med*. 1976;4(3):95-100.
15. Odensten M, Lysholm J, Gillquist J. Suture of fresh ruptures of the anterior cruciate ligament. A 5-year follow-up. *Acta Orthop Scand*. 1984;55(3):270-272.
16. Engebretsen L, Benum P, Sundalsvoll S. Primary suture of the anterior cruciate ligament a 6-year follow-up of 74 cases. *Acta Orthop Scand*. 1989;60(5):561-564.
17. Jonsson T, Peterson L, Renstrom P. Anterior cruciate ligament repair with and without augmentation. A prospective 7-year study of 51 patients. *Acta Orthop Scand*. 1990;61(6):562-566.
18. Kaplan N, Wickiewicz TL, Warren RF. Primary surgical treatment of anterior cruciate ligament ruptures. A long-term follow-up study. *Am J Sports Med*. 1990 Jul-Aug;18(4):354-358.
19. Sherman MF, Lieber L, Bonamo JR, Podesta L, Reiter I. The long-term followup of primary anterior cruciate ligament repair. Defining a rationale for augmentation. *Am J Sports Med*. 1991;19(3):243-255.
20. van der List JP, DiFelice GS. Primary repair of the anterior cruciate ligament: A paradigm shift. *Surgeon*. 2017 Jun;15(3):161-168.
21. Li S, Chen Y, Lin Z, Cui W, Zhao J, Su W. A systematic review of randomized controlled clinical trials comparing hamstring autografts versus bone-patellar tendon-bone autografts for the reconstruction of the anterior cruciate ligament. *Arch Orthop Trauma Surg*. 2012 Sep;132(9):1287-1297.
22. Li S, Su W, Zhao J, Xu Y, Bo Z, Ding X, Wei Q. A meta-analysis of hamstring autografts versus bone-patellar tendon-bone autografts for reconstruction of the anterior cruciate ligament. *Knee*. 2011 Oct;18(5):287-293.

23. Xie X, Liu X, Chen Z, Yu Y, Peng S, Li Q. A meta-analysis of bone-patellar tendon-bone autograft versus four-strand hamstring tendon autograft for anterior cruciate ligament reconstruction. *Knee*. 2015 Mar;22(2):100-110.
24. Yunes M, Richmond JC, Engels EA, Pinczewski LA. Patellar versus hamstring tendons in anterior cruciate ligament reconstruction: A meta-analysis. *Arthroscopy*. 2001 Mar;17(3):248-257.
25. Wang HD, Wang FS, Gao SJ, Zhang YZ. Remnant preservation technique versus standard technique for anterior cruciate ligament reconstruction: A meta-analysis of randomized controlled trials. *J Orthop Surg Res*. 2018 Sep 12;13(1):231.
26. Ardern CL, Taylor NF, Feller JA, Webster KE. Fifty-five per cent return to competitive sport following anterior cruciate ligament reconstruction surgery: An updated systematic review and meta-analysis including aspects of physical functioning and contextual factors. *Br J Sports Med*. 2014 Nov;48(21):1543-1552.
27. Brophy RH, Schmitz L, Wright RW, Dunn WR, Parker RD, Andrich JT, McCarty EC, Spindler KP. Return to play and future acl injury risk after acl reconstruction in soccer athletes from the multicenter orthopaedic outcomes network (moon) group. *Am J Sports Med*. 2012 Nov;40(11):2517-2522.
28. Ajuied A, Wong F, Smith C, Norris M, Earnshaw P, Back D, Davies A. Anterior cruciate ligament injury and radiologic progression of knee osteoarthritis: A systematic review and meta-analysis. *Am J Sports Med*. 2014;42(9):2242-2252.
29. von Porat A, Roos EM, Roos H. High prevalence of osteoarthritis 14 years after an anterior cruciate ligament tear in male soccer players: A study of radiographic and patient relevant outcomes. *Ann Rheum Dis*. 2004;63(3):269-273.
30. Yperen DTV, Reijman M, Es EMv, Bierma-Zeinstra SMA, Meuffels DE. Twenty-year follow-up study comparing operative versus nonoperative treatment of anterior cruciate ligament ruptures in high-level athletes. *Am J Sports Med*. 2018;46(5):1129-1136.
31. Allen MM, Pareek A, Krych AJ, Hewett TE, Levy BA, Stuart MJ, Dahm DL. Are female soccer players at an increased risk of second anterior cruciate ligament injury compared with their athletic peers? *Am J Sports Med*. 2016 Oct;44(10):2492-2498.
32. Dekker TJ, Godin JA, Dale KM, Garrett WE, Taylor DC, Riboh JC. Return to sport after pediatric anterior cruciate ligament reconstruction and its effect on subsequent anterior cruciate ligament injury. *J Bone Joint Surg Am*. 2017 Jun 07;99(11):897-904.
33. Webster KE, Feller JA. Exploring the high reinjury rate in younger patients undergoing anterior cruciate ligament reconstruction. *Am J Sports Med*. 2016;44(11):2827-2832.
34. Andriolo L, Filardo G, Kon E, Ricci M, Della Villa F, Della Villa S, Zaffagnini S, Marcacci M. Revision anterior cruciate ligament reconstruction: Clinical outcome and evidence for return to sport. *Knee Surg Sports Traumatol Arthrosc*. 2015 Oct;23(10):2825-2845.
35. Arianjam A, Inacio MCS, Funahashi TT, Maletis GB. Analysis of 2019 patients undergoing revision anterior cruciate ligament reconstruction from a community-based registry. *Am J Sports Med*. 2017 Apr 01:363546517700882.
36. Cheatham SA, Johnson DL. Anticipating problems unique to revision acl surgery. *Sports Medicine and Arthroscopy Review*. 2013;21(2):129-134.
37. Kohl S, Evangelopoulos DS, Schar MO, Bieri K, Muller T, Ahmad SS. Dynamic intraligamentary stabilisation: Initial experience with treatment of acute acl ruptures. *Bone Joint J*. 2016 Jun;98-b(6):793-798.
38. Mackay GM, Blyth MJ, Anthony I, Hopper GP, Ribbans WJ. A review of ligament augmentation with the internalbrace: The surgical principle is described for the lateral ankle ligament and acl repair in particular, and a comprehensive review of other surgical applications and techniques is presented. *Surg Technol Int*. 2015 May;26:239-255.
39. van der List JP, DiFelice GS. Role of tear location on outcomes of open primary repair of the anterior cruciate ligament: A systematic review of historical studies. *Knee*. 2017 Oct;24(5):898-908.
40. van Eck CF, Limpisvasti O, ElAttrache NS. Is there a role for internal bracing and repair of the anterior cruciate ligament? A systematic literature review. *Am J Sports Med*. 2017;46(9):2291-2298.
41. Krismer AM, Gousopoulos L, Kohl S, Ateschrang A, Kohlhof H, Ahmad SS. Factors influencing the success of anterior cruciate ligament repair with dynamic intraligamentary stabilisation. *Knee Surg Sports Traumatol Arthrosc*. 2017;25(12):3923-3928.

42. Toy BJ, Yeasting RA, Morse DE, McCann P. Arterial supply to the human anterior cruciate ligament. *J Athl Train*. 1995 Jun;30(2):149-152.
43. Nguyen DT, Ramwadhoebe TH, van der Hart CP, Blankevoort L, Tak PP, van Dijk CN. Intrinsic healing response of the human anterior cruciate ligament: An histological study of reattached acl remnants. *J Orthop Res*. 2014;32(2):296-301.
44. Murray MM. Current status and potential of primary acl repair. *Clin Sports Med*. 2009 Jan;28(1):51-61.
45. Murray MM, Martin SD, Martin TL, Spector M. Histological changes in the human anterior cruciate ligament after rupture. *J Bone Joint Surg Am*. 2000 Oct;82-A(10):1387-1397.
46. van der List JP, DiFelice GS. Range of motion and complications following primary repair versus reconstruction of the anterior cruciate ligament. *Knee*. 2017 Aug;24(4):798-807.
47. Fleming BC, Carey JL, Spindler KP, Murray MM. Can suture repair of acl transection restore normal anteroposterior laxity of the knee? An ex vivo study. *J Orthop Res*. 2008 Nov;26(11):1500-1505.
48. Murray MM, Fleming BC. Use of a bioactive scaffold to stimulate anterior cruciate ligament healing also minimizes posttraumatic osteoarthritis after surgery. *Am J Sports Med*. 2013 Aug;41(8):1762-1770.
49. Jonkergouw A, van der List JP, DiFelice GS. Arthroscopic primary repair of proximal anterior cruciate ligament tears: With or without additional suture augmentation? *Orthop J Sports Med*. 2018;6(7 (suppl 4)):2325967118S2325960006.
50. Smith JO, Yasen SK, Palmer HC, Lord BR, Britton EM, Wilson AJ. Paediatric acl repair reinforced with temporary internal bracing. *Knee Surg Sports Traumatol Arthrosc*. 2016;24(6):1845-1851.
51. Bigoni M, Gaddi D, Gorla M, Munegato D, Pungitore M, Piatti M, Turati M. Arthroscopic anterior cruciate ligament repair for proximal anterior cruciate ligament tears in skeletally immature patients: Surgical technique and preliminary results. *Knee*. 2017 Jan;24(1):40-48.
52. DiFelice GS, van der List JP. Arthroscopic primary repair of proximal anterior cruciate ligament tears. *Arthrosc Tech*. 2016 Oct;5(5):e1057-e1061.
53. van der List JP, DiFelice GS. Preservation of the anterior cruciate ligament: Surgical techniques. *Am J Orthop (Belle Mead NJ)*. 2016;45(7):E406-414.
54. van der List JP, DiFelice GS. Arthroscopic primary anterior cruciate ligament repair with suture augmentation. *Arthrosc Tech*. 2017 Oct;6(5):e1529-e1534.
55. van der List JP, Mintz DN, DiFelice GS. The location of anterior cruciate ligament tears: A prevalence study using magnetic resonance imaging. *Orthop J Sports Med*. 2017;5(6):2325967117709966.
56. van der List JP, Mintz DN, DiFelice GS. The location of anterior cruciate ligament tears in pediatric and adolescent patients: A magnetic resonance imaging study. *J Pediatr Orthop*. 2017.
57. van der List JP, DiFelice GS. Preoperative magnetic resonance imaging predicts eligibility for arthroscopic primary anterior cruciate ligament repair. *Knee Surg Sports Traumatol Arthrosc*. 2017 July 13;26(2):660-671.
58. Li RT, Lorenz S, Xu Y, Harner CD, Fu FH, Irrgang JJ. Predictors of radiographic knee osteoarthritis after anterior cruciate ligament reconstruction. *Am J Sports Med*. 2011 Dec;39(12):2595-2603.
59. O'Donoghue DH, Rockwood CA, Jr., Frank GR, Jack SC, Kenyon R. Repair of the anterior cruciate ligament in dogs. *J Bone Joint Surg Am*. 1966;48(3):503-519.
60. O'Donoghue DH. An analysis of end results of surgical treatment of major injuries to the ligaments of the knee. *J Bone Joint Surg Am*. 1955;37(1):1-13.
61. O'Donoghue DH. Surgical treatment of fresh injuries to the major ligaments of the knee. *J Bone Joint Surg Am*. 1950;32 A(4):721-738.
62. Magarian EM, Fleming BC, Harrison SL, Mastrangelo AN, Badger GJ, Murray MM. Delay of 2 or 6 weeks adversely affects the functional outcome of augmented primary repair of the porcine anterior cruciate ligament. *Am J Sports Med*. 2010 Dec;38(12):2528-2534.
63. Werner BC, Cancienne JM, Miller MD, Gwathmey FW. Incidence of manipulation under anesthesia or lysis of adhesions after arthroscopic knee surgery. *Am J Sports Med*. 2015 Jul;43(7):1656-1661.
64. Herbst E, Hoser C, Gfoller P, Hepperger C, Abermann E, Neumayer K, Musahl V, Fink C. Impact of surgical timing on the outcome of anterior cruciate ligament reconstruction. *Knee Surg Sports Traumatol Arthrosc*. 2017 Feb;25(2):569-577.

65. Eriksson K, von Essen C, Jonhagen S, Barenius B. No risk of arthrofibrosis after acute anterior cruciate ligament reconstruction. *Knee Surg Sports Traumatol Arthrosc.* 2018 Oct;26(10):2875-2882.
66. Lo IK, de Maat GH, Valk JW, Frank CB. The gross morphology of torn human anterior cruciate ligaments in unstable knees. *Arthroscopy.* 1999;15(3):301-306.
67. Crain EH, Fithian DC, Paxton EW, Luetzow WF. Variation in anterior cruciate ligament scar pattern: Does the scar pattern affect anterior laxity in anterior cruciate ligament-deficient knees? *Arthroscopy.* 2005;21(1):19-24.
68. Fowler PJ, Regan WD. The patient with symptomatic chronic anterior cruciate ligament insufficiency. Results of minimal arthroscopic surgery and rehabilitation. *Am J Sports Med.* 1987 Jul-Aug;15(4):321-325.
69. Vahey TN, Broome DR, Kayes KJ, Shelbourne KD. Acute and chronic tears of the anterior cruciate ligament: Differential features at mr imaging. *Radiology.* 1991;181(1):251-253.
70. van der List JP, DiFelice GS. Successful arthroscopic primary repair of a chronic anterior cruciate ligament tear 11 years following injury. *Hss j.* 2017 Feb;13(1):90-95.
71. Higgins RW, Steadman JR. Anterior cruciate ligament repairs in world class skiers. *Am J Sports Med.* 1987;15(5):439-447.
72. Speer KP, Warren RF, Wickiewicz TL, Horowitz L, Henderson L. Observations on the injury mechanism of anterior cruciate ligament tears in skiers. *Am J Sports Med.* 1995 Jan-Feb;23(1):77-81.
73. Ho CP, Marks PH, Steadman JR. Mr imaging of knee anterior cruciate ligament and associated injuries in skiers. *Magn Reson Imaging Clin N Am.* 1999 Feb;7(1):117-130.
74. Hetsroni I, Delos D, Fives G, Boyle BW, Lillemoe K, Marx RG. Nonoperative treatment for anterior cruciate ligament injury in recreational alpine skiers. *Knee Surg Sports Traumatol Arthrosc.* 2013 Aug;21(8):1910-1914.
75. Weaver JK, Derkash RS, Freeman JR, Kirk RE, Oden RR, Matyas J. Primary knee ligament repair--revisited. *Clin Orthop Relat Res.* 1985 (199):185-191.

# Chapter 8

## **Range of motion and complications following primary repair versus reconstruction of the anterior cruciate ligament**

Jelle P. van der List

Gregory S. DiFelice

*Knee. 2017 Aug;24(4):798-807.*

## **Abstract**

### **Introduction**

Recently, there has been a resurgence of interest in primary anterior cruciate ligament (ACL) repair. The procedure is less invasive than ACL reconstruction, yet studies assessing early postoperative course are lacking. Goal therefore was to assess postoperative range of motion (ROM), complications and operative times following primary repair and compare this to the gold standard of reconstruction.

### **Methods**

A retrospective study was performed for which 52 repair and 90 reconstruction patients could be included. Patients were examined at one week and one, three and six months. Rehabilitation protocol consisted of early ROM and was equal for both groups. Outcomes were compared using independent t-tests and chi-square tests, and reported in mean  $\pm$  standard deviation.

### **Results**

Repair had more ROM than reconstruction patients at one week ( $89^\circ \pm 18$  vs.  $61^\circ \pm 21$ ,  $p < 0.01$ ) and one month ( $125^\circ \pm 14$  vs.  $116^\circ \pm 18$ ,  $p < 0.01$ ) postoperatively. Fewer repair patients had  $90^\circ$  ROM at one week (23% vs. 84%,  $p < 0.01$ ), and more repair patients had full ROM at one month (57% vs. 30%,  $p < 0.01$ ). Treatment of meniscal lesions, but not chondral lesions, influenced ROM. Trends towards fewer complications (2% vs. 9%,  $p = 0.19$ ) and infections (0% vs. 6%,  $p = 0.20$ ) were noted following primary repair, and the procedure was significantly shorter.

### **Conclusions**

Following primary repair, patients had better ROM, and trends towards fewer complications than reconstruction. Primary repair is a safe, brief procedure with early ROM and low complication rates.



## Introduction

The first surgical treatment of an anterior cruciate ligament (ACL) injury was performed by Mayo Robson in 1895 using open primary repair.<sup>1</sup> Over the following decades, Ivar Palmer<sup>2,3</sup> and Don O'Donoghue<sup>4,5</sup> further popularized the treatment of open primary ACL repair, and this technique became the most commonly used treatment in the 1970s and 1980s.<sup>6-11</sup> However, because no appropriate patient selection was applied, surgery consisted of an invasive arthrotomy and postoperative management consisted of joint immobilization with a cast for 5 or 6 weeks, problems such as decreased range of motion (ROM), intraoperative and postoperative complications, and deterioration of outcomes at mid-term follow-up were frequently reported.<sup>11-15</sup> Ultimately, open primary repair was abandoned and ACL reconstruction became the gold standard.<sup>16</sup>

In recent years, a resurgence of interest has been noted regarding primary repair. With the modern-day understanding of only repairing patients with proximal (type I) tears<sup>14,17-19</sup> (using a recently modified Sherman classification<sup>20,21</sup>), utilizing rehabilitation protocols that stress early ROM,<sup>16,19,22</sup> and with the modern advancements of arthroscopic technology<sup>23,24</sup>, better results of primary repair could be expected. Indeed, DiFelice et al. were the first to report a case series of 11 patients treated with arthroscopic primary ACL repair of proximal type I tears using suture anchors.<sup>25</sup> They reported excellent outcomes at a mean short-term follow-up of 3.5 years. More recently, Achtnich et al. compared arthroscopic primary repair to the gold standard of single-bundle ACL reconstruction in patients with proximal type I tears, and found equivalent outcomes regarding stability, and patient reported outcomes.<sup>26</sup> More recently, Mackay et al. reported on the addition of an internal brace to the primary repair in order to protect healing of the repaired ligament during early rehabilitation.<sup>27</sup>

Arthroscopic primary ACL repair is a conservative and minimally invasive approach when compared to reconstructive surgery, as no tunnels are drilled, no grafts are harvested and revision surgery, when necessary may be less complicated.<sup>17</sup> Furthermore, the native nerve-endings, blood supply and ligament are preserved, and thus proprioception is maintained.<sup>28</sup> With the less invasive nature of this surgery, one could expect a more benign postoperative course with regard to ROM and complications when compared to ACL reconstruction, but studies assessing this are lacking.

Therefore, we aimed to assess the intraoperative and early postoperative course of arthroscopic primary ACL repair patients and compare this to the gold standard of single-bundle ACL reconstruction. The hypotheses were that (I) patients undergoing primary repair had earlier return of ROM and (II) less complications when compared to reconstruction surgery, and (III) primary repair was a shorter surgical procedure than reconstruction surgery.

## Methods

### Patient selection

Following Institutional Review Board approval (Hospital for Special Surgery, #16006), a retrospective search was performed in the database of the senior author (G.S.D.) for patients who underwent arthroscopic primary ACL repair and ACL reconstruction between April 2009 and April 2016. In the practice of the senior author, patients with type I ACL tears are treated with arthroscopic primary repair, while patients with non-repairable tears undergo ACL reconstruction. A total of 66 patients underwent primary repair and 109 that patients underwent ACL reconstruction and these were included in the study. Patients in the repair group were excluded because they had multiligamentous injuries ( $n = 6$ ), distal avulsion tears ( $n = 4$ ), or simultaneously conservatively treated medial collateral ligament (MCL) injuries ( $n = 4$ ), since the focus of the study was to assess primary repair of isolated proximal ACL tears, and since MCL injuries influence postoperative ROM.<sup>29,30</sup> Patients in the reconstruction group were excluded because they had multiligamentous injuries ( $n = 17$ ), or simultaneously conservatively treated MCL injuries ( $n = 2$ ), since the focus of the study was to assess reconstruction of isolated ACL injuries, and since MCL injuries influence postoperative ROM.<sup>29,30</sup> No patients were excluded for meniscus tears or chondral lesions. This resulted in a total of 52 patients that underwent primary repair and 90 patients that underwent ACL reconstruction without any other ligamentous injuries.

### Surgical techniques

Preoperatively, the senior author discussed with all patients that they would undergo primary repair when a proximal (type I) tear was present, and that they would undergo single-bundle ACL reconstruction when the tear was non-repairable. The senior author performed all surgeries. All patients had full ROM (i.e. 0 to  $\geq 130^\circ$ ) preoperatively. Arthroscopic primary ACL repair was performed with suture anchor fixation of the anteromedial and posterolateral bundle as has been previously described.<sup>23,24</sup> An InternalBrace (Arthrex, Naples, FL, USA) was added to the repair in 52% of patients since the availability of this internal brace, as this was thought to protect the ligament with early ROM.<sup>19,27,31</sup> Single-bundle anatomic ACL reconstruction with anteromedial drilling of the femoral tunnel was performed in all patients without repairable tears using either soft tissue allograft tissue (55%) or autograft tissue with bone-patellar tendon-bone (BPTB) (43%) or hamstring autografts (3%). BPTB was fixed using interference screws, while soft tissue grafts were fixed proximally with a button or interference screw, and distally with an interference screw. The specific drilling technique (retrograde versus antegrade) differed throughout the study period.

## **Rehabilitation protocol**

The rehabilitation protocol was the same for patients undergoing primary repair (with and without internal brace) and reconstruction with an early ROM protocol. A brace is worn in the first four weeks with weight bearing as tolerated. The brace is locked in extension until volitional quadriceps control has returned and is then unlocked for ambulation. Swelling control and ROM exercises are initiated in the first few days after surgery in a controlled fashion. Formal physical therapy is started at four weeks. After four to six weeks, the patient is advanced to gentle strengthening and a standard ACL rehabilitation protocol. Return to sports is generally based upon sport specific assessment between 6 and 9 months postoperatively.

## **Data collection**

As part of the standard postoperative protocol, all patients presented in the clinic at one week, one month, three months and six months postoperatively. Data collected were information on operative procedures, age, gender, BMI, side of injury, time of injury to surgery, other ligamentous injuries, status of meniscus and meniscus procedures, time of surgery (defined as time from incision to closure), status of cartilage and chondroplasty procedures, passive ROM, complications, reoperations and revisions. ROM was measured with a goniometer and defined as the arc of ROM (flexion - extension) and was categorized as limited ( $<90^\circ$ ), mildly limited ( $90 - 130^\circ$ ) and full ROM ( $\geq 130^\circ$ ). Additionally, extension deficits were reported separately.

## **Statistical analysis**

Statistical analysis was performed using SPSS Version 21 (SPSS Inc., Armonk, NY, USA). Independent t-tests were used to compare continuous data, whereas chi-square tests and Fisher's exact tests (in case one of the cells was less than 5) were used to compare nominal data. Microsoft Excel 2011 (Microsoft Corp., Redmond, WA, USA) was used to plot ROM graphs with standard deviation (SD) as the error bars. All tests were two-sided and a difference of  $p < 0.05$  was considered statistically significant.

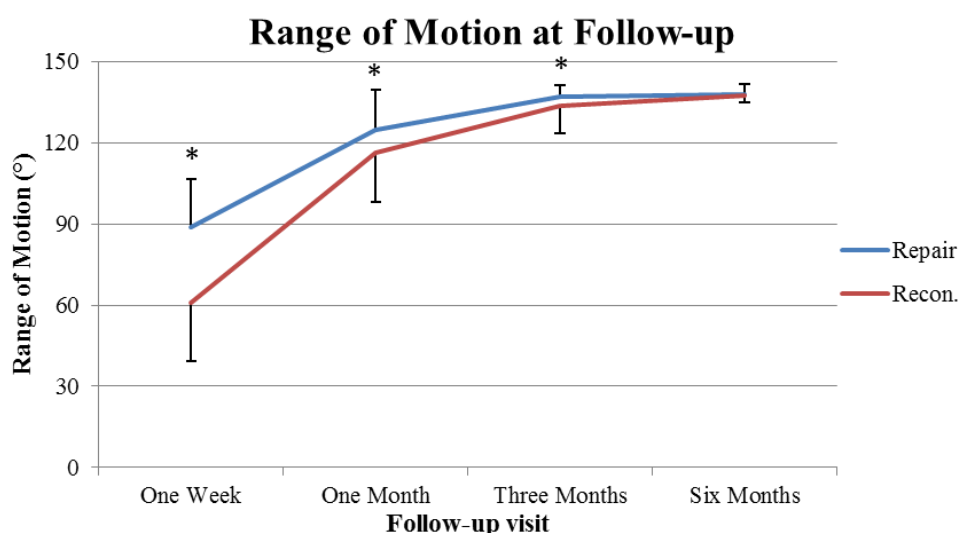
## Results

### Baseline characteristics

Mean age in the primary repair group was higher ( $33 \pm 11$  years, range 14 – 57) than in the reconstruction group ( $29 \pm 9$  years, range 14 – 51) ( $p = 0.03$ ). Mean time from injury to surgery was shorter in the primary repair group ( $48 \pm 39$  days, range 5 – 155) than in the reconstruction group ( $412 \pm 1037$  days, range 3 – 5479) ( $p = 0.02$ ), although three patients in the repair group had chronic ACL tears with a range from injury to surgery of 4 – 11 years. No significant differences between both groups were noted in gender, side, BMI, or how many days postoperatively patients came in for visits (Table 1). Patients in the reconstruction group had more often meniscal injuries when compared to the repair group ( $p < 0.01$ ). No differences in cartilage damage were noted between both groups ( $p = 0.27$ ) (Table 1).

### Range of motion

Patients who underwent primary repair had significantly more ROM when compared to patients who underwent reconstruction at one week ( $89^\circ \pm 18$  vs.  $61^\circ \pm 21$ ,  $p < 0.01$ ) and one month postoperatively ( $125^\circ \pm 14$  vs.  $116^\circ \pm 18$ ,  $p < 0.01$ ). This was also seen at three months postoperatively ( $137^\circ \pm 4$  vs.  $134^\circ \pm 10$ ,  $p = 0.03$ ), but this was not clinically relevant. At six months follow-up, all patients had full ROM (Table 2, Figure 1). Furthermore, fewer repair patients had limited ROM when compared to reconstruction patients at one week (23% vs. 84%,  $p < 0.01$ ), and more repair patients had full ROM at one month (57% vs. 30%,  $p < 0.01$ ) (Table 2 and Figure 2). No differences in extension deficits were noted between both groups at all visits (all  $p > 0.99$ ) (Table 2).



**Figure 1.** Graph shows mean range of motion in patients that underwent repair versus reconstruction at postoperative visits. The error bars represent standard deviation. Asterix (\*) indicates significant differences at one week, one month and three month visits.

**Table 1.** Patient demographics of patients undergoing primary repair or reconstruction of the anterior cruciate ligament

	Primary Repair		Reconstruction		T-test or $\chi^2$ *
	n = 52		n = 90		
	Mean $\pm$ SD	Range	Mean $\pm$ SD	Range	p-value
Age (years)	33 $\pm$ 11	14 – 57	29 $\pm$ 9	14 – 51	0.03
BMI (kg/m <sup>2</sup> )	25 $\pm$ 4	19 – 35	26 $\pm$ 5	18 – 47	0.11
Delay (days injury – surgery)	48 $\pm$ 39**	5 – 155	412 $\pm$ 1037	3 – 5479	0.02
Gender (M:F)	30:22		65:35		0.08
Side (R:L)	29:23		42:48		0.30
First visit (days postop.)	5 $\pm$ 2	2 – 11	5 $\pm$ 2	2 – 10	0.58
Second visit (days postop.)	35 $\pm$ 7	20 – 46	34 $\pm$ 7	20 – 45	0.19
Third visit (days postop.)	93 $\pm$ 24	64 – 129	89 $\pm$ 21	59 – 128	0.35
Fourth visit (days postop.)	190 $\pm$ 38	143 – 224	188 $\pm$ 38	148 – 219	0.81
<b>Concomitant injuries</b>	<b>n (%)</b>		<b>n (%)</b>		<b>p-value</b>
Meniscus					
No meniscal tears	35 (67%)		37 (41%)		<0.01
Meniscal Repair	5 (10%)		19 (21%)		0.08
Meniscectomy	12 (23%)		34 (38%)		0.07
Cartilage					
No damage	40 (77%)		73 (81%)		0.27
TF chondroplasty	5 (10%)		13 (14%)		0.40
Pat. chondroplasty	6 (12%)		2 (2%)		0.02
TF + pat. chondroplasty	1 (2%)		2 (2%)		0.90

BMI indicates body mass index; M, males; F, females; R, right; L, left; n, number of patients; TF, tibiofemoral; pat., patellar.

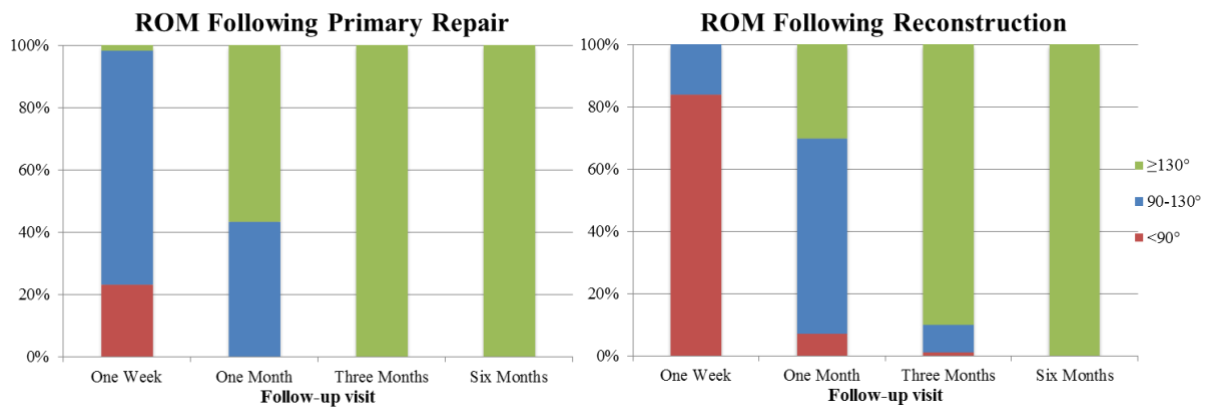
\* Independent t-test was used to compare repair vs. reconstruction with continuous data and chi-square test ( $\chi^2$ ) was used for nominal or categorical data (i.e. groups)

\*\* Three patients had a chronic ACL tear but were excluded for the calculation of delay, as they were outliers. These three patients underwent repair 4 – 11 years following injury

**Table 2.** Range of motion, range of motion groups (very limited vs. limited vs. full range of motion), and extension deficits in patients treated with primary repair and reconstruction

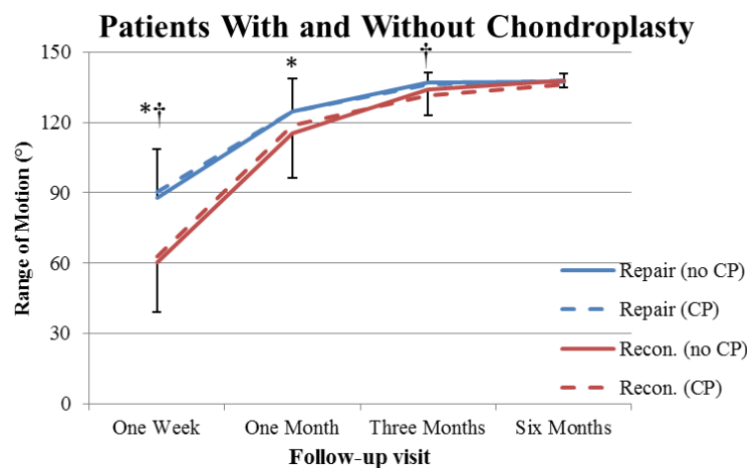
	<b>Primary Repair</b>	<b>Reconstruction</b>	<b>Independent t-test</b>
	<b>Mean ± SD</b>	<b>Mean ± SD</b>	<b>p-value</b>
<b>One week</b>	89° ± 18°	61° ± 21°	<0.01
<b>One month</b>	125° ± 14°	116° ± 18°	<0.01
<b>Three months</b>	137° ± 4°	134° ± 10°	0.03
<b>Six months</b>	138° ± 3°	128° ± 3°	0.91
	<b>Primary Repair</b>	<b>Reconstruction</b>	<b>Chi-square test</b>
	<b>&lt;90°</b>	<b>&lt;90°</b>	<b>&lt;90°</b>
<b>One week</b>	23%	84%	<0.01
<b>One month</b>	0%	7%	0.11
<b>Three months</b>	0%	1%	>0.99
<b>Six months</b>	0%	0%	>0.99
	<b>90 – 130°</b>	<b>90 – 130°</b>	<b>≥130°</b>
<b>One week</b>	75%	16%	<0.01
<b>One month</b>	43%	63%	0.11
<b>Three months</b>	0%	9%	>0.99
<b>Six months</b>	0%	0%	>0.99
	<b>Primary Repair</b>	<b>Reconstruction</b>	<b>Chi-square test</b>
<b>Extension deficit</b>	<b>&lt;5°</b>	<b>&lt;5°</b>	<b>&lt;5°</b>
<b>One week</b>	0%	0%	>0.99
<b>One month</b>	4%	4%	>0.99
<b>Three months</b>	2%	1%	>0.99
<b>Six months</b>	2%	2%	>0.99
	<b>5 – 10°</b>	<b>5 – 10°</b>	<b>&gt;10°</b>
<b>One week</b>	0%	0%	>0.99
<b>One month</b>	4%	3%	>0.99
<b>Three months</b>	0%	1%	>0.99
<b>Six months</b>	0%	0%	>0.99

SD indicates standard deviation.



**Figure 2.** Graph shows the distribution of the range of motion of patients following primary repair (on the left) and reconstruction (on the right) at all visits, stratified by limited (<90°), mildly limited (90 – 130°) and full (≥130°) range of motion. Repair patients had significantly less often limited ROM at one week and significantly more often full ROM at one month.

In patients without meniscus injury, it was noted that primary repair patients had more ROM at one week ( $88^\circ \pm 16$  vs.  $57^\circ \pm 21$ ,  $p < 0.01$ ) compared to reconstruction patients, but not at other visits. In patients with meniscectomy, patients with primary repair had more ROM at one week ( $93^\circ \pm 23$  vs.  $60^\circ \pm 23$ ,  $p < 0.01$ ) and at one month ( $129^\circ \pm 10$  vs.  $115^\circ \pm 19$ ,  $p = 0.02$ ) compared to reconstruction patients. Similarly, repair patients with meniscal repair had more ROM at one week and one month than reconstruction patients but this was not significant due to the small number of patients in the primary repair group ( $n = 5$ ) (Table 3). The presence of cartilage injuries and subsequent chondroplasty did not influence ROM in both groups (Table 3, Figure 3).



**Figure 3.** Graph shows mean range of motion in patients that underwent repair versus reconstruction with and without chondroplasty at all visits. The error bars represent standard deviation. Asterisk (\*) indicates statistical significant difference between repair and reconstruction without chondroplasty, and dagger (†) indicates statistical significant difference between repair and reconstruction in patients with chondroplasty. CP indicates chondroplasty.

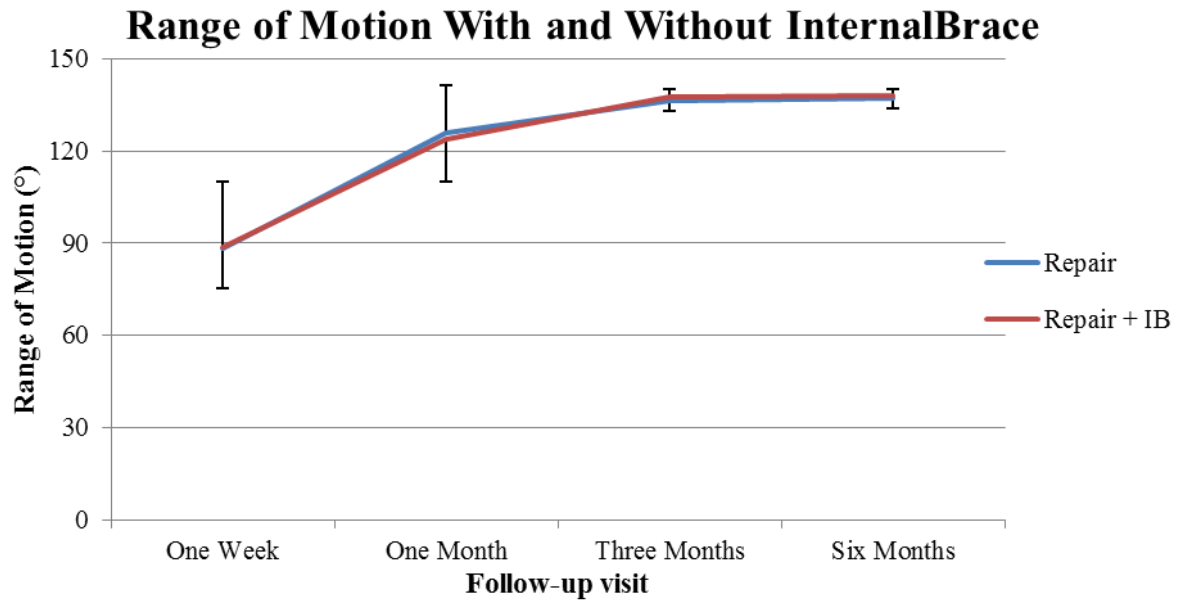
**Table 3.** Range of motion (mean  $\pm$  SD) of primary repair vs. reconstruction in different meniscus/cartilage status

	Primary Repair	Reconstruction	T-test
<b>Patients without meniscus injury</b>			
One week	88° $\pm$ 16°	57° $\pm$ 21°	<0.01
One month	124° $\pm$ 16°	121° $\pm$ 17°	0.54
Three months	137° $\pm$ 4°	133° $\pm$ 14°	0.10
Six months	138° $\pm$ 4°	138° $\pm$ 3°	0.86
<b>Patients with meniscectomy</b>			
One week	93° $\pm$ 23°	60° $\pm$ 23°	<0.01
One month	129° $\pm$ 10°	115° $\pm$ 19°	0.02
Three months	136° $\pm$ 4°	133° $\pm$ 7°	0.23
Six months	137° $\pm$ 3°	137° $\pm$ 3°	0.75
<b>Patients with meniscus repair</b>			
One week	82° $\pm$ 21°	69° $\pm$ 19°	0.19
One month	120° $\pm$ 17°	110° $\pm$ 17°	0.23
Three months	136° $\pm$ 3°	135° $\pm$ 4°	0.48
Six months	136° $\pm$ 3°	138° $\pm$ 3°	0.24
<b>Patients without chondroplasty</b>			
One week	88° $\pm$ 21°	60° $\pm$ 21°	<0.01
One month	125° $\pm$ 14°	116° $\pm$ 19°	0.01
Three months	137° $\pm$ 4°	134° $\pm$ 11°	0.11
Six months	137° $\pm$ 3°	138° $\pm$ 3°	0.51
<b>Patients with chondroplasty</b>			
One week	90° $\pm$ 5°	63° $\pm$ 23°	<0.01
One month	125° $\pm$ 16°	119° $\pm$ 14°	0.29
Three months	136° $\pm$ 5°	132° $\pm$ 6°	0.04
Six months	138° $\pm$ 4°	136° $\pm$ 2°	0.12

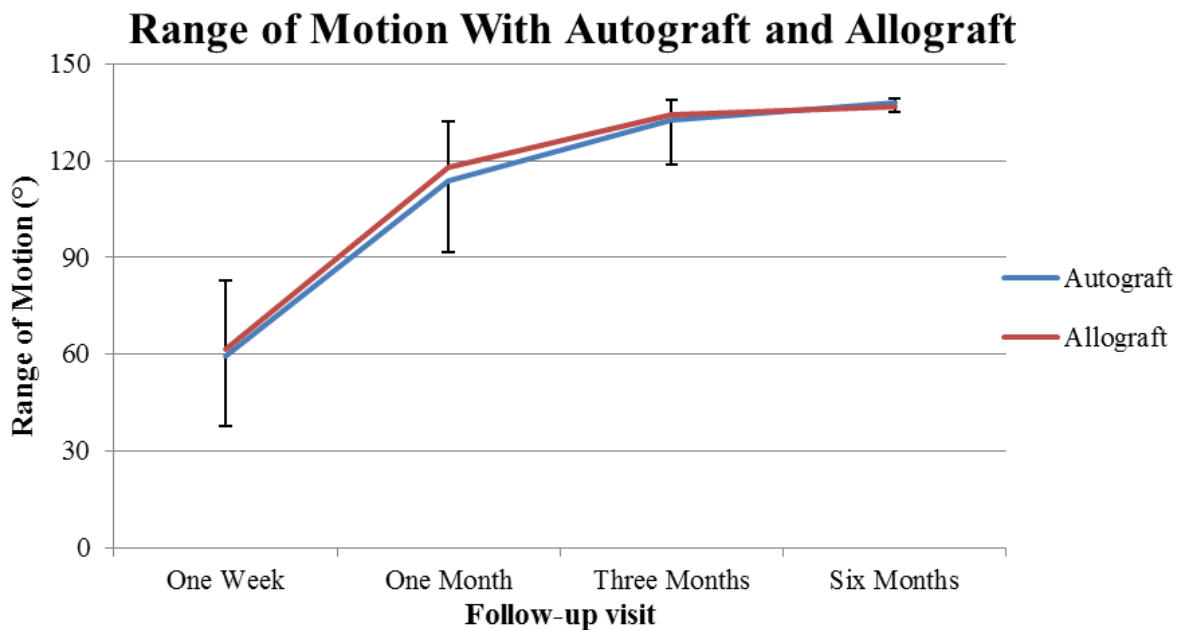
SD indicates standard deviation.



No differences in ROM were noted between patients treated with primary repair and patients treated with primary repair with the addition of an internal brace (Figure 4). Finally, no differences in ROM were noted between reconstruction with autograft and allograft tissue (Figure 5).



**Figure 4.** Graph shows mean range of motion in patients that underwent repair with internal brace versus without internal brace at all visits. The error bars represent standard deviation. Differences were not significant at all visits. IB indicates internal brace.



**Figure 5.** Graph shows mean range of motion in patients that underwent reconstruction with autograft or allograft tissue at different visits. The error bars represent standard deviation. Differences were not significant at all visits.

## Complications

When comparing repair with reconstruction, trends towards fewer complications (2% vs. 9%, respectively,  $p = 0.19$ ) and infections (0% vs. 6%, respectively,  $p = 0.20$ ) were noted (Table 4). In the primary repair group, one reinjury (2%) occurred within six months while descending stairs and one technical operative complication (2%) occurred when the tip of the scorpion device broke off and was lost in the ACL ligament, which was treated conservatively without further problems.

In the reconstruction group, one reinjury (1%) (BPTB autograft) occurred while playing soccer, while he was not cleared for return to sports. One patient (1%) who underwent BPTB autograft reconstruction had a patella fracture during physical therapy, and one patient (1%) with a BPTB autograft had a tibial stress fracture. Both were successfully treated conservatively. One technical complication (1%) of a graft-tunnel mismatch occurred intraoperatively (BPTB autograft).

Two patients (2%) developed septic arthritis at one week (hamstring autograft) and two weeks (BPTB autograft) postoperatively, respectively. One patient (1%) had a stitch abscess (BPTB autograft) and two patients (2%) developed superficial infection at the graft-harvesting site (BPTB autograft) and the incision site (soft tissue allograft), respectively. The first three patients all required reoperation, with one of the patients with a deep infection (1%) requiring revision surgery because the graft was damaged and non-functioning and the patients with superficial infections were successfully treated with oral antibiotics.

## Operation time

The operation time of the repair procedure was  $74 \pm 14$  minutes, and this was faster when compared to repair with internal brace  $95 \pm 15$  minutes ( $p < 0.01$ ), compared to autograft BPTB reconstruction  $129 \pm 32$  minutes ( $p < 0.01$ ), and compared to reconstruction allograft  $103 \pm 20$  minutes ( $p < 0.01$ ). Meniscus treatment did not significantly influence the differences in operation times between the groups (Table 5).

**Table 4.** Complications, reoperations and indicated revisions following primary repair and reconstruction

	<b>Primary Repair</b> <b>n = 52</b>	<b>Reconstruction</b> <b>n = 90</b>	<b>Chi-square</b> <b>test</b>
<b>Reinjury</b>	1 (2%)	1 (1%)	>0.99
<b>Meniscal repair failures</b>	0/5 (0%)	2/19 (11%)	>0.99
<b>Complications</b>	1 (2%)	8 (9%)	0.19
<b>Technical</b>	1 (2%)	1 (1%)	>0.99
<b>Patella fracture</b>	0 (0%)	1 (1%)	>0.99
<b>Tibial stress fracture</b>	0 (0%)	1 (1%)	>0.99
<b>Infections</b>	0 (0%)	5 (6%)	0.20
<b>Deep infection</b>	0 (0%)	2 (2%)	
<b>Stitch abscess</b>	0 (0%)	1 (1%)	
<b>Superficial infection</b>	0 (0%)	2 (2%)	
<b>Total revisions indicated*</b>	1 (2%)	2 (2%)	>0.99
<b>Total reoperations**</b>	0 (0%)	5 (6%)	0.20

N indicates number of patients.

\* Revisions indicated means that the anterior cruciate ligament was not functioning and revision surgery was indicated. One patient with a deep infection had a non-functioning ligament after treatment and underwent revision

\*\* Two patients with meniscus repair failure, two patients with deep infection and one patients with stitch abscess underwent reoperation

**Table 5.** Operation times in minutes of the different procedures

	<b>All patients</b>		<b>Isolated ACL tear</b>		<b>ACL + meniscus*</b>		<b>T-test**</b>
	<b>Mn ± SD</b>	<b>Range</b>	<b>Mn ± SD</b>	<b>Range</b>	<b>Mn ± SD</b>	<b>Range</b>	
<b>Repair</b>	74 ± 14	54 – 98	76 ± 17	54 – 98	72 ± 7	64 – 82	0.63
<b>Repair + internal brace</b>	97 ± 15	76 – 129	98 ± 17	76 – 129	97 ± 11	84 – 115	0.95
<b>T-test</b>	<0.01		0.01		<0.01		
<b>Reconstruction (autograft)</b>	129 ± 32	83 – 210	124 ± 24	84 – 161	133 ± 37	83 – 210	0.42
<b>Reconstruction (allograft)</b>	103 ± 20	64 – 157	99 ± 20	64 – 123	105 ± 21	76 – 157	0.49
<b>T-test</b>	<0.01		0.02		0.01		

Mn indicates mean; SD, standard deviation; ACL, anterior cruciate ligament; IB, internal brace; Recon, reconstruction.

\* Meniscus treatment indicates any meniscus treatment (partial meniscectomy and meniscal repair)

\*\* Independent t-tests compare the operation times between isolated ACL tears and ACL tears with meniscus treatments

## Discussion

The main findings of this study were that patients undergoing primary repair had more ROM in the early phases of rehabilitation, and earlier return to full ROM when compared to patients who underwent reconstruction. Furthermore, trends towards fewer complications and infections were noted following primary repair when compared to reconstruction, and it was noted that the primary repair procedure had significantly shorter operative times than reconstruction surgery.

The first hypothesis of this study was that patients undergoing primary repair would have earlier return of ROM when compared to patients undergoing reconstruction surgery. Data in our study indeed showed that patients undergoing primary repair had approximately 30° more ROM in the first week when compared to reconstruction patients, which can likely be explained by less invasive nature of primary repair surgery. Furthermore, it was noted that after one month patients with primary repair had more ROM and twice as many primary repair patients had full ROM (57%) when compared to reconstruction patients (30%). It was also noted that the differences were significant at three months follow-up, but these differences were not considered clinically relevant (137° vs. 134°). At three months follow-up, however, it was noted that 10% of patients undergoing ACL reconstruction had not achieved full ROM while all patients in the repair group had regained full ROM (Figures 2 and Table 2). At six months follow-up, no differences were noted between both patient groups and all patients had regained full ROM without significant extension deficits. It is likely that the more invasive surgery of ACL reconstruction with the drilling of tunnels and graft harvesting (especially BPTB) play a role in these differences. It should be noted that patients in the reconstruction group were four years younger than patients in the primary repair group but this was not considered clinically relevant.

This is the first study assessing postoperative ROM following arthroscopic primary ACL repair. Comparing these results with studies performing open primary repair in the historical literature is difficult for several reasons. First of all, primary repair in the historical literature was performed via an arthrotomy, which is a significantly more invasive surgery when compared to the current standard of arthroscopic surgery. Secondly, ROM exercises are currently started early (first few days in our study), while patients historically were placed in a cast and immobilized for four to six weeks.<sup>10</sup> Interestingly, Noyes et al. assessed postoperative ROM following ACL reconstruction and compared arthroscopic surgery with arthrotomy and divided patients in these groups in early and delayed motion postoperatively.<sup>32</sup> The authors concluded that there were correlations of better ROM in the early motion group and better ROM in the arthroscopic group when compared to the arthrotomy and delayed motion groups. When reviewing the complications following open primary repair in the historical literature, problems with ROM have been reported up to 77%.<sup>33</sup> In contrast, when reviewing the two recent publications on arthroscopic primary repair<sup>25,26</sup> and the results of this current study, no complications with regard to ROM were

noted in the cohorts. It seems that the difference between ROM problems in the historical literature of open primary repair and the excellent ROM in this current study of arthroscopic primary repair can be explained by the minimally invasive procedure and early ROM protocols during rehabilitation. Recently, Murray et al. reported the short-term postoperative course of primary repair using a biological scaffold using an arthrotomy approach.<sup>34</sup> They found an average flexion of approximately 90° at six weeks, which is significantly less when compared to this current study. This might be explained by their arthrotomy approach, and the fact that patients were not allowed to flex their knee beyond 90° for six weeks. It seems that their approach might be midway between the historic arthrotomy and casting approach versus our early ROM approach.

It was further noted that adding an internal brace to the repair did not have an influence on ROM (Figure 4). It should be emphasized that an internal brace, which is practically the addition of a doubled length of stout suture that runs in the anterior third of the ligament that is tensioned with suture anchors,<sup>27,35</sup> is different from the recently published technique of the dynamic intraligamentary stabilization (DIS) device.<sup>36,37</sup> With the DIS device, a spring mechanism is placed in the tibia and a braid is placed through the ligament and is fixed proximally on the femoral cortex with a fixation button. With this design, however, many problems have been reported with a 79% complication rate, and a 33% extension deficit rate that required additional reoperation (mostly cyclops lesions),<sup>36</sup> while 60% of the tibial spring mechanisms needed to be removed.<sup>37</sup> This is not surprising as complications with synthetic augmentation devices were frequently reported in the historical literature.<sup>38,39</sup> The internal brace, however, is a minimalist variation of the repair procedure that is only slightly more invasive, and ROM data was not different when compared to primary repair without internal brace in this study. Furthermore, no complications with this technique were noted during the first six months postoperatively. Future studies are needed to further assess if the internal brace indeed protects the ligament and decreases reinjury rates.

Taking a close look at the results in this study, it was noted that the meniscus status played a role on ROM. Because the numbers in the subgroups were small (e.g., n = 5 in meniscus repair group of primary repair patients), outcomes were not significantly different in the meniscus repair analysis. It was noted that ROM differences existed between repair and reconstruction in all meniscus groups at one week postoperatively, but that this depended on the meniscus status at one month postoperatively. Interestingly, Herbst et al. recently assessed the postoperative ROM following ACL reconstruction and noted that the incidence of extension deficits was different in patients with and without meniscus injuries.<sup>40</sup> Although no large extension deficits were present in our study, we similarly noted that ROM was influenced by the meniscus status. Studies with larger number of patients are necessary to compare ROM in these meniscus subgroups. Finally, chondroplasty and the use of autograft versus allograft tissue did not seem to play a role on postoperative ROM, which can be expected when comparing these results with studies in the literature.<sup>41,42</sup>

With regard to our second hypothesis, low incidences of complications (2%) and infections (0%) were found in the cohort of primary repair patients, and there was a trend that this was lower when compared to reconstruction surgery (9% and 6%, respectively). The low complication rate in the primary repair is likely to be multifactorial with the minimally invasive nature of the procedure, (no drilling of tunnels, graft harvesting or use of allograft tissue), and the shorter operation time with repair procedure compared to the reconstruction procedure (Table 5). This was the first study reporting operative times of arthroscopic primary ACL repair, and comparison with the literature was therefore not possible. Some complications of reconstruction surgery can be contributed to graft harvesting, such as the patella fracture, superficial wound infections around the graft harvesting skin or a graft-tunnel mismatch. Furthermore, the risk for infections is generally increased with a longer surgery time that occurs when graft are harvested or when allograft tissue is prepared for graft placement.<sup>43</sup> Although the incidence of infections and deep infections was high following reconstruction (6% and 2%, respectively), others recent studies have reported similar rates or slightly lower rates when stratifying by type of infection (superficial versus deep) when compared to the literature regarding infections following ACL reconstruction.<sup>44,45</sup> One patient had a tibial stress fracture following ACL reconstruction, which may be explained by the fact that abnormal contact stresses occur following ACL reconstruction.<sup>46</sup> It is currently not known if primary repair restores normal kinematics and contact stresses, and studies are necessary to compare the contact stresses following repair vs. reconstruction. Results in this study, nonetheless, showed that complications and infections are rare following arthroscopic primary ACL repair and that this procedure is both safe and relatively expeditious when compared to ACL reconstruction. Larger studies are necessary to assess if the differences between reconstruction and repair are also statistically significant.

Limitations in this study existed. First of all, due to the retrospective design it was not possible to assess if individual adjustments were made during the rehabilitation, despite the fact that the same protocol was used for all patients. Similarly, differences in delay of injury to surgery were present in both groups, which could have led to altered kinematics in the reconstruction group.<sup>47</sup> We believe, however, that this study simulates the clinical setting of acutely treating the subgroup of patients that are repairable,<sup>20,26</sup> while reconstruction patients that are not repairable in a delayed stage. Similarly, differences in age and BMI were noted in both groups, which should be considered when reviewing the outcome in this study, although we believe these differences are small with regards to clinical relevance. Furthermore, baseline characteristics, such as smoking status, were not available and the study cohort was too small to perform multivariate analysis to correct for BMI or graft type, as these factors can increase the risk for infections. Also, the operative times of the procedures were relatively long. This could be explained that no residents or fellows were present at the surgeries, and that the senior author therefore had to prepare the graft himself. However, when comparing the operative times of primary repair with the operative times of ACL reconstruction in the literature, it can be noted that the primary repair procedure is still shorter.<sup>48</sup> Furthermore, the primary repair procedure in this study included the learning curve for the senior author, and

a trend was noted towards shorter operative times as the learning curve was passed, which if included in this analysis, would show a greater difference between both procedures. Also, the numbers of patients were relatively small in this cohort, but we believe that this represents a typical volume for a general orthopaedic surgeon performing ACL surgery, and that the results are therefore generalizable to the average volume orthopaedic surgeon. Finally, the numbers of patients for comparing complication rates were too small to show significance and larger studies or registry studies are necessary to compare complication rates between primary repair and reconstruction surgery. We, however, believe that, based on this data, it can be concluded that primary repair is a safe and minimally invasive procedure.

## **Conclusion**

Patients undergoing arthroscopic primary repair for proximal (type I) tears had more ROM and regained earlier full ROM in the early phases of rehabilitation when compared to patients undergoing ACL reconstruction. Furthermore, a trend of lower complications and fewer infections was seen following primary repair compared to reconstruction, which may be explained by the less invasive nature of the surgery and shorter surgery time. Based on these results, primary repair appears to be a relatively quick and safe procedure with early return of ROM and a low complication rate.

## **Disclosures**

Author J.P.L. declares he has no conflict of interest. Author G.S.D. declares he is a paid consultant for Arthrex (Naples, FL, USA) but this has not conflicted this study.



## References

1. Robson AW. Vi. Ruptured crucial ligaments and their repair by operation. *Ann Surg.* 1903;37(5):716-718.
2. Palmer I. On the injuries to the ligaments of the knee joint. *Acta Orthop Scand.* 1938;53.
3. Palmer I. On the injuries to the ligaments of the knee joint: A clinical study. 1938. *Clin Orthop Relat Res.* 2007;454:17-22; discussion 14.
4. O'Donoghue DH. Surgical treatment of fresh injuries to the major ligaments of the knee. *J Bone Joint Surg Am.* 1950;32 A(4):721-738.
5. O'Donoghue DH. An analysis of end results of surgical treatment of major injuries to the ligaments of the knee. *J Bone Joint Surg Am.* 1955;37(1):1-13.
6. England RL. Repair of the ligaments about the knee. *Orthop Clin North Am.* 1976;7(1):195-204.
7. Feagin JA, Abbott HG, Rokous JR. The isolated tear of the anterior cruciate ligament. *J Bone Joint Surg Am* 1972. p. 1340-1341.
8. Marshall JL, Warren RF, Wickiewicz TL, Reider B. The anterior cruciate ligament: A technique of repair and reconstruction. *Clin Orthop Relat Res.* 1979 (143):97-106.
9. Odensten M, Lysholm J, Gillquist J. Suture of fresh ruptures of the anterior cruciate ligament. A 5-year follow-up. *Acta Orthop Scand.* 1984;55(3):270-272.
10. Warren RF. Primary repair of the anterior cruciate ligament. *Clin Orthop Relat Res.* 1983 (172):65-70.
11. Weaver JK, Derkash RS, Freeman JR, Kirk RE, Oden RR, Matyas J. Primary knee ligament repair--revisited. *Clin Orthop Relat Res.* 1985 (199):185-191.
12. Enneking WF, Horowitz M. The intra-articular effects of immobilization on the human knee. *J Bone Joint Surg Am.* 1972;54(5):973-985.
13. Millett PJ, Wickiewicz TL, Warren RF. Motion loss after ligament injuries to the knee. Part i: Causes. *Am J Sports Med.* 2001;29(5):664-675.
14. Sherman MF, Lieber L, Bonamo JR, Podesta L, Reiter I. The long-term followup of primary anterior cruciate ligament repair. Defining a rationale for augmentation. *Am J Sports Med.* 1991;19(3):243-255.
15. Strand T, Molster A, Hordvik M, Krukhaug Y. Long-term follow-up after primary repair of the anterior cruciate ligament: Clinical and radiological evaluation 15-23 years postoperatively. *Arch Orthop Trauma Surg.* 2005;125(4):217-221.
16. van der List JP, DiFelice GS. Primary repair of the anterior cruciate ligament: A paradigm shift. *Surgeon.* 2017;15(3):161-168.
17. van der List JP, DiFelice GS. Preservation of the anterior cruciate ligament: A treatment algorithm based on tear location and tissue quality. *Am J Orthop (Belle Mead NJ).* 2016;45(7):E393-E405.
18. van der List JP, DiFelice GS. Successful arthroscopic primary repair of a chronic anterior cruciate ligament tear 11 years following injury. *HSS J.* 2017;13(1):90-95.
19. van der List JP, DiFelice GS. The role of ligament repair in anterior cruciate ligament surgery. In: Mascarenhas R, Bhatia S, Lowe WR, editors. *Ligamentous injuries of the knee.* 1 ed. Houston: Nova Science Publishers; 2016. p. 199-220.
20. van der List JP, Mintz DN, DiFelice GS. The location of anterior cruciate ligament tears: A prevalence study using magnetic resonance imaging. *Orthop J Sports Med.* 2017.
21. van der List JP, DiFelice GS. Gap formation following primary repair of the anterior cruciate ligament: A biomechanical evaluation. *Knee.* 2016;24(2):243-249.
22. DiFelice GS, van der List JP. Arthroscopic primary repair of proximal anterior cruciate ligament tears. *Arthrosc Tech.* 2016;5(5):E1057-E1061.
23. van der List JP, DiFelice GS. Preservation of the anterior cruciate ligament: Surgical techniques. *Am J Orthop (Belle Mead NJ).* 2016;45(7):E406-414.
24. DiFelice GS, Villegas C, Taylor SA. Anterior cruciate ligament preservation: Early results of a novel arthroscopic technique for suture anchor primary anterior cruciate ligament repair. *Arthroscopy.* 2015;31(11):2162-2171.
25. Achtnich A, Herbst E, Forkel P, Metzloff S, Sprenger F, Imhoff AB, Petersen W. Acute proximal anterior cruciate ligament tears: Outcomes after arthroscopic suture anchor repair versus anatomic single-bundle reconstruction. *Arthroscopy.* 2016;32(12):2562-2569.

26. Mackay GM, Blyth MJ, Anthony I, Hopper GP, Ribbans WJ. A review of ligament augmentation with the internal brace: The surgical principle is described for the lateral ankle ligament and ACL repair in particular, and a comprehensive review of other surgical applications and techniques is presented. *Surg Technol Int.* 2015;26:239-255.
27. Adachi N, Ochi M, Uchio Y, Iwasa J, Ryoike K, Kuriwaka M. Mechanoreceptors in the anterior cruciate ligament contribute to the joint position sense. *Acta Orthop Scand.* 2002;73(3):330-334.
28. Halinen J, Lindahl J, Hirvensalo E, Santavirta S. Operative and nonoperative treatments of medial collateral ligament rupture with early anterior cruciate ligament reconstruction: A prospective randomized study. *Am J Sports Med.* 2006;34(7):1134-1140.
29. Halinen J, Lindahl J, Hirvensalo E. Range of motion and quadriceps muscle power after early surgical treatment of acute combined anterior cruciate and grade-iii medial collateral ligament injuries. A prospective randomized study. *J Bone Joint Surg Am.* 2009;91(6):1305-1312.
30. Smith JO, Yaseen SK, Palmer HC, Lord BR, Britton EM, Wilson AJ. Paediatric ACL repair reinforced with temporary internal bracing. *Knee Surg Sports Traumatol Arthrosc.* 2016;24(6):1845-1851.
31. Noyes FR, Mangine RE, Barber S. Early knee motion after open and arthroscopic anterior cruciate ligament reconstruction. *Am J Sports Med.* 1987;15(2):149-160.
32. Kaplan N, Wickiewicz TL, Warren RF. Primary surgical treatment of anterior cruciate ligament ruptures. A long-term follow-up study. *Am J Sports Med.* 1990;18(4):354-358.
33. Murray MM, Flutie BM, Kalish LA, Ecklund K, Fleming BC, Proffen BL, Micheli LJ. The bridge-enhanced anterior cruciate ligament repair (bear) procedure: An early feasibility cohort study. *Orthop J Sports Med.* 2016;4(11):2325967116672176.
34. Anthony IC, Mackay GM. Anterior cruciate ligament repair revisited. Preliminary results of primary repair with internal brace ligament augmentation: A case series. *Orthopedic & Muscular System.* 2015;04(02).
35. Evangelopoulos DS, Kohl S, Schwienbacher S, Gantenbein B, Exadaktylos A, Ahmad SS. Collagen application reduces complication rates of mid-substance ACL tears treated with dynamic intraligamentary stabilization. *Knee Surg Sports Traumatol Arthrosc.* 2015.
36. Kohl S, Evangelopoulos DS, Schar MO, Bieri K, Muller T, Ahmad SS. Dynamic intraligamentary stabilisation: Initial experience with treatment of acute ACL ruptures. *Bone Joint J.* 2016;98-b(6):793-798.
37. Grontvedt T, Engebretsen L. Comparison between two techniques for surgical repair of the acutely torn anterior cruciate ligament. A prospective, randomized follow-up study of 48 patients. *Scand J Med Sci Sports.* 1995;5(6):358-363.
38. Kdolsky RK, Gibbons DF, Kwasny O, Schabus R, Plenk H, Jr. Braided polypropylene augmentation device in reconstructive surgery of the anterior cruciate ligament: Long-term clinical performance of 594 patients and short-term arthroscopic results, failure analysis by scanning electron microscopy, and synovial histomorphology. *J Orthop Res.* 1997;15(1):1-10.
39. Herbst E, Hoser C, Gfoller P, Heppinger C, Abermann E, Neumayer K, Musahl V, Fink C. Impact of surgical timing on the outcome of anterior cruciate ligament reconstruction. *Knee Surg Sports Traumatol Arthrosc.* 2017;25(2):569-577.
40. Reinhardt KR, Hetsroni I, Marx RG. Graft selection for anterior cruciate ligament reconstruction: A level I systematic review comparing failure rates and functional outcomes. *Orthop Clin North Am.* 2010;41(2):249-262.
41. Wei J, Yang HB, Qin JB, Yang TB. A meta-analysis of anterior cruciate ligament reconstruction with autograft compared with nonirradiated allograft. *Knee.* 2015;22(5):372-379.
42. Murphy MV, Du DT, Hua W, Cortez KJ, Butler MG, Davis RL, DeCoster TA, Johnson L, Li L, Nakasato C, Nordin JD, Ramesh M, Schum M, Von Worley A, Zinderman C, Platt R, Klompas M. Risk factors for surgical site infections following anterior cruciate ligament reconstruction. *Infect Control Hosp Epidemiol.* 2016;37(7):827-833.
43. Westermann R, Anthony CA, Duchman KR, Gao Y, Pugely AJ, Hettrich CM, Amendola N, Wolf BR. Infection following anterior cruciate ligament reconstruction: An analysis of 6,389 cases. *J Knee Surg.* 2016.
44. Kim HJ, Lee HJ, Lee JC, Min SG, Kyung HS. Evaluation of infection after anterior cruciate ligament reconstruction during a short period. *Knee Surg Relat Res.* 2017;29(1):45-51.

45. Imhauser C, Mauro C, Choi D, Rosenberg E, Mathew S, Nguyen J, Ma Y, Wickiewicz T. Abnormal tibiofemoral contact stress and its association with altered kinematics after center-center anterior cruciate ligament reconstruction: An in vitro study. *Am J Sports Med.* 2013;41(4):815-825.
46. McDonald LS, van der List JP, Jones KJ, Zuiderbaan HA, Nguyen JT, Potter HG, Pearle AD. Passive anterior tibial subluxation in the setting of anterior cruciate ligament injuries. *Am J Sports Med.* 2017:363546516688673.
47. Tian S, Wang B, Liu L, Wang Y, Ha C, Li Q, Yang X, Sun K. Irradiated hamstring tendon allograft versus autograft for anatomic double-bundle anterior cruciate ligament reconstruction: Midterm clinical outcomes. *Am J Sports Med.* 2016;44(10):2579-2588.



# Chapter 9

**Arthroscopic primary repair of proximal anterior cruciate ligament tears seems safe but higher level of evidence is needed: a systematic review and meta-analysis of recent literature**

Jelle P. van der List

Harmen D. Vermeijden

Inger N. Sierevelt

Gregory S. DiFelice

Arthur van Noort

Gino M.M.J. Kerkhoffs

*Knee Surg Sports Traumatol Arthrosc.* 2020. Jun;28(6):1946-1957.

## **Abstract**

### **Purpose**

To assess the outcomes of the various techniques of primary repair of proximal anterior cruciate ligament (ACL) tears in the recent literature using a systematic review with meta-analysis.

### **Methods**

PRISMA guidelines were followed. All studies reporting outcomes of arthroscopic primary repair of proximal ACL tears using primary repair, repair with static (suture) augmentation and dynamic augmentation between January 2014 and July 2019 in PubMed, Embase and Cochrane were identified and included. Primary outcomes were failure rates, reoperation rates, and secondary outcomes were patient-reported outcome scores.

### **Results**

A total of 13 studies and 1101 patients (mean age 31 years, mean follow-up 2.1 years, 60% male) were included. Nearly all studies were retrospective studies without a control group and only one randomized study was identified. Grade of recommendation for primary repair was weak.

There were 10 out of 74 failures following primary repair (14%), 4 out of 69 following repair with static augmentation (6%) and 106 out of 958 following dynamic augmentation (11%). Repair with dynamic augmentation had more reoperations (99; 10%), and more hardware removal (255; 29%) compared to the other procedures. All functional outcome scores were >85% of maximum scores.

### **Conclusions**

This systematic review with meta-analysis found that the different techniques of primary repair are safe with failure rates of 6-14%, no complications and functional outcome scores of >85% of maximum scores. There was a high risk of bias and follow-up was short with 2.1 years. Prospective studies comparing the outcomes to ACL reconstruction with sufficient follow-up are needed prior to widespread implementation.

### **Level of Evidence**

Systematic review of level I, II, III and IV studies

## Introduction

Over the last year there has been a renewed interest in the concept of primary repair of the anterior cruciate ligament (ACL).<sup>1</sup> Open primary repair was commonly performed in the twentieth century and, despite promising short-term results,<sup>2-8</sup> the outcomes were disappointing at longer follow-up.<sup>9-14</sup> This resulted in an abandonment of the primary repair technique at that time and a shift towards ACL reconstruction that is still the gold standard for active and symptomatic patients today.<sup>1,15</sup>

There are multiple reasons why there has been renewed interest in primary repair following the disappointing historical results. Firstly, historically all different tear types were treated with primary repair but several studies have suggested that primary repair should only be performed in selected patients with proximal tears, as there is better vascularity at the proximal end of the ligament<sup>16,17</sup> and several studies shown better results of primary repair of proximal when compared to midsubstance tears.<sup>1,18-22</sup> Another reason for the renewed interest is the lesser invasiveness of the surgery when compared to ACL reconstruction as no grafts are harvested or tunnels drilled, and thereby avoiding donor-site morbidity<sup>23,24</sup> and earlier return to range of motion<sup>25</sup>. Finally, there have been several developments in surgical techniques, such as arthroscopic surgery, suture anchors, dynamic intraligamentary stabilization, and internal bracing, that were not available in the historical studies and this has also been a reason to reassess the outcomes of primary repair in the more recent era.

However, there are also objections to the renewed interest in primary repair. Given the historical disappointing outcomes of open primary repair, several surgeons have presumed that primary repair might be a risky procedure with higher failure rates than reconstruction.<sup>26,27</sup> Furthermore, by performing primary repair in the more acute setting (for optimal tissue quality and prevention of ligament retraction), it is possible that too many ACL surgeries are performed, as some of the conservatively treated patients do well without ACL surgery.<sup>28, 29</sup>

Recently, several small cohort studies have presented the first results of arthroscopic primary repair.<sup>30-35</sup> This systematic review with meta-analysis was therefore performed to assess the safety and efficacy of the renewed primary repair techniques given the disappointing results in the historical literature. The goal of this study was to assess the outcomes of all techniques of primary repair in recent studies and abstracts and compare the outcomes between the different techniques. This study aims to provide an overview of the recent outcomes of various techniques of primary repair of proximal tears.

## Methods

The Preferred Reporting Items for Systematic Reviews and Meta-Analyses (PRISMA) guidelines were followed when performing this study.

### Literature search

A systematic search was performed in the electronic search engines PubMed, Embase and Cochrane Library for studies reporting on outcomes of primary ACL repair. Following a preliminary search, the search algorithm “*Anterior Cruciate Ligament AND (repair OR reinsertion OR reattachment OR healing OR suture)*” was developed and used on July 2, 2019. The search was limited for studies reporting outcomes in the last five years (between January 1, 2014 and June 30, 2019) as recent systematic reviews have shown that no new studies have reported outcomes of modern primary repair before 2014,<sup>18-20</sup> and was limited to English studies.

After duplicate removal, two reviewers (JPL and HDV) first reviewed the title and abstract of all studies and then reviewed full-texts of potential studies on the inclusion and exclusion criteria. References of full-text scanned studies were also reviewed for potentially interesting studies. Agreement was reached on the inclusion and exclusion of all studies and a third independent reviewer (AVN) was not required.

Inclusion criteria were (I) outcomes of primary repair with or without augmentation, (II) (mainly) treating proximal tears, (III) minimum one-year follow-up and (IV) minimum level IV studies. Exclusion criteria were (I) long-term follow-up of historical studies,<sup>18-20</sup> (II) not reporting tear location,<sup>36,37</sup> (III) treating multiligamentous knee injuries or knee dislocations, (IV) treating distal (bony) avulsion tears, (V) pediatric patient population,<sup>38-40</sup> abstracts without full-text<sup>41-44</sup> or (VI) multiple studies that report on the same group of patients (smallest cohort study or shortest follow-up excluded)<sup>30,33,45-51</sup>.

### Methodological quality of studies

Level of evidence of the included studies was assessed using the adjusted Oxford Centre for Evidence-Based Medicine 2011 Levels of Evidence.<sup>52</sup> The methodological quality of included studies was assessed using the Methodological Index for Non-Randomized Studies (MINORS) instrument,<sup>53</sup> which is an instrument designed to assess methodological quality of both non-comparative and comparative studies. For this study only the cohorts of primary repair were used and therefore only the non-comparative factors of the MINORS instrument were used. The strength of recommendation was determined using the Grades of Recommendation, Assessment, Development, and Evaluation (GRADE) Working Group system.<sup>54</sup>

### Data extraction

All data was collected in Excel 2017 (Microsoft Corp., Redmond, WA, USA). Collected baseline characteristics data included author names, year of publication, number of patients at follow-



up, length of follow-up, age, delay from injury to surgery and gender. Surgical techniques in the literature consisted of primary repair without augmentation, repair with static (suture (Internal Brace)) augmentation and repair with dynamic augmentation (Ligamys). For the repair without and with dynamic augmentation, the method of femoral fixation technique (transosseous tunnels or suture anchor) was also assessed. Collected outcomes consisted of failures (defined as rerupture or symptomatic instability), reoperations (defined as operation for other reason than revision), and removal of hardware (ROH; defined as removal of hardware without any other concomitant procedure). Furthermore, clinical stability consisting of Lachman and pivot shift test, and KT-1000 measurements (absolute measurements and percentage <3mm side-to-side difference) were collected. Collected outcome scores were international Knee Documentation Committee (IKDC) objective and subjective score,<sup>55</sup> preinjury and postoperative Tegner score,<sup>56</sup> Lysholm score,<sup>57</sup> modified Cincinnati score,<sup>58,59</sup> Sports subscale of the Knee injury and Osteoarthritis Outcome Score (KOOS),<sup>60</sup> Single Assessment Numeric Score (SANE) on knee function,<sup>61</sup> and visual analogue scale (VAS) for pain as these were most commonly reported and considered as relevant outcomes measures. Categorical outcomes were reported in percentages, and continuous outcomes were reported in mean  $\pm$  standard deviation (SD). In case results were presented otherwise, transformation to means and SD was performed according to previously defined methods.<sup>62-64</sup> Pooled outcomes were collected for continuous outcomes by calculating weighted average and by calculating the incidence (e.g. total patients with KT-1000 side-to-side difference <3mm/total patients tested x 100%).

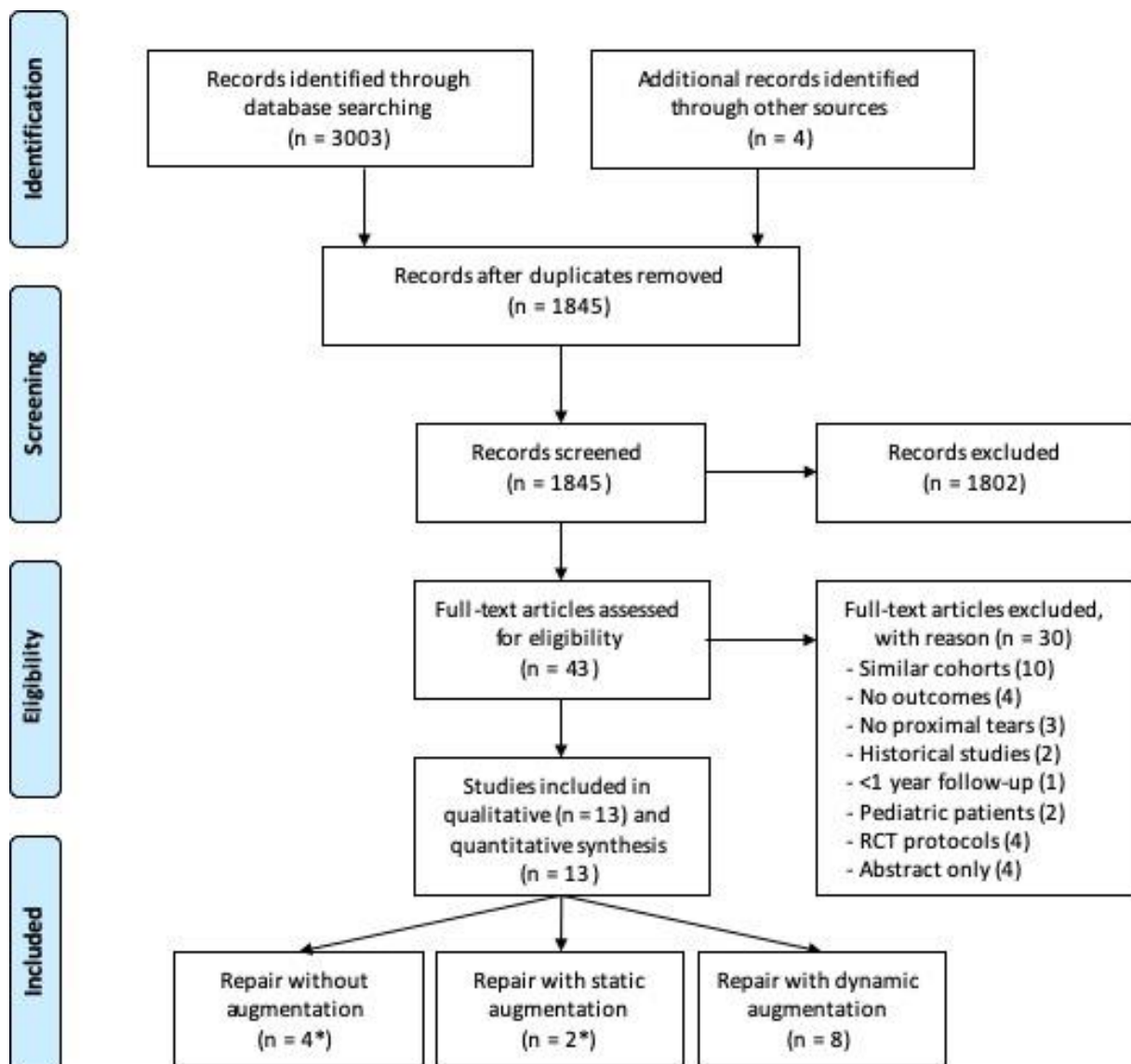
### **Statistical analysis**

Statistical analysis was performed using SPSS Statistics version 25.0 (SPSS Inc., Armonk, NY, USA) and Excel 2017. Differences in incidence were assessed using Pearson Chi-Square test and Fisher's exact test (in case of expected values <5). Continuous variables were not statistically compared, but the overall mean and standard deviations were calculated using standardized methods.<sup>64</sup> Forest plots were performed to assess differences for preinjury and postoperative Tegner activity levels by use of RevMan 5.3 and only studies reporting both preinjury and postoperative Tegner levels were included for this analysis. All tests were two-sided and a  $p < 0.05$  was considered statistically significant.

# Results

## Literature Search

Eighteen hundred forty-five articles were screened on title and abstract for eligibility and forty-three articles were reviewed on their full-text for inclusion. A total of 13 studies reported on outcomes of primary repair and were included<sup>21,31,32,34,35,65-72</sup> of which four used primary repair,<sup>31,32,35,72</sup> two used primary repair with suture augmentation,<sup>34,72</sup> (one reported outcomes of both with and without suture augmentation<sup>72</sup>) and eight used primary repair with dynamic augmentation (Figure 1)<sup>21,65-71</sup>.



**Figure 1.** A PRISMA flowchart of the inclusion and exclusion of the study is shown. The dotted line indicates that the study was included for qualitative synthesis but not for quantitative synthesis.

## Methodological quality of studies

One study was a level I study (8%),<sup>68</sup> there were no level II studies, two studies were level III studies (15%)<sup>31, 72</sup> and the majority (ten studies; 77%) were level IV studies<sup>21,32,34,35,65-67,69-71</sup>. The recommendation for using primary repair for proximal ACL tears was weak using the GRADE system. The methodological quality of studies was graded according to the MINORS criteria (Table 1) and the average score was 10.9 out 16 points (68% of maximum). No blinding was applied in any of the studies and only two studies compared their results to ACL reconstruction<sup>31,68</sup> of which one was a randomized controlled study (RCT)<sup>68</sup>.

**Table 1.** Quality assessment of the included studies using the Methodological Index for NonRandomized Studies (MINORS) criteria

Authors	Year	Journal/Meeting	Evidence	Study design	1	2	3	4	5	6	7	8	Total
Achtnich et al. <sup>31</sup>	2016	Arthroscopy	III	Prospective	2	2	1	2	1	2	2	0	12
Ateschrang et al. <sup>65</sup>	2017	KSSTA	IV	Case Series	2	2	2	2	0	1	1	0	10
Büchler et al. <sup>66</sup>	2016	Knee	IV	Case Series	2	2	1	2	0	1	2	0	10
Häberli et al. <sup>67</sup>	2018	Knee	IV	Case Series	2	2	1	2	0	2	2	0	11
Heusdens et al. <sup>34</sup>	2018	KSSTA	IV	Case Series	2	2	2	1	0	1	2	1	11
Hoffmann et al. <sup>32</sup>	2017	J Orthop Surg Res	IV	Case Series	2	2	0	2	1	2	2	0	11
Hoogeslag et al. <sup>68</sup>	2019	Am J Sports Med	I	RCT	2	2	2	2	1	2	2	2	15
Jonkergouw et al. <sup>72</sup>	2018	AOSSM	III	Retrospective	2	2	1	2	0	1	2	0	10
Kohl et al. <sup>69</sup>	2016	BJJ	IV	Case Series	1	2	2	2	0	2	2	0	11
Krismer et al. <sup>21</sup>	2017	KSSTA	IV*	Case Series	2	2	0	2	0	2	2	0	10
Meister et al. <sup>70</sup>	2017	KSSTA	IV	Case Series	2	1	2	2	0	1	2	0	10
Mukhopadhyay et al. <sup>35</sup>	2018	Chin J Traumatol	IV	Case Series	1	2	2	2	0	2	2	0	11
Osti et al. <sup>71</sup>	2018	KSSTA	IV	Case Series	2	2	2	1	0	1	2	0	10

Only the non-comparative part of the MINORS criteria was used (i.e., first 8 questions).

The criteria of MINORS<sup>53</sup> with 0 points when not reported, 1 when reported but not adequate, and 2 when reported and adequate. Maximum score is 16.

1. A clearly stated aim: the question addressed should be precise and relevant in the light of available literature.
2. Inclusion of consecutive patients: all patients potentially fit for inclusion (satisfying the criteria for inclusion) have been included in the study during the study period (no exclusion or details about the reasons for exclusion).
3. Prospective collection of data: data were collected according to a protocol established before the beginning of the study.
4. End points appropriate to the aim of the study: unambiguous explanation of the criteria used to evaluate the main outcome which should be in accordance with the question addressed by the study. In addition, the end points should be assessed on an intention-to-treat basis.
5. Unbiased assessment of the study end point: blind evaluation of objective end points and double-blind evaluation of subjective end points. Otherwise the reasons for not blinding should be stated.
6. Follow-up period appropriate to the aim of the study: the follow-up should be sufficiently long to allow the assessment of the main endpoint and possible adverse events.
7. Loss to follow-up less than 5%: all patients should be included in the follow-up. Otherwise, the proportion lost to follow-up should not exceed the proportion experiencing the major end point.
8. Prospective calculation of the study size: information of the size of detectable difference of interest with a calculation of 95% CI, according to the expected incidence of the outcome event, and information about the level for statistical.

\* This study reported being a level II studies but we have classified this case series with failure analysis as level IV study

## Baseline characteristics

A total of 1101 patients in 13 different studies were included in this study with a mean age of 31 years, mean follow-up of 2.1 years, mean delay of 2 weeks and of which 60% were males.

Four studies performed arthroscopic primary repair without augmentation, of which in one study two suture anchors were used to reattach the ACL back to the femoral footprint,<sup>72</sup> in two studies one suture anchor,<sup>31,32</sup> and in one study transosseous tunnel fixation was used.<sup>35</sup> A total of 74 patients were included of which 63% were male. Mean age was 35 years, mean follow-up was 3.7 years and mean delay was 3 weeks. All patients had proximal tears (100%) (Table 2).

Two studies reported on outcomes of arthroscopic primary with static augmentation, of which in one study transosseous tunnels for ACL fixation were used,<sup>34</sup> and in one study two suture anchors with suture augmentation in the proximal suture anchor were used (Table 2).<sup>72</sup> A total of 69 patients were included of which 57% were male. Mean age was 32 years, mean follow-up was 2.2 years and mean delay was 4 weeks (Table 2). All patients had proximal tears (100%).

Eight studies performed primary repair with dynamic augmentation on a total of 958 patients of which 60% were male. Mean age of these patients was 31 years, mean follow-up was 2.0 years and mean delay was 2 weeks. A total of 77% of patients had proximal tears (range 62% - 100%) (Table 2).

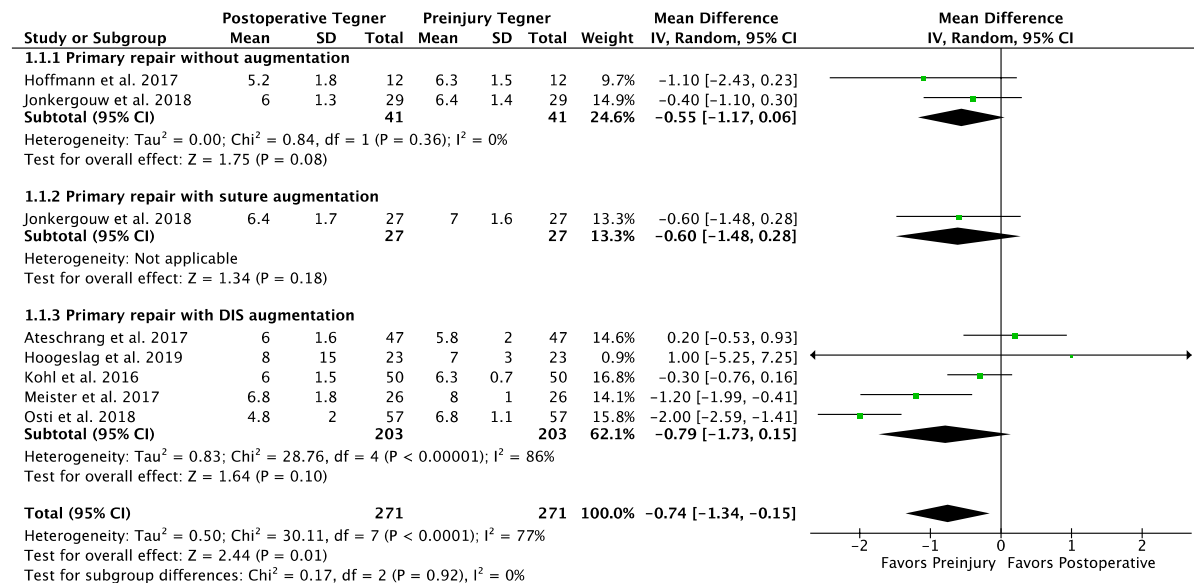
## Outcomes

In 74 patients who underwent primary repair without augmentation, the failure rate was 14%, additional reoperation rate 4%, and no ROH was reported. Eighty-two percent of patients had stable Lachman examination and 84% negative pivot shift (Table 2). Mean KT-1000 side-to-side difference was  $1.9 \pm 1.5$  mm and 91% had  $<3$ mm side-to-side difference. Eighty-three percent had an IKDC objective score of A or B. The Tegner score changed from  $6.4 \pm 1.3$  preinjury to  $5.8 \pm 1.4$  postoperatively (Figure 2), Lysholm score was  $93 \pm 11$ , modified Cincinnati was  $91 \pm 13$ , and the IKDC subjective was  $90 \pm 14$  (Table 3).

In 69 patients undergoing primary repair with static augmentation, the failure rate was 6%, additional reoperation rate 0% and ROH rate 3% (Table 2). Eighty-nine percent of patients had IKDC objective scores of A or B in one study. Tegner score changed from  $7.0 \pm 1.6$  to  $6.4 \pm 1.7$  in one study (Figure 2). Lysholm score was  $93 \pm 8$ , modified Cincinnati  $93 \pm 10$ , IKDC subjective  $89 \pm 10$ , and KOOS Sports  $77 \pm 31$  (Table 3).

In 958 patients undergoing primary repair with dynamic augmentation, the failure rate was 11%, additional reoperation rate 10%, and additional ROH 29%. Lachman examination was negative in 86% (two studies) and pivot shift was negative in 90% (one study) (Table 2). Mean KT-1000 examination was  $1.0 \pm 1.7$  mm and 77% had  $<3$ mm side-to-side difference. Ninety

percent had IKDC objective A or B. Tegner score changed from 6.7±1.5 preinjury to 6.1±1.8 postoperatively (Figure 2), Lysholm score was 95±6, and the IKDC subjective score was 92±8 (Table 3).



**Figure 2.** A Forest plot is shown with the preinjury and postoperative Tegner activity scores showing that a 0.7 level decrease in Tegner activity score can be expected following primary repair (regardless of technique; p=0.01). The numbers on the right graph display the mean difference in Tegner score between preinjury and postoperative.

### Differences between treatments

No differences were seen in failure rate between primary repair and repair with static augmentation (n.s.), between primary repair and dynamic augmentation (n.s.) nor between static and dynamic augmentation (n.s.). Primary repair with dynamic augmentation had more frequently reoperations when compared to primary repair with static augmentation (10% vs. 0%; p<0.01), and had more frequently removal of hardware when compared to primary repair (29% vs. 0%; p<0.01) and to repair with static augmentation (29% vs. 3%; p<0.01). No differences between primary repair and repair with static augmentation were found for reoperations (n.s.) or ROH (n.s.). No clinically meaningful differences were noted in any of the functional and patient-reported outcome scores between all treatment groups. No studies reported on return to sports (RTS).

**Table 2.** Study characteristics with failure and reoperation rates of studies/abstracts reporting outcomes of arthroscopic primary ACL repair of proximal tears

Authors	Year	No. pts	FU (years)		Age (years)		Delay (wks)	Male (%)	Prox (%)	Fail. (%)	Reop. (%)	ROH (%)		Lachman		Pivot shift				
			Mn	Range	Mn	Range						Mn	Range	Neg.	Pos.	Neg.	Pos.			
<b>Primary repair without augmentation</b>																				
Achtnich et al. <sup>31</sup>	2016	20	2.3	2.0 - 2.6	30		< 6*		100%	15%	5%	0%	85%	15%	80%	20%				
Hoffmann et al. <sup>32</sup>	2017	12	6.6	5.0 - 8.2	43	19 - 67	1	0 - 3	25%	25%	0%	0%	75%	25%	75%	25%				
Jonkergouw et al. <sup>72</sup>	2018	29	4.0	2.0 - 9.2	37	15 - 57	5	1 - 574	62%	14%	7%	0%	100%	0%	100%	0%				
Mukhopadhyay et al. <sup>35</sup>	2018	13	2.6	2.2 - 3.2	31	21 - 40	1	0 - 2	100%	0%	0%	0%	85%	15%	100%	0%				
<b>Primary repair with static augmentation</b>																				
Heusdens et al. <sup>34</sup>	2018	42	2.0		33	14 - 60		< 13*	57%	5%	0%	0%	100%	0%	0%	0%				
Jonkergouw et al. <sup>72</sup>	2018	27	2.4	2.0 - 4.4	30	14 - 44	4	1 - 22	56%	7%	0%	7%	100%	0%	0%	7%				
<b>Primary repair with dynamic augmentation</b>																				
Ateschrang et al. <sup>65</sup>	2017	47	1.0		28		2		57%	11%	17%		100%	11%	17%					
Büchler et al. <sup>66</sup>	2016	45	1.0		26	18 - 54	2	0 - 3	72%	7%	0%		73%	7%	0%					
Häberli et al. <sup>67</sup>	2018	446	2.3	1.8 - 5.3	33			< 9*	56%	9%	12%	27%	73% <sup>†</sup>	9%	12%	27%				
Hoogslag et al. <sup>68</sup>	2019	23	2.0		21	10 - 27	2	2 - 2	79%	9%	21%	0%	83%	9%	21%	0%				
Kohl et al. <sup>69</sup>	2016	50	2.0		30	18 - 50	2	0 - 3	68%	10%	18%	60%	80%	10%	18%	60%				
Krismer et al. <sup>21</sup>	2017	264		>2.0	31		2		59%	14%	2%	35%	77%	14%	2%	35%				
Meister et al. <sup>70</sup>	2017	26	1.0	1.0 - 1.2	28	18 - 50	2	1 - 4	65%	15%	20%	8%	62%	15%	20%	8%				
Osti et al. <sup>71</sup>	2019	57	1.0		28	15 - 54	2	0 - 4	65%	18%	23%	18%	84%	18%	23%	18%				
<b>Total primary repair</b>		<b>74</b>	<b>3.7</b>	<b>2.0 - 9.2</b>	<b>35</b>	<b>15 - 67</b>	<b>3</b>	<b>0 - 547</b>	<b>63%</b>	<b>14%</b>	<b>4%</b>	<b>0%</b>	<b>100%</b>	<b>14%</b>	<b>4%</b>	<b>0%</b>	<b>82%</b>	<b>18%</b>	<b>84%</b>	<b>16%</b>
<b>Total repair with SA</b>		<b>69</b>	<b>2.2</b>	<b>2.0 - 4.4</b>	<b>32</b>	<b>14 - 60</b>	<b>4</b>	<b>1 - 22</b>	<b>57%</b>	<b>6%</b>	<b>0%</b>	<b>3%</b>	<b>100%</b>	<b>6%</b>	<b>0%</b>	<b>3%</b>				
<b>Total repair with DIS</b>		<b>958</b>	<b>2.0</b>	<b>1.0 - 5.3</b>	<b>31</b>	<b>10 - 54</b>	<b>2</b>	<b>1 - 29</b>	<b>60%</b>	<b>11%</b>	<b>10%</b>	<b>29%</b>	<b>77%</b>	<b>11%</b>	<b>10%</b>	<b>29%</b>	<b>86%</b>	<b>14%</b>	<b>90%</b>	<b>10%</b>
<b>Total</b>		<b>1101</b>	<b>2.1</b>	<b>1.0 - 9.2</b>	<b>31</b>	<b>10 - 67</b>	<b>2</b>	<b>0 - 547</b>	<b>60%</b>	<b>11%</b>	<b>9%</b>	<b>25%</b>	<b>79%</b>	<b>11%</b>	<b>9%</b>	<b>25%</b>	<b>84%</b>	<b>16%</b>	<b>87%</b>	<b>13%</b>

No. pts indicates number of patients; FU, follow-up in years; wks, weeks; Mn, mean; Mn, range; prox., percentage of patients with proximal tears; reop., reoperation; ROH, removal of hardware; RTS, return to sports; Comp, complications; Neg, negative; Pos, positive; SA, suture augmentation. \* data collected from another study with same cohort of patients

<sup>†</sup> These studies only reported criteria such as operation within certain number of weeks. <sup>‡</sup> Data collected from another study with same cohort of patients<sup>51</sup>

No studies reported on the return to sport rate following primary repair at follow-up except

**Table 3.** Functional and patient-reported outcomes of studies/abstracts reporting outcomes of arthroscopic primary ACL repair of proximal tears

Authors	Year	No. of pts	KT-1000 Min±SD	<3mm	A	B	C	D	Tegner Pre <sup>†</sup>	Post <sup>†</sup>	Lys-holm	Mod. Cinc.	IKDC Subj	KOOS Sports	SANE	VAS pain
<b>Primary repair without suture augmentation</b>																
Achtlich et al. <sup>31</sup>	2016	20	2.0±1.7	65%	20%	15%	0%									
Hoffmann et al. <sup>32</sup>	2017	12	2.1±1.3	78%	73%	9%	18%	0%	6.3±1.5	5.2±1.8	85±20	84±21	87±17			
Jonkergouw et al. <sup>72</sup>	2018	29	1.9±1.6*	88*	73%	9%	18%		6.4±1.4	6.0±1.3	95±8	94±8	91±12		89±15	
Mukhopadhyay et al. <sup>35</sup>	2018	13	1.7±0.7	100%							95±1					
<b>Primary repair with static augmentation</b>																
Heusdens et al. <sup>34</sup>	2018	42												77±31		1.3±1.9
Jonkergouw et al. <sup>72</sup>	2018	27		72%	17%	11%			7.0±1.6	6.4±1.7	93±8	93±10	89±10		90±10	
<b>Primary repair with dynamic augmentation</b>																
Ateschrang et al. <sup>65</sup>	2017	47	2.1±2.2	42%	45%	7%	7%		5.8±2.0	6.0±1.6	91±8		86±10			
Büchler et al. <sup>66</sup>	2016	45	0.0±1.6	100%						7.0±1.1			90±7			**
Häberli et al. <sup>67</sup>	2018	446							5.1±1.5							
Hoogeslag et al. <sup>68</sup>	2019	23	1.2±0.9	100%	87%	13%	0%	0%	8.0±1.5	7.0±3.0			93±14	78±19		
Kohl et al. <sup>69</sup>	2016	50	1.2±1.6						6.3±0.7	6.0±1.5	100±1		99±1			
Krismer et al. <sup>21</sup>	2017	264							6.8±5.2							
Meister et al. <sup>70</sup>	2017	26		69%	66%	19%	10%	5%	8.0±1.0	6.8±1.8	94±11					
Osti et al. <sup>71</sup>	2019	57		51%					6.8±1.1	4.8±2.0						
<b>Total primary repair</b>		<b>74</b>	<b>1.9±1.5</b>	<b>91%</b>	<b>83%</b>	<b>17%</b>			<b>6.4±1.3</b>	<b>5.8±1.4</b>	<b>93±11</b>	<b>91±13</b>	<b>90±14</b>		<b>89±15</b>	
<b>Total repair with SA</b>		<b>69</b>			<b>89%</b>	<b>11%</b>			<b>7.0±1.6</b>	<b>6.4±1.7</b>	<b>93±8</b>	<b>93±10</b>	<b>89±10</b>	<b>77±31</b>	<b>90±10</b>	<b>1.3±1.9</b>
<b>Total repair with DIS</b>		<b>958</b>	<b>1.0±1.7</b>	<b>77%</b>	<b>90%</b>	<b>10%</b>			<b>6.7±1.5</b>	<b>6.1±1.8</b>	<b>95±6</b>		<b>92±8</b>	<b>78±19</b>		
<b>Total</b>		<b>1101</b>	<b>1.2±1.6</b>	<b>77%</b>	<b>87%</b>	<b>13%</b>			<b>6.7±1.4</b>	<b>6.1±1.7</b>	<b>94±8</b>	<b>92±12</b>	<b>91±9</b>	<b>77±27</b>	<b>90±13</b>	<b>1.3±1.9</b>

No. of pts indicates number of patients; IKDC, International Knee Documentation Committee score; Mod. Cinc., modified Cincinnati score; KOOS, Knee injury and Osteoarthritis Outcome Score (sports subscale); SANE, Single Assessment Numeric Evaluation; VAS, visual analog score; Mn, mean; SD, standard deviation.

\* Data collected from another study with same cohort of patients<sup>30</sup>. † Only total sum calculated when both preinjury and postoperative Tegner score were reported

\*\* Excluded due to inconsistency in data presentation

## Discussion

The main findings of this systematic review with meta-analysis were that the outcomes of primary repair have been reported in 1101 patients using three different techniques (primary repair, repair with static augmentation and repair with dynamic augmentation) and that the procedures seemed safe with failure rates of 6 – 14%, no complications and patient reported outcomes of >85% of the maximum scores. It was further noted that repair with dynamic augmentation lead to a higher reoperation rate (10%) and higher ROH rate (29%). Nearly all studies were retrospective case series with mean 2.1 year follow-up and there was a high risk of bias in these studies, and therefore there was a low grade of recommendation for repair based on these studies.

Over the last few years, there has been a renewed interest in primary ACL repair and there are many reasons why the technique is being revisited. One of the main reasons for this renewed interest in primary repair is the strict patient selection that have been applied to the modern studies by only performing repairs on proximal tears.<sup>18,19</sup> Historically all tear types were repaired (of which most were midsubstance tears) and it is believed that this explains the disappointing historical outcomes of primary repair given the better vascularity and healing potential at the distal and proximal ends of the ligament.<sup>16,17</sup> When reviewing the historical<sup>18</sup> and recent<sup>21,73</sup> studies on primary repair, it has been shown that the outcomes of proximal tears are indeed better than repair of midsubstance tears. Another reason for the revisitation of primary repair is that historically surgery was performed using an arthrotomy, and the technique consisted of suturing the torn end of the ACL together<sup>6</sup> or using drill holes<sup>9</sup>, whereas now suture anchors, static and dynamic augmentation and arthroscopic surgery are available.

When reviewing the failure rates in this study, it was noted that all three techniques reported acceptable failure rates ranging from 6% to 14% without statistical significant or clinically relevant differences between the techniques. It is difficult comparing these failure rates to the failure rates of ACL reconstruction in the literature as ACL reconstruction literature has more studies with higher level of evidence and larger number of patients. However, it seems that the failure rates of ACL reconstruction are generally lower than the failure rates of primary repair. In the Danish Registry, revision rates of ACL reconstruction at two-years were 3%, although this registry only included revisions and not (non-operatively treated) failures,<sup>74</sup> and failure rates in two large recent and meta-analyses were 7% for patients with an average age of 25 years.<sup>75,76</sup> Two studies in this current study compared the outcomes of repair with reconstruction. Achtnich et al. compared 20 patients with ACL reconstruction to 20 patients with ACL repair for proximal tears, and noted similar outcomes in IKDC objective scores and KT-1000 stability with a higher failure rate in repair (15%) when compared to reconstruction (0%).<sup>31</sup> Hoogeslag et al. recently performed a randomized controlled trial in which they compared the outcomes of 23 patients undergoing primary repair with dynamic augmentation with 21 patients undergoing ACL reconstruction.<sup>68</sup> They noted at follow-up similar patient-



reported outcome scores and a higher failure rate of ACL reconstruction (19.0%) when compared to dynamic augmented repair (8.7%). When reviewing the overall pooled failure rates of primary repair in this study (6% – 14%), it seems that primary repair is a safe procedure with acceptable failure rates at short-term follow-up. It should be noted that these studies are mainly short-term follow-up, and more comparative studies with longer follow-up are necessary.

When reviewing reoperations in this study, reoperation rates of 0% to 10% were noted. A significantly higher reoperation rate was present following primary repair with dynamic augmentation compared to primary repair and repair with static augmentation. When reviewing dynamic augmentation, it is noted that most reoperations were due to scar tissue, range of motion deficits and arthrofibrosis. This might be explained by the additional spring device that is implanted in the tibia with this surgery. Similar to the reoperation rate, a higher removal of hardware rate was noted following dynamic augmentation compared to primary repair and primary repair with suture augmentation. When reviewing the study with the highest ROH rate by Kohl et al.<sup>69</sup> (60%), they stated that the tibial Ligamys implant was large and this led to the frequent removal of hardware in addition to the risk of arthrofibrosis.<sup>69</sup> The overall removal of hardware rate seems rather high with the dynamic augmentation procedure although it should be noted that not all patients had symptomatic ROH. Nonetheless, when combining failure rates, reoperation rates and ROH rates, more than half of dynamic augmentation repair patients had a complicated procedure, and future studies need to assess the additional value of the dynamic augmentation with these reoperation rates, especially given the findings in this study that the failure rates or reoperations rates were not lower with dynamic augmentation repair.

Interestingly, none of the studies reported return to sports (RTS) rates following any of the techniques besides the Tegner activity scale. It is possible that this has not been reported due to the small sample size of the studies and the relatively new surgical technique. The Tegner activity level dropped on average from 6.6 pre-injury to 5.9 at follow-up but future studies assessing the RTS as this is one of the main goals of ACL surgery.<sup>77</sup>

Besides the aforementioned potential advantages of primary repair, there are also potential disadvantages of primary repair. Since primary repair needs to be performed in the (sub)acute setting in order to prevent ligament retracting and to optimize tissue quality,<sup>78-80</sup> patients will be operated without attempting conservative treatment first and this will likely result in performing ACL surgery in a subset of patients that do not need ACL surgery. Some guidelines recommend attempting conservative treatment first in patients that do not return to pivoting sports or are willing to adjust their activity level as some of the conservatively treated patients may be copers and do not need ACL surgery.<sup>28,29</sup> On the contrary, treating patients conservatively or delaying the interval between injury and surgery increases the chance of meniscus and chondral damage<sup>28,81-83</sup> and several studies have shown that meniscus damage and meniscectomy increases the rate of osteoarthritis at longer follow-up.<sup>84,85</sup> A study by

Sanders et al. showed at 14-year follow-up that performing ACL reconstruction decreases the risk of secondary meniscus tears, subsequent osteoarthritis and the need for total knee arthroplasty when compared to treating ACL injuries conservatively.<sup>81</sup> Ideally, it should be identified early which patients require surgery in order to decrease the chance of secondary meniscus or chondral damage, improve outcomes of ACL reconstruction,<sup>82</sup> and ultimately decrease the risk of osteoarthritis at longer-term follow-up.<sup>81,84,85</sup> Potentially, in these patients there might also be a role for primary repair in case a proximal tear is found during surgery, which is estimated to occur in approximately 15% to 40% of patients with acute ACL tears.<sup>86,87</sup>

Limitations of this study are present. First of all, most included studies in this review were of retrospective nature and had no control group and therefore no direct comparison between different treatments could be performed. This made it impossible to avoid or decrease potential bias, such as selection bias of which patients were treated with repair and publication bias. It should be mentioned, however, that there were two well-performed studies that compared their outcomes with ACL reconstruction and more of these studies are needed.<sup>31,68</sup> Secondly, not all patients in the dynamic augmentation group had proximal tears which could influence the outcomes of dynamic augmentation repair. When considering that better outcomes of dynamic augmentation repair have been reported in patients with proximal tears,<sup>21</sup> it should be noted better outcomes are expected when only patients with proximal tears are treated in the dynamic augmentation studies. Furthermore, the total number of patients in this study were small due to the relatively “new” treatment, which prevents drawing hard conclusions on the pooled outcomes. Finally, no correction for potential confounders such as concomitant injuries (e.g. meniscus or chondral injuries), age, gender, level of activity, or length of follow-up could be performed due to the relatively low number of patients and these could significantly influence outcomes. Despite these limitations, this study is the first to provide an overview of the recent outcomes of various techniques of primary repair of proximal tears and the current level of evidence that is available on primary repair.

## **Conclusion**

This systematic review with meta-analysis found that the different techniques of primary repair (primary repair without augmentation, with static and with dynamic augmentation) were safe with failure rates between 6% and 14%, and good functional outcome scores in 1101 patients. Higher reoperation rates (10%) and removal of hardware rates (29%) were noted with dynamic augmentation repair. Nearly all studies were retrospective without a control group and possessed a high risk of bias and prospective studies comparative studies with sufficient follow-up are needed prior to widespread implementation.

## **Conflict of interest**

JPL and GSD declare they are a paid consultant for Arthrex and GSD receives research funding from Arthrex. This has not influenced the work of this study. HDV, AN and GMMJK declare they have no conflict of interest.

## References

1. Van der List JP, DiFelice GS. Primary repair of the anterior cruciate ligament: A paradigm shift. *Surgeon*. 2017 Jun;15(3):161-168.
2. Feagin JA, Abbott HG, Rokous JR. The isolated tear of the anterior cruciate ligament. *J Bone Joint Surg Am*. 1972;54(6):1340-1341.
3. Cabitza P, Colombo A, Verdoia C. Follow-up of results obtained with O'Donoghue's technique in the repair of recent lesions of the anterior cruciate ligament. *Minerva Ortop*. 1978;29(12):579-583.
4. Nixon JE. Acute injuries of the anterior cruciate ligament of the knee: Primary repair. *Bull N Y Acad Med*. 1980 Jun;56(5):483-487.
5. Marshall JL, Warren RF, Wickiewicz TL. Primary surgical treatment of anterior cruciate ligament lesions. *Am J Sports Med*. 1982;10(2):103-107.
6. Warren RF. Primary repair of the anterior cruciate ligament. *Clin Orthop Relat Res*. 1983 Jan-Feb;172:65-70.
7. Marcacci M, Spinelli M, Chiellini F, Buccolieri V. Notes on 53 cases of immediate suture of acute lesions of the anterior cruciate ligament. *Ital J Orthop Traumatol*. 1985;7(2):69-79.
8. Sherman MF, Bonamo JR. Primary repair of the anterior cruciate ligament. *Clin Sports Med*. 1988;7(4):739-750.
9. Feagin JA, Jr., Curl WW. Isolated tear of the anterior cruciate ligament: 5-year follow-up study. *Am J Sports Med*. 1976;4(3):95-100.
10. Odensten M, Lysholm J, Gillquist J. Suture of fresh ruptures of the anterior cruciate ligament. A 5-year follow-up. *Acta Orthop Scand*. 1984;55(3):270-272.
11. Engebretsen L, Benum P, Sundalsvoll S. Primary suture of the anterior cruciate ligament a 6-year follow-up of 74 cases. *Acta Orthop Scand*. 1989;60(5):561-564.
12. Jonsson T, Peterson L, Renstrom P. Anterior cruciate ligament repair with and without augmentation. A prospective 7-year study of 51 patients. *Acta Orthop Scand*. 1990;61(6):562-566.
13. Kaplan N, Wickiewicz TL, Warren RF. Primary surgical treatment of anterior cruciate ligament ruptures. A long-term follow-up study. *Am J Sports Med*. 1990 Jul-Aug;18(4):354-358.
14. Sherman MF, Lieber L, Bonamo JR, Podesta L, Reiter I. The long-term followup of primary anterior cruciate ligament repair. Defining a rationale for augmentation. *Am J Sports Med*. 1991;19(3):243-255.
15. Mather RC, 3rd, Koenig L, Kocher MS, Dall TM, Gallo P, Scott DJ, Bach BR, Jr., Spindler KP, Group MK. Societal and economic impact of anterior cruciate ligament tears. *J Bone Joint Surg Am*. 2013 Oct 2;95(19):1751-1759.
16. Toy BJ, Yeasting RA, Morse DE, McCann P. Arterial supply to the human anterior cruciate ligament. *J Athl Train*. 1995 Jun;30(2):149-152.
17. Nguyen DT, Ramwadhoebe TH, van der Hart CP, Blankevoort L, Tak PP, van Dijk CN. Intrinsic healing response of the human anterior cruciate ligament: An histological study of reattached acl remnants. *J Orthop Res*. 2014 Feb;32(2):296-301.
18. Van der List JP, DiFelice GS. Role of tear location on outcomes of open primary repair of the anterior cruciate ligament: A systematic review of historical studies. *Knee*. 2017 Oct;24(5):898-908.
19. Van Eck CF, Limpisvasti O, ElAttrache NS. Is there a role for internal bracing and repair of the anterior cruciate ligament? A systematic literature review. *Am J Sports Med*. 2018 Jul;46(9):2291-2298.
20. Taylor SA, Khair MM, Roberts TR, DiFelice GS. Primary repair of the anterior cruciate ligament: A systematic review. *Arthroscopy*. 2015 Nov;31(11):2233-2247.
21. Krismmer AM, Gousopoulos L, Kohl S, Ateschrang A, Kohlhof H, Ahmad SS. Factors influencing the success of anterior cruciate ligament repair with dynamic intraligamentary stabilisation. *Knee Surg Sports Traumatol Arthrosc*. 2017;25(12):3923-3928.
22. Van der List JP, DiFelice GS. Preoperative magnetic resonance imaging predicts eligibility for arthroscopic primary anterior cruciate ligament repair. *Knee Surg Sports Traumatol Arthrosc*. 2018 July 13;26(2):660-671.
23. Kraeutler MJ, Bravman JT, McCarty EC. Bone-patellar tendon-bone autograft versus allograft in outcomes of anterior cruciate ligament reconstruction: A meta-analysis of 5182 patients. *Am J Sports Med*. 2013 Oct;41(10):2439-2448.

24. Biau DJ, Tournoux C, Katsahian S, Schranz PJ, Nizard RS. Bone-patellar tendon-bone autografts versus hamstring autografts for reconstruction of anterior cruciate ligament: Meta-analysis. *BMJ*. 2006;332(7548):995-1001.
25. van der List JP, DiFelice GS. Range of motion and complications following primary repair versus reconstruction of the anterior cruciate ligament. *Knee*. 2017 Aug;24(4):798-807.
26. Hohmann E. Editorial commentary: Renaissance of primary anterior cruciate ligament repair: Is history repeating itself? *Arthroscopy*. 2016;32(12):2570-2571.
27. Reider B. The quest. *Am J Sports Med*. 2013 Aug;41(8):1747-1749.
28. Meuffels DE, Poldervaart MT, Diercks RL, Fievez AW, Patt TW, Hart CP, Hammacher ER, Meer F, Goedhart EA, Lenssen AF, Muller-Ploeger SB, Pols MA, Saris DB. Guideline on anterior cruciate ligament injury. *Acta Orthop*. 2012 Aug;83(4):379-386.
29. Frobell RB, Roos EM, Roos HP, Ranstam J, Lohmander LS. A randomized trial of treatment for acute anterior cruciate ligament tears. *N Engl J Med*. 2010;363(4):331-342.
30. DiFelice GS, Villegas C, Taylor SA. Anterior cruciate ligament preservation: Early results of a novel arthroscopic technique for suture anchor primary anterior cruciate ligament repair. *Arthroscopy*. 2015;31(11):2162-2171.
31. Achtnich A, Herbst E, Forkel P, Metzloff S, Sprenger F, Imhoff AB, Petersen W. Acute proximal anterior cruciate ligament tears: Outcomes after arthroscopic suture anchor repair versus anatomic single-bundle reconstruction. *Arthroscopy*. 2016 Dec;32(12):2562-2569.
32. Hoffmann C, Friederichs J, von Ruden C, Schaller C, Bühren V, Moessmer C. Primary single suture anchor re-fixation of anterior cruciate ligament proximal avulsion tears leads to good functional mid-term results: A preliminary study in 12 patients. *J Orthop Surg Res*. 2017 Nov 13;12(1):171.
33. DiFelice GS, van der List JP. Clinical outcomes of arthroscopic primary repair of proximal anterior cruciate ligament tears are maintained at mid-term follow-up. *Arthroscopy*. 2018;34(4):1085-1093.
34. Heusdens CHW, Hopper GP, Dossche L, Roelant E, Mackay GM. Anterior cruciate ligament repair with independent suture tape reinforcement: A case series with 2-year follow-up. *Knee Surg Sports Traumatol Arthrosc*. 2018;27(1):60-67.
35. Mukhopadhyay R, Shah N, Vakta R, Bhatt J. Acl femoral avulsion repair using suture pull-out technique: A case series of thirteen patients. *Chin J Traumatol*. 2018;21(6):352-355.
36. Bieri KS, Scholz SM, Kohl S, Aghayev E, Staub LP. Dynamic intraligamentary stabilization versus conventional acl reconstruction: A matched study on return to work. *Injury*. 2017 Jun;48(6):1243-1248.
37. Schliemann B, Glasbrenner J, Rosenbaum D, Lammers K, Herbort M, Domnick C, Raschke MJ, Kösters C. Changes in gait pattern and early functional results after acl repair are comparable to those of acl reconstruction. *Knee Surg Sports Traumatol Arthrosc*. 2018;26(2):374-380.
38. Bigoni M, Gaddi D, Gorla M, Munegato D, Pungitore M, Piatti M, Turati M. Arthroscopic anterior cruciate ligament repair for proximal anterior cruciate ligament tears in skeletally immature patients: Surgical technique and preliminary results. *Knee*. 2017 Jan;24(1):40-48.
39. Smith JO, Yasen SK, Palmer HC, Lord BR, Britton EM, Wilson AJ. Paediatric acl repair reinforced with temporary internal bracing. *Knee Surg Sports Traumatol Arthrosc*. 2016;24(6):1845-1851.
40. Gagliardi AG, Carry PM, Parikh HB, Traver JL, Howell DR, Albright JC. Acl repair with suture ligament augmentation is associated with a high failure rate among adolescent patients. *Am J Sports Med*. 2019 Mar;47(3):560-566.
41. Ateschrang A, Ahrend MD, Dobeles S, Ihle C, Stockle U, Schroter S. Does acl repair with dynamic intraligamentary stabilization show similar objective short-term outcomes to the acl reconstruction? *Knee*. 2017;24(6):1508.
42. Hennings J. Primary anatomical repair of proximal acl ruptures with suture anchors: 1 year follow-up. Presented at Annual Meeting of the DKG. 2018.
43. Bucci G, Begg M, Pillifant K, Singleton SB. Primary acl repair vs reconstruction: Investigating the current conventional wisdom. Presented at 12th Biannual Meeting of the Sociedad Espanola de Traumatologia del Deporte. 2018.
44. Caborn DN, Nyland J, Wheeldon B, Kalloub A. Acl femoral avulsion reapproximation with internal bracing and prp augmentation: Excellent return to sports outcomes and low re-injury rates at 3 year follow-up. Presented at Annual Meeting of the European Society of Sports Traumatology, Knee Surgery and Arthroscopy; . 2018.

45. Mackay GM, Blyth MJ, Anthony I, Hopper GP, Ribbans WJ. A review of ligament augmentation with the internal brace: The surgical principle is described for the lateral ankle ligament and acl repair in particular, and a comprehensive review of other surgical applications and techniques is presented. *Surg Technol Int*. 2015 May;26:239-255.
46. Mackay G, Anthony IC, Jenkins PJ, Blyth MJ. Anterior cruciate ligament repair revisited. Preliminary results of primary repair with internal brace ligament augmentation: A case series. *Orthop Muscular Syst*. 2015;4(2):1000188.
47. Ateschrang A, Schreiner AJ, Ahmad SS, Schroter S, Hirschmann MT, Korner D, Kohl S, Stockle U, Ahrend MD. Improved results of acl primary repair in one-part tears with intact synovial coverage. *Knee Surg Sports Traumatol Arthrosc*. 2019 Oct 8;27(1):37-43.
48. Eggli S, Kohlhof H, Zumstein M, Henle P, Hartel M, Evangelopoulos DS, Bonel H, Kohl S. Dynamic intraligamentary stabilization: Novel technique for preserving the ruptured acl. *Knee Surg Sports Traumatol Arthrosc*. 2015 Apr;23(4):1215-1221.
49. Eggli S, Roder C, Perler G, Henle P. Five year results of the first ten acl patients treated with dynamic intraligamentary stabilisation. *BMC Musculoskelet Disord*. 2016 Feb 27;17:105.
50. Henle P, Bieri KS, Brand M, Aghayev E, Bettfuehr J, Haeberli J, Kess M, Eggli S. Patient and surgical characteristics that affect revision risk in dynamic intraligamentary stabilization of the anterior cruciate ligament. *Knee Surg Sports Traumatol Arthrosc*. 2018 Apr;26(4):1182-1189.
51. Henle P, Roder C, Perler G, Heitkemper S, Eggli S. Dynamic intraligamentary stabilization (dis) for treatment of acute anterior cruciate ligament ruptures: Case series experience of the first three years. *BMC Musculoskelet Disord*. 2015 Feb 13;16:27.
52. Wright JG, Swiontkowski MF, Heckman JD. Introducing levels of evidence to the journal. *J Bone Joint Surg Am*. 2003 Jan;85-A(1):1-3.
53. Slim K, Nini E, Forestier D, Kwiatkowski F, Panis Y, Chipponi J. Methodological index for non-randomized studies (minors): Development and validation of a new instrument. *ANZ J Surg*. 2003 Sep;73(9):712-716.
54. Atkins D, Best D, Briss PA, Eccles M, Falck-Ytter Y, Flottorp S, Guyatt GH, Harbour RT, Haugh MC, Henry D, Hill S, Jaeschke R, Leng G, Liberati A, Magrini N, Mason J, Middleton P, Mrukowicz J, O'Connell D, Oxman AD, Phillips B, Schünemann HJ, Edejer TT-T, Varonen H, Vist GE, Williams JW, Jr., Zaza S, Group GW. Grading quality of evidence and strength of recommendations. *BMJ (Clinical research ed)*. 2004;328(7454):1490-1490.
55. Hefti F, Muller W, Jakob RP, Staubli HU. Evaluation of knee ligament injuries with the ikdc form. *Knee Surg Sports Traumatol Arthrosc*. 1993;1(3-4):226-234.
56. Tegner Y, Lysholm J. Rating systems in the evaluation of knee ligament injuries. *Clin Orthop Relat Res*. 1985;198:43-49.
57. Briggs KK, Lysholm J, Tegner Y, Rodkey WG, Kocher MS, Steadman JR. The reliability, validity, and responsiveness of the lysholm score and tegner activity scale for anterior cruciate ligament injuries of the knee: 25 years later. *Am J Sports Med*. 2009 May;37(5):890-897.
58. Noyes FR, Barber SD, Moar LA. A rationale for assessing sports activity levels and limitations in knee disorders. *Clin Orthop Relat Res*. 1989;246:238-249.
59. Shelbourne KD, Barnes AF, Gray T. Correlation of a single assessment numeric evaluation (sane) rating with modified cincinnati knee rating system and ikdc subjective total scores for patients after acl reconstruction or knee arthroscopy. *Am J Sports Med*. 2012;40(11):2487-2491.
60. Collins NJ, Prinsen CA, Christensen R, Bartels EM, Terwee CB, Roos EM. Knee injury and osteoarthritis outcome score (koos): Systematic review and meta-analysis of measurement properties. *Osteoarthritis Cartilage*. 2016 Aug;24(8):1317-1329.
61. Williams GN, Taylor DC, Gangel TJ, Uhorchak JM, Arciero RA. Comparison of the single assessment numeric evaluation method and the lysholm score. *Clin Orthop Relat Res*. 2000;373:184-192.
62. Walter SD, Yao X. Effect sizes can be calculated for studies reporting ranges for outcome variables in systematic reviews. *J Clin Epidemiol*. 2007 Aug;60(8):849-852.
63. Hozo SP, Djulbegovic B, Hozo I. Estimating the mean and variance from the median, range, and the size of a sample. *BMC Med Res Methodol*. 2005 Apr 20;5:13.
64. Higgins JP, Green S. *Cochrane handbook for systematic reviews of interventions*.

65. Ateschrang A, Ahmad SS, Stockle U, Schroeter S, Schenk W, Ahrend MD. Recovery of acl function after dynamic intraligamentary stabilization is resultant to restoration of acl integrity and scar tissue formation. *Knee Surg Sports Traumatol Arthrosc.* 2018 Feb;26(2):589-595.
66. Büchler L, Regli D, Evangelopoulos DS, Bieri K, Ahmad SS, Krismer A, Muller T, Kohl S. Functional recovery following primary acl repair with dynamic intraligamentary stabilization. *Knee.* 2016;23(3):549-553.
67. Häberli J, Jaberg L, Bieri K, Eggli S, Henle P. Reinterventions after dynamic intraligamentary stabilization in primary anterior cruciate ligament repair. *Knee.* 2018;25(2):271-278.
68. Hoogeslag RAG, Brouwer RW, Boer BC, de Vries AJ, Huis In 't Veld R. Acute anterior cruciate ligament rupture: Repair or reconstruction? Two-year results of a randomized controlled clinical trial. *Am J Sports Med.* 2019 Mar;47(3):567-577.
69. Kohl S, Evangelopoulos DS, Schar MO, Bieri K, Muller T, Ahmad SS. Dynamic intraligamentary stabilisation: Initial experience with treatment of acute acl ruptures. *Bone Joint J.* 2016 Jun;98-b(6):793-798.
70. Meister M, Koch J, Amsler F, Arnold MP, Hirschmann MT. Acl suturing using dynamic intraligamentary stabilisation showing good clinical outcome but a high reoperation rate: A retrospective independent study. *Knee Surg Sports Traumatol Arthrosc.* 2018 Feb;26(2):655-659.
71. Osti M, El Attal R, Doskar W, Hock P, Smekal V. High complication rate following dynamic intraligamentary stabilization for primary repair of the anterior cruciate ligament. *Knee Surg Sports Traumatol Arthrosc.* 2019;27(1):29-36.
72. Jonkergouw A, van der List JP, DiFelice GS. Arthroscopic primary repair of proximal anterior cruciate ligament tears: Outcomes of the first 56 consecutive patients and the role of additional internal bracing. *Knee Surg Sports Traumatol Arthrosc.* 2018;27(1):21-28.
73. Evangelopoulos DS, Kohl S, Schwienbacher S, Gantenbein B, Exadaktylos A, Ahmad SS. Collagen application reduces complication rates of mid-substance acl tears treated with dynamic intraligamentary stabilization. *Knee Surg Sports Traumatol Arthrosc.* 2017 Aug;25(8):2414-2419.
74. Lind M, Menhert F, Pedersen AB. The first results from the danish acl reconstruction registry: Epidemiologic and 2 year follow-up results from 5,818 knee ligament reconstructions. *Knee Surg Sports Traumatol Arthrosc.* 2008;17(2):117-124.
75. Wiggins AJ, Grandhi RK, Schneider DK, Stanfield D, Webster KE, Myer GD. Risk of secondary injury in younger athletes after anterior cruciate ligament reconstruction: A systematic review and meta-analysis. *Am J Sports Med.* 2016;44(7):1861-1876.
76. Xie X, Liu X, Chen Z, Yu Y, Peng S, Li Q. A meta-analysis of bone-patellar tendon-bone autograft versus four-strand hamstring tendon autograft for anterior cruciate ligament reconstruction. *Knee.* 2015 Mar;22(2):100-110.
77. Lefevre N, Klouche S, Mirouse G, Herman S, Gerometta A, Bohu Y. Return to sport after primary and revision anterior cruciate ligament reconstruction. *Am J Sports Med.* 2017 Jan;45(1):34-41.
78. Murray MM, Martin SD, Martin TL, Spector M. Histological changes in the human anterior cruciate ligament after rupture. *J Bone Joint Surg Am.* 2000 Oct;82-A(10):1387-1397.
79. O'Donoghue DH. Surgical treatment of fresh injuries to the major ligaments of the knee. *J Bone Joint Surg Am.* 1950;32 A(4):721-738.
80. O'Donoghue DH. An analysis of end results of surgical treatment of major injuries to the ligaments of the knee. *J Bone Joint Surg Am.* 1955;37(1):1-13.
81. Sanders TL, Kremers HM, Bryan AJ, Fruth KM, Larson DR, Pareek A, Levy BA, Stuart MJ, Dahm DL, Krych AJ. Is anterior cruciate ligament reconstruction effective in preventing secondary meniscal tears and osteoarthritis? *Am J Sports Med.* 2016 Jul;44(7):1699-1707.
82. Herbst E, Hoser C, Gfoller P, Heppinger C, Abermann E, Neumayer K, Musahl V, Fink C. Impact of surgical timing on the outcome of anterior cruciate ligament reconstruction. *Knee Surg Sports Traumatol Arthrosc.* 2017 Feb;25(2):569-577.
83. Jarvela S, Kiekara T, Suomalainen P, Jarvela T. Double-bundle versus single-bundle anterior cruciate ligament reconstruction: A prospective randomized study with 10-year results. *Am J Sports Med.* 2017 Sep;45(11):2578-2585.

84. Magnussen RA, Mansour AA, Carey JL, Spindler KP. Meniscus status at anterior cruciate ligament reconstruction associated with radiographic signs of osteoarthritis at 5- to 10-year follow-up: A systematic review. *J Knee Surg.* 2009 Oct;22(4):347-357.
85. Shelbourne KD, Benner RW, Gray T. Results of anterior cruciate ligament reconstruction with patellar tendon autografts: Objective factors associated with the development of osteoarthritis at 20 to 33 years after surgery. *Am J Sports Med.* 2017 Oct;45(12):2730-2738.
86. Van der List JP, Mintz DN, DiFelice GS. The locations of anterior cruciate ligament tears in pediatric and adolescent patients: A magnetic resonance study. *J Pediatr Orthop.* 2017 Aug 2.
87. Van der List JP, Mintz DN, DiFelice GS. The location of anterior cruciate ligament tears: A prevalence study using magnetic resonance imaging. *Orthop J Sports Med.* 2017 Jun;5(6):2325967117709966.



# Chapter 10

## **Arthroscopic primary repair of proximal anterior cruciate ligament tears: outcomes of the first 56 consecutive patients and the role of additional internal bracing**

Anne Jonkergouw

Jelle P. van der List

Gregory S. DiFelice

*Knee Surg Sports Traumatol Arthrosc.* 2019 Jan;27(1):21-28.

## **Abstract**

### **Purpose**

Recent outcomes of arthroscopic primary repair of proximal anterior cruciate ligament (ACL) tears have been promising in small cohort studies. The purpose of this study was to assess outcomes of arthroscopic ACL repair in a larger cohort and to assess the role of additional augmentation.

### **Methods**

The first 56 consecutive patients that underwent arthroscopic ACL repair were examined at minimum two-year follow-up. The latter 27 patients (48.2%) received additional internal bracing with ACL repair. All 56 patients were included (100% follow-up). Mean age at surgery was  $33.5 \pm 1.3$  years (59% male) and mean follow-up  $3.2 \pm 1.7$  years.

Clinical examination was performed using the objective International Knee Documentation Committee (IKDC) form. Subjective outcomes were obtained using the Lysholm, modified Cincinnati, Single Assessment Numeric Evaluation (SANE), and subjective IKDC scores.

### **Results**

Six repairs (10.7%) failed and four additional patients underwent reoperation (7.1%); two for meniscus tears and two for suture anchor irritation. Objective IKDC scores were A in 38 (73%), B in 8 (15%) and C/D in 6 (12%) patients. Mean Lysholm score was  $94 \pm 7.6$ , modified Cincinnati  $94 \pm 8.9$ , SANE  $90 \pm 12.5$ , pre-injury Tegner  $6.7 \pm 1.5$ , current Tegner  $6.2 \pm 1.5$ , and subjective IKDC  $90 \pm 10.9$ . Failure rates were 7.4% with and 13.8% without internal bracing ( $p=0.672$ ). There were no statistically significant or clinically relevant differences in subjective outcomes.

### **Conclusions**

Arthroscopic primary repair has resulted in good objective and subjective outcomes at 3.2 years follow-up in a carefully selected population. The role of additional internal bracing is possibly beneficial, but larger groups are needed to assess this.

### **Level of Evidence**

Level III

## Introduction

Primary repair of anterior cruciate ligament (ACL) tears was the standard of care for all ACL tears until the early 1990s but fell out of favor due to disappointing mid-term follow-up outcomes.<sup>1-5</sup> Recently, there has been a renewed interest in primary repair due to several factors. First of all, recent research has shown that primary repair should only be performed in proximal tears due to better vascularity<sup>6</sup> and good healing potential<sup>7</sup> and outcomes of primary repair are indeed better in proximal tears compared to midsubstance tears in both historical<sup>4</sup> and modern-day studies<sup>8,9</sup>. Second, minimal invasive arthroscopy techniques are available nowadays with early rehabilitation that were both not available or commonly used during the open repair era.<sup>1-3</sup> Finally, researchers and surgeons have been pursuing the concept of primary repair because of the (potential) advantages: the ligament is preserved with its proprioception, graft site morbidity can be prevented,<sup>10, 11</sup> revision surgery is similar to primary reconstruction which is not the case with reconstruction surgery,<sup>12-14</sup> and it may potentially decrease the incidence of osteoarthritis.<sup>15,16</sup>

Subsequently, several studies have reported excellent outcomes using primary ACL repair in predominantly small case series over the last five years with various techniques. In these studies, excellent outcomes of arthroscopically reattaching proximally avulsed ACLs back to the femoral footprint have been reported using suture anchors<sup>17-21</sup> or transosseous tunnels<sup>22-24</sup>. Furthermore, some groups have also advocated augmenting the primary repair construct by either internal suture augmentation<sup>23,24</sup> or dynamic intraligamentary stabilization<sup>9,25-28</sup>. The rationale of this augmentation is to provide additional stability to the repaired ligament and protect its healing during early mobilization.<sup>1,23,24,29</sup> The clinical benefits of internal bracing have not yet been assessed, although preclinical studies have shown improved healing and biomechanical properties of the ACL by adding a mechanical augmentation to a repaired ACL.<sup>30-32</sup>

The purpose of this study was (I) to evaluate the outcomes of arthroscopic ACL repair in a larger cohort and (II) to assess the role of additional suture augmentation on the outcomes. It was hypothesized that arthroscopic ACL repair would lead to good knee stability and subjective outcomes at final follow-up, regardless of additional internal bracing.

## Methods

### Patient selection

In this retrospective study, approval from the Institutional Review Board was obtained to search the database of the senior author for all surgically treated patients with isolated complete ACL tears between December 2008 and June 2016. A total of 190 patients were operated of which 134 were treated with ACL reconstruction due to midsubstance tears or insufficient tissue quality. A total of 56 (29%) patients were treated with arthroscopic primary ACL repair and all of these patients could be included (100%) with minimum two-year follow-up. This study therefore consisted of the first 56 consecutive patients with complete isolated proximal ACL tears that were treated with arthroscopic primary ACL repair.

### Patient demographics

Fifty-two patients (92.9%) were seen in clinic and four (7.1%) provided information and patient-reported outcomes by email at a mean follow-up of  $3.2 \pm 1.7$  years (range: 2 – 9). Mean age at surgery was  $33.5 \pm 11.3$  years (range: 14 – 57) and BMI was  $25 \text{ kg/m}^2$  (range: 19 – 35) (Table 1). Twenty-three patients (41.1%) had meniscal injury and 16 (28.6%) chondral injury. The most common mechanisms of injury were skiing (25.5%), basketball (16.4%) and soccer injuries (9.1%). Mean time to surgery was 203 days after injury (range: 5 days – 11 years). Twenty-four patients (42.9%) with excellent tissue quality were treated greater than 6 weeks from injury.

**Table 1.** Patient demographics of ACL Repair and ACL Repair with additional internal bracing

	Entire cohort (N = 56)	ACL Repair (N = 29)	ACL Repair + IB (N = 27)	P-value
Age (years); mean $\pm$ SD	$33.5 \pm 11.3$	$37.0 \pm 11.3$	$29.6 \pm 10.1$	0.013
Male; N (%)	33 (58.9%)	18 (62.1%)	15 (55.6%)	0.621
BMI ( $\text{kg/m}^2$ ); mean $\pm$ SD	$25.2 \pm 3.8$	$25.8 \pm 4.1$	$24.6 \pm 3.3$	0.323
Concomitant injury; N (%)				
MM injury	11 (19.6%)	5 (17.9%)	6 (22.2%)	0.865
LM injury	14 (25.0%)	6 (21.4%)	8 (29.6%)	0.440
Chondral injury	16 (28.6%)	10 (35.7%)	6 (22.2%)	0.201
Time to surgery (days); median (range)	35 (5 – 4018)	38 (9 – 4018)	26 (5 – 155)	0.201

ACL indicates anterior cruciate ligament; SD, standard deviation; BMI, body mass index; MM, medial meniscus; LM, lateral meniscus

## **Study protocol**

Each patient was contacted and invited for evaluation of outcomes. First, it was assessed if failure (symptomatic instability or rerupture) or reoperation had occurred and the surgeon scored the International Knee Documentation Committee (IKDC) Objective Score. Then, patient-reported outcome scores were collected, consisting of the Lysholm Knee Score<sup>33,34</sup>, modified Cincinnati Score<sup>35,36</sup>, Single Assessment Numeric Evaluation (SANE)<sup>34,36</sup>, preinjury and current Tegner Activity Scales<sup>37</sup>, and IKDC Subjective Score<sup>38</sup>. In case no visit could be planned, patients were asked if they underwent subsequent surgeries or experienced recurrent instability and to provide patient-reported outcomes by email. In addition, the medical records of all patients were reviewed to record demographics, injury patterns, details of the operative procedure and postoperative rehabilitation.

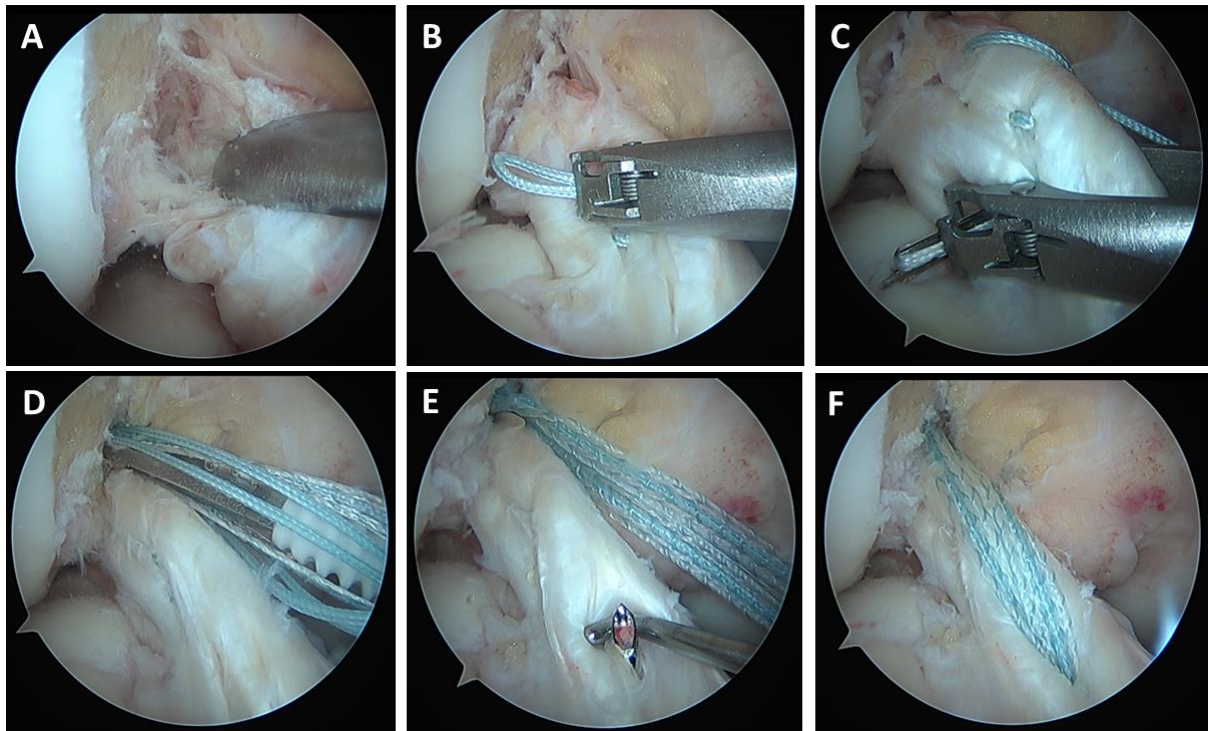
## **Surgical technique**

All surgeries were performed by the senior author (GSD). Arthroscopic primary repair was selectively performed in patients with a proximal ACL tear that had sufficient distal remnant length and tissue quality to reapproximate the remnant to the femoral footprint. The technique of ACL repair with internal bracing has been previously described in detail.<sup>29,39</sup> In brief, the anteromedial (AM) and posterolateral bundle were each sutured in a Bunnell-type pattern from distal to proximal, using No. 2 FiberWire and TigerWire sutures (Arthrex, Naples, FL), respectively (Figure 1). Each bundle was then reapproximated to its footprint using a BioComposite SwiveLock suture anchor (Arthrex). Prior to fixation, the footprint and notch were roughened with a shaver to induce a local healing response.

In the latter 27 of 56 patients, a 2-mm wide InternalBrace (Arthrex) was added to the ACL repair. The AM suture anchor was preloaded with this InternalBrace, which was channeled through a tunnel in the tibia that was drilled using an ACL DrillGuide (Arthrex). The InternalBrace exited the anteromedial tibial cortex and was fixed using a BioComposite SwiveLock suture anchor after cycling the knee and tensioning in near full extension.

## **Postoperative rehabilitation**

Postoperatively, all patients wore a hinged brace. At first, weightbearing was allowed with the brace locked in extension, until quadriceps muscle control had been regained (examined at approximately 4 weeks postoperatively). In cases where meniscal repair had been performed, patients were restricted to partial weightbearing and flexion to a maximum of 90° for six weeks. In general, formal physical therapy was started after four weeks. Patients were seen at one week, one month, three months, and six months post-operatively, during which it was reviewed if patients were ready for return to sports using examination of quadriceps muscle strength, rehabilitation milestones and confidence to return to sports.



**Figure 1.** Arthroscopic view of a right knee, viewed from the anterolateral portal, with the patient supine and the knee at 90° of flexion. (A) A proximal avulsion tear of the anterior cruciate ligament (ACL) is being confirmed by using a probe to displace the ligament from the femoral footprint. (B) The anteromedial (AM) ACL bundle is sutured with locking stitches of No. 2 FiberWire using a Scorpion suture passer. (C) The posterolateral (PL) ACL bundle is subsequently sutured with a No. 2 TigerWire. (D) A 4.75-mm Vented BioComposite SwiveLock suture anchor that is preloaded with FiberTape is deployed into the femur at the footprint of the AM bundle. The PL bundle has been reattached with an unloaded suture anchor. (E) A Straight Microsuture Lasso is being inserted through a 2.4-mm tunnel through the tibia from the anteromedial cortex into the anterior half of the tibial ACL insertion. (F) The FiberTape is shuttled along the repaired ACL and down through the tibia where it is fixed at the cortex using a suture anchor.

### Statistical analysis

Statistical analyses were performed using SPSS 24.0 software (IBM Corporation, Armonk, NY). Continuous variables were described with means  $\pm$  standard deviations (SDs) and their ranges or medians with ranges (if not normally distributed), and nominal variables were described with frequencies (%). Outcomes of subgroups were compared, using independent t-tests for continuous variables and chi-squared tests or Fisher exact tests (for samples with a value  $<5$  in the contingency table) for nominal data. All tests were two-sided and a difference of  $P < 0.05$  was considered statistically significant.

## Results

### Baseline characteristics

Treatment consisted of arthroscopic ACL repair for the first 29 patients (51.8%) and arthroscopic ACL repair with additional internal bracing for the latter 27 patients (48.2%). There were no significant differences in injury pattern (meniscal and chondral injuries) and time to surgery between ACL repairs with and without internal bracing (Table 1). Patients undergoing ACL repair without additional internal bracing were older than patients with additional internal bracing ( $37.0\pm 2.1$  vs.  $29.6\pm 10.0$  years;  $P=0.013$ ) due to more restricted patient selection at the start of this procedure and had longer follow-up ( $4.0\pm 2.0$  years vs  $2.4\pm 0.7$  years vs;  $P=0.001$ ).

### Objective outcomes

At final follow-up, six ACL repairs (10.7%) had failed at a mean time of 1.0 years (range: 6 – 17 months) after surgery (Table 2). Each failure was caused by re-injury. Subsequently, four failed ACL repairs were treated with an uncomplicated ACL reconstruction and two were treated conservatively. Furthermore, four additional patients (7.1%) underwent a subsequent surgery; two for a medial meniscus tear and two for tibial suture anchor removal (Table 2). There was no statistical significant difference in failure rate ( $P = 0.672$ ) between ACL repair with (2/27; 7.4%) and without (4/29; 13.8%) additional internal bracing or in reoperation rate ( $P > 0.999$ ) between these groups (2/27 (7.4%) vs. 2/29 (6.9%), respectively). In addition, no effect of age or time to surgery on clinical success was found. Objective IKDC scores of the 52 examined patients were A in 38 (73%), B in 8 (15%) and C/D in 6 (12%) patients and these did not differ between both groups.

**Table 2.** Subsequent treatments following primary ACL repair

		Initial treatment	Mechanism	Timing (years)	Subsequent treatment
ACL re-tear	#1	ACL Repair	Stair-climbing injury	0.6	Conservative
	#2	ACL Repair	Fall	0.9	Conservative
	#3	ACL Repair	Soccer injury	0.8	ACL recon.
	#4	ACL Repair	Rugby injury	1.1	ACL recon.
	#5	ACL Repair + IB	Soccer injury	1.4	ACL recon.
	#6	ACL Repair + IB	Gymnastics injury	1.1	ACL recon.
Meniscus injury	#1	ACL Repair	Football injury	2.8	Meniscectomy
	#2	ACL Repair	Soccer injury	3.3	Repair
Hardware irrit.	#1	ACL Repair + IB	Tibial anchor	1.4	Partial removal
	#2	ACL Repair + IB	Tibial anchor	1.6	Partial removal

IB indicates internal brace; MM, medial meniscus; hardware irrit., hardware irritation

### Patient-reported outcomes

The mean patient-reported outcomes of the entire cohort were a Lysholm of  $94 \pm 7.6$  (range: 68-100), modified Cincinnati of  $94 \pm 8.9$  (range: 59-100), SANE of  $90 \pm 12.5$  (range: 40-100), and subjective IKDC of  $90 \pm 10.9$  (range: 60-100) (Table 3). Tegner activity level changed from  $6.7 \pm 1.5$  (range: 3-10) pre-injury to  $6.2 \pm 1.5$  (range: 3-9) at follow-up. The subjective scores did not significantly differ between ACL repair with and without internal bracing (Table 3).

**Table 3.** Patient-Reported Outcomes after Successful ACL Repair in 50 Patients at 3.2 Years Follow-Up

	Entire Cohort (N = 50)	ACL Repair (N = 25)	ACL Repair +IB (N = 25)	P-value
Lysholm; mn $\pm$ SD	$94.2 \pm 7.6$	$95.2 \pm 7.4$	$93.0 \pm 7.9$	0.324
Modified Cincinnati; mn $\pm$ SD	$93.5 \pm 8.9$	$94.1 \pm 8.3$	$92.9 \pm 9.5$	0.654
SANE; mn $\pm$ SD	$89.7 \pm 12.5$	$89.3 \pm 14.5$	$90.0 \pm 10.2$	0.844
Tegner pre-injury; mn $\pm$ SD	$6.7 \pm 1.5$	$6.4 \pm 1.4$	$7.0 \pm 1.6$	0.166
Tegner currently; mn $\pm$ SD	$6.2 \pm 1.5$	$6.0 \pm 1.3$	$6.4 \pm 1.7$	0.483
Subjective IKDC; mn $\pm$ SD	$90.0 \pm 10.9$	$90.6 \pm 12.1$	$89.4 \pm 9.6$	0.699

ACL indicates anterior cruciate ligament; Mn, mean; SANE, Single Assessment Numeric Evaluation; IKDC, International Knee Documentation Committee; SD, standard deviation; IB, internal brace augmentation



## Discussion

The most important findings of the present study were that the good short-term clinical outcomes of ACL repair were achieved using arthroscopic ACL repair on selected patients with proximal ACL tears and that no differences in complication rate, reoperation rate, or patient-reported outcomes were found between ACL repair with and without additional internal augmentation. In this study, 48 of the 54 examined patients (88.9%) had stable knees, and 50 of 56 patients (89.3%) reported excellent subjective outcomes at a mean of 3.2 years follow-up. At final follow-up, six ACL repairs (10.7%) had failed and four additional patients (7.1%) required a subsequent surgery for painful hardware or meniscal injury.

This study reported on a large cohort of patients that have undergone modern arthroscopic ACL repair followed by early rehabilitation in the literature. Previous recent studies, consisting of smaller cohorts and with variable ACL repair techniques, showed results similar to the current study.<sup>19-23</sup> Achtnich et al. reported a 15% failure rate out of 20 ACL repairs at 28 months (2.3 years) follow-up, using one suture anchor for ACL fixation at the femoral footprint.<sup>19</sup> They noted that failures were associated with noncompliance with the rehabilitation protocol. Hoffmann et al. also used an ACL repair technique with one suture anchor and reported that 25% of 12 patients had failed or suffered from residual laxity at mean follow-up of 79 months (6.6 years).<sup>21</sup> As no re-injuries were noted, they assumed that the ACLs did not heal properly in these cases. Furthermore, Bigoni et al.<sup>20</sup> and Smith et al.<sup>24</sup> reported no failures of ACL repairs in five and three pediatric patients, respectively. More historical studies have described ACL repairs using open techniques and subsequent knee immobilization and are therefore less comparable to the current outcomes.

Comparing ACL repair with and without additional internal bracing, this study failed to show a clinical benefit of additional internal bracing to primary ACL repair. However, it should be noted that this comparison was underpowered, and it is possible that failure rates will be different in a larger cohort of patients, although the follow-up in the internal bracing group was shorter. Preclinical studies have shown superior biomechanical results when adding an internal brace (often described as suture augmentation).<sup>1,31,40</sup>

Recently, Van Heusden et al. reported excellent outcomes of primary repair with additional internal bracing in 42 patients with 4.8% failures at 2-year follow-up.<sup>23</sup> Heitmann et al. tested different types of suture augmentation and showed higher load-to-failure of augmented ACL repairs (464 – 624 N) compared with ACL repairs without augmentation (177 N) and with ACL reconstructions with hamstring tendons (362 N).<sup>40</sup> Seitz et al. showed significantly higher stiffness, tensile strength and less anteroposterior laxity of augmented ACLs.<sup>31</sup> Similarly, Murray et al. reported that additional stabilization between the tibia and femur improves structural properties of ACL repairs.<sup>32</sup> However, no clinical data is available to suggest functional benefits of additional internal bracing.

Importantly, two patients reported hardware irritation at the tibial cortex from the suture anchor used for internal brace fixation, who required additional surgery for removal of this hardware. To prevent such irritation, the tibial suture anchor was deployed at least as deep as the cortex and no further cases of hardware irritation occurred. Overall, implementation of an internal brace seems safe and no failures were related to the hardware, although no clinical benefits were suggested. As a result, the senior author now selectively performs additional internal bracing in patients at high-risk for failure, including those of young age, with generalized hyperlaxity, of younger female patients or those competing in high-level pivoting sports. It could be argued that internal bracing should be included on all repairs in light of the minimal complications that have been encountered, while not factoring in costs. Larger studies with more power will be needed to answer this question.

When comparing outcomes of ACL repair with ACL reconstruction in the literature, the failure rates of ACL repair in this study are similar to slightly higher than ACL reconstruction outcomes. However, ACL reconstruction can be associated with significant postoperative quadriceps muscle weakness and knee stiffness, which require a strenuous and time-consuming rehabilitation program.<sup>41</sup> A previous study by our group found that patients have greater postoperative range of motion after ACL repair than ACL reconstruction at one week (89° vs. 61°) and at one month (125° vs. 116°), in addition to fewer complications and a shorter operation time.<sup>42</sup> Although good knee stability is generally achieved with ACL reconstruction, recent studies have noted that return-to-sport activity rates after ACL reconstruction are not as high as expected, and that development of long-term osteoarthritis is a significant risk.<sup>43-45</sup> There is preclinical data that suggests that ACL repair results in a lower risk of osteoarthritis than both reconstruction and conservative treatment.<sup>15</sup> Considering the less invasive nature of ACL repair, future studies are needed to assess if ACL repair might also lead to a lower incidence of long-term osteoarthritis in humans.

Limitations exist in this study. Despite the relative large cohort of patients evaluated, this study is a retrospective study and is subject to selection bias although this risk is decreased within the cohort because consecutive patients were included without any lost to follow-up. Furthermore, the comparison of outcomes of ACL repair with and without additional internal bracing is underpowered and it is therefore possible that the failure rate of primary repair with additional augmentation may be lower than primary repair without augmentation. However, this study shows that, in general, arthroscopic ACL repair is safe regardless of internal bracing, with an acceptable failure rate and excellent functional outcomes. In addition, the age of patients varied between the treatment groups with and without internal bracing, with younger patients in the group with additional internal bracing. Since younger age is potentially associated with inferior results, as seen after ACL reconstruction, this factor could have suppressed actual differences in outcomes between the treatment groups, although on the contrary, the group with additional internal bracing was treated when the surgeon had more experience with ACL repair. Finally, no objective KT-1000 laxity measurements were performed in this study. Several studies have previously showed that

good stability can be achieved with primary ACL repair as measured on KT-1000 laxity.<sup>18-22,25,46-48</sup> These limitations support neither the use or abandonment of internal bracing. Studies matched by age and gender will be needed to better assess failure rates and outcomes between both groups, as well as studies reporting outcomes in a prospective design and comparing the outcomes with reconstruction and conservative treatment.

## **Conclusion**

Arthroscopic primary repair has resulted in good objective and patient-reported outcomes at 3.2 years follow-up in a carefully selected patient population of proximal tears and sufficient tissue quality. The role of additional internal bracing is possibly beneficial, but larger groups of patients are needed to assess this.

## **Disclosures**

Gregory S. DiFelice is a paid consultant for Arthrex and receives research funding from Arthrex, and Jelle P. van der List is a paid consultant for Arthrex. Anne Jonkergouw declares no conflict of interest.

## **Ethical approval**

All procedures performed in studies involving human participants were in accordance with the ethical standards of the institutional and/or national research committee and with the 1964 Helsinki declaration and its later amendments or comparable ethical standards.

## References

1. van Eck CF, Limpisvasti O, ElAttrache NS. Is there a role for internal bracing and repair of the anterior cruciate ligament? A systematic literature review. *Am J Sports Med.* 2017;46(9):2291-2298.
2. Taylor SA, Khair MM, Roberts TR, DiFelice GS. Primary repair of the anterior cruciate ligament: A systematic review. *Arthroscopy.* 2015;31(11):2233-2247.
3. van der List JP, DiFelice GS. Primary repair of the anterior cruciate ligament: A paradigm shift. *Surgeon.* 2017;15(3):161-168.
4. van der List JP, DiFelice GS. Role of tear location on outcomes of open primary repair of the anterior cruciate ligament: A systematic review of historical studies. *Knee.* 2017;24(5):898-908.
5. Hirschmann MT, Muller W. Complex function of the knee joint: The current understanding of the knee. *Knee Surg Sports Traumatol Arthrosc.* 2015;23(10):2780-2788.
6. Toy BJ, Yeasting RA, Morse DE, McCann P. Arterial supply to the human anterior cruciate ligament. *J Athl Train.* 1995;30(2):149-152.
7. Nguyen DT, Ramwadhoebe TH, van der Hart CP, Blankevoort L, Tak PP, van Dijk CN. Intrinsic healing response of the human anterior cruciate ligament: An histological study of reattached ACL remnants. *J Orthop Res.* 2014 Feb;32(2):296-301.
8. Evangelopoulos DS, Kohl S, Schwienbacher S, Gantenbein B, Exadaktylos A, Ahmad SS. Collagen application reduces complication rates of mid-substance ACL tears treated with dynamic intraligamentary stabilization. *Knee Surg Sports Traumatol Arthrosc.* 2017 Aug;25(8):2414-2419.
9. Krismer AM, Gousopoulos L, Kohl S, Ateschrang A, Kohlhof H, Ahmad SS. Factors influencing the success of anterior cruciate ligament repair with dynamic intraligamentary stabilisation. *Knee Surg Sports Traumatol Arthrosc.* 2017;25(12):3923-3928.
10. Kraeutler MJ, Bravman JT, McCarty EC. Bone-patellar tendon-bone autograft versus allograft in outcomes of anterior cruciate ligament reconstruction: A meta-analysis of 5182 patients. *Am J Sports Med.* 2013;41(10):2439-2448.
11. Biau DJ, Tournoux C, Katsahian S, Schranz PJ, Nizard RS. Bone-patellar tendon-bone autografts versus hamstring autografts for reconstruction of anterior cruciate ligament: Meta-analysis. *BMJ.* 2006;332(7548):995-1001.
12. Lind M, Menhert F, Pedersen AB. Incidence and outcome after revision anterior cruciate ligament reconstruction: Results from the danish registry for knee ligament reconstructions. *Am J Sports Med.* 2012;40(7):1551-1557.
13. Lefevre N, Klouche S, Mirouse G, Herman S, Gerometta A, Bohu Y. Return to sport after primary and revision anterior cruciate ligament reconstruction. *Am J Sports Med.* 2017;45(1):34-41.
14. Kamath GV, Redfern JC, Greis PE, Burks RT. Revision anterior cruciate ligament reconstruction. *Am J Sports Med.* 2011;39(1):199-217.
15. Murray MM, Fleming BC. Use of a bioactive scaffold to stimulate anterior cruciate ligament healing also minimizes posttraumatic osteoarthritis after surgery. *Am J Sports Med.* 2013;41(8):1762-1770.
16. Strand T, Molster A, Hordvik M, Krukhaug Y. Long-term follow-up after primary repair of the anterior cruciate ligament: Clinical and radiological evaluation 15-23 years postoperatively. *Arch Orthop Trauma Surg.* 2005;125(4):217-221.
17. DiFelice GS, van der List JP. Clinical outcomes of arthroscopic primary repair of proximal anterior cruciate ligament tears are maintained at midterm follow-up. *Arthroscopy.* 2018;34(4):1085-1093.
18. DiFelice GS, Villegas C, Taylor SA. Anterior cruciate ligament preservation: Early results of a novel arthroscopic technique for suture anchor primary anterior cruciate ligament repair. *Arthroscopy.* 2015;31(11):2162-2171.
19. Achtnich A, Herbst E, Forkel P, Metzloff S, Sprenker F, Imhoff AB, Petersen W. Acute proximal anterior cruciate ligament tears: Outcomes after arthroscopic suture anchor repair versus anatomic single-bundle reconstruction. *Arthroscopy.* 2016;32(12):2562-2569.
20. Bigoni M, Gaddi D, Gorla M, Munegato D, Pungitore M, Piatti M, Turati M. Arthroscopic anterior cruciate ligament repair for proximal anterior cruciate ligament tears in skeletally immature patients: Surgical technique and preliminary results. *Knee.* 2017;24(1):40-48.

21. Hoffmann C, Friederichs J, von Ruden C, Schaller C, Buhren V, Moessmer C. Primary single suture anchor re-fixation of anterior cruciate ligament proximal avulsion tears leads to good functional mid-term results: A preliminary study in 12 patients. *J Orthop Surg Res.* 2017;12(1):171.
22. Mukhopadhyay R, Shah N, Vakta R, Bhatt J. ACL femoral avulsion repair using suture pull-out technique: A case series of thirteen patients. *Chin J Traumatol.* 2018.
23. Heusdens CHW, Hopper GP, Dossche L, Roelant E, Mackay GM. Anterior cruciate ligament repair with independent suture tape reinforcement: A case series with 2-year follow-up. *Knee Surg Sports Traumatol Arthrosc.* 2018. 10.1007/s00167-018-5239-1
24. Smith JO, Yasen SK, Palmer HC, Lord BR, Britton EM, Wilson AJ. Paediatric ACL repair reinforced with temporary internal bracing. *Knee Surg Sports Traumatol Arthrosc.* 2016;24(6):1845-1851.
25. Ateschrang A, Ahmad SS, Stockle U, Schroeter S, Schenk W, Ahrend MD. Recovery of ACL function after dynamic intraligamentary stabilization is resultant to restoration of ACL integrity and scar tissue formation. *Knee Surg Sports Traumatol Arthrosc.* 2018;26(2):589-595.
26. Häberli J, Jaberg L, Bieri K, Eggli S, Henle P. Reinterventions after dynamic intraligamentary stabilization in primary anterior cruciate ligament repair. *Knee.* 2018;25(2):271-278.
27. Meister M, Koch J, Amsler F, Arnold MP, Hirschmann MT. ACL suturing using dynamic intraligamentary stabilisation showing good clinical outcome but a high reoperation rate: A retrospective independent study. *Knee Surg Sports Traumatol Arthrosc.* 2018;26(2):655-659.
28. Ateschrang A, Schreiner AJ, Ahmad SS, Schroter S, Hirschmann MT, Korner D, Kohl S, Stockle U, Ahrend MD. Improved results of ACL primary repair in one-part tears with intact synovial coverage. *Knee Surg Sports Traumatol Arthrosc.* 2018. 10.1007/s00167-018-5199-5
29. van der List JP, DiFelice GS. Arthroscopic primary anterior cruciate ligament repair with suture augmentation. *Arthrosc Tech.* 2017;6(5):e1529-e1534.
30. Seitz H, Menth-Chiari WA, Lang S, Nau T. Histological evaluation of the healing potential of the anterior cruciate ligament by means of augmented and non-augmented repair: An in vivo animal study. *Knee Surg Sports Traumatol Arthrosc.* 2008;16(12):1087-1093.
31. Seitz H, Pichl W, Matzi V, Nau T. Biomechanical evaluation of augmented and nonaugmented primary repair of the anterior cruciate ligament: An in vivo animal study. *Int Orthop.* 2013;37(11):2305-2311.
32. Murray MM, Magarian E, Zurakowski D, Fleming BC. Bone-to-bone fixation enhances functional healing of the porcine anterior cruciate ligament using a collagen-platelet composite. *Arthroscopy.* 2010;26(9 Suppl):S49-57.
33. Lysholm J, Gillquist J. Evaluation of knee ligament surgery results with special emphasis on use of a scoring scale. *Am J Sports Med.* 1982;10(3):150-154.
34. Williams GN, Taylor DC, Gangel TJ, Uhorchak JM, Arciero RA. Comparison of the single assessment numeric evaluation method and the lysholm score. *Clin Orthop Relat Res.* 2000 (373):184-192.
35. Noyes FR, Barber SD, Mooar LA. A rationale for assessing sports activity levels and limitations in knee disorders. *Clin Orthop Relat Res.* 1989 (246):238-249.
36. Shelbourne KD, Barnes AF, Gray T. Correlation of a single assessment numeric evaluation (sane) rating with modified Cincinnati knee rating system and IKDC subjective total scores for patients after ACL reconstruction or knee arthroscopy. *Am J Sports Med.* 2012;40(11):2487-2491.
37. Tegner Y, Lysholm J. Rating systems in the evaluation of knee ligament injuries. *Clin Orthop Relat Res.* 1985 (198):43-49.
38. Hefti F, Muller W, Jakob RP, Staubli HU. Evaluation of knee ligament injuries with the IKDC form. *Knee Surg Sports Traumatol Arthrosc.* 1993;1(3-4):226-234.
39. DiFelice GS, van der List JP. Arthroscopic primary repair of proximal anterior cruciate ligament tears. *Arthrosc Tech.* 2016;5(5):E1057-E1061.
40. Heitmann M, Dratzidis A, Jagodzinski M, Wohlmuth P, Hurschler C, Puschel K, Giannakos A, Preiss A, Frosch KH. [Ligament bracing--augmented cruciate ligament sutures: Biomechanical studies of a new treatment concept]. *Unfallchirurg.* 2014;117(7):650-657.
41. Nyland J, Mattocks A, Kibbe S, Kalloub A, Greene JW, Caborn DN. Anterior cruciate ligament reconstruction, rehabilitation, and return to play: 2015 update. *Open Access J Sports Med.* 2016;7:21-32.
42. van der List JP, DiFelice GS. Range of motion and complications following primary repair versus reconstruction of the anterior cruciate ligament. *Knee.* 2017;24(4):798-807.

43. Ajuied A, Wong F, Smith C, Norris M, Earnshaw P, Back D, Davies A. Anterior cruciate ligament injury and radiologic progression of knee osteoarthritis: A systematic review and meta-analysis. *Am J Sports Med.* 2014;42(9):2242-2252.
44. Chalmers PN, Mall NA, Moric M, Sherman SL, Paletta GP, Cole BJ, Bach BR, Jr. Does ACL reconstruction alter natural history?: A systematic literature review of long-term outcomes. *J Bone Joint Surg Am.* 2014;96(4):292-300.
45. Kessler MA, Behrend H, Henz S, Stutz G, Rukavina A, Kuster MS. Function, osteoarthritis and activity after ACL-rupture: 11 years follow-up results of conservative versus reconstructive treatment. *Knee Surg Sports Traumatol Arthrosc.* 2008;16(5):442-448.
46. Hennings J. Primary anatomical repair of proximal ACL ruptures with suture anchors: 1 year follow-up. Annual Meeting of the DKG; Germany; 2018.
47. Büchler L, Regli D, Evangelopoulos DS, Bieri K, Ahmad SS, Krismer A, Muller T, Kohl S. Functional recovery following primary ACL repair with dynamic intraligamentary stabilization. *Knee.* 2016;23(3):549-553.
48. Kohl S, Evangelopoulos DS, Schar MO, Bieri K, Muller T, Ahmad SS. Dynamic intraligamentary stabilisation: Initial experience with treatment of acute ACL ruptures. *Bone Joint J.* 2016;98-B(6):793-798.

# Chapter 11

**Clinical outcomes of arthroscopic primary repair of proximal anterior cruciate ligament tears are maintained at mid-term follow-up**

Gregory S. DiFelice

Jelle P. van der List

*Arthroscopy. 2018 Apr;34(4):1085-1093.*

## **Abstract**

### **Purpose**

To assess the mid-term clinical outcomes in patients with proximal avulsion anterior cruciate ligament (ACL) tears undergoing arthroscopic suture anchor primary repair.

### **Methods**

The first 11 consecutive patients with proximal avulsion tears treated with arthroscopic primary repair were evaluated at mid-term (minimum five year) follow-up. Physical examination was performed, laxity examination consisting of Lachman, pivot shift and anterior drawer test were performed, and patients were asked to complete the Lysholm, modified Cincinnati, Single Assessment Numeric Evaluation (SANE), and International Knee Documentation Committee (IKDC) questionnaires.

### **Results**

Ten of 11 patients were seen at mean follow-up of  $6.0 \pm 1.5$  years (range: 4.8 – 9.2 years). One patient was lost to follow-up, who had already failed at short-term follow-up. One additional patient underwent reoperation for a medial meniscus tear and also had a partial ACL tear, who was clinically stable at last follow-up. All patients had full range of motion. Nine patients had a negative Lachman and a negative pivot shift (IKDC A) and one patient had a 1A Lachman and a 1+ pivot shift (IKDC B). Mean Lysholm score was  $96.0 \pm 4.5$  (range: 88 – 100), modified Cincinnati  $95.6 \pm 7.4$  (range: 80 – 100), SANE score  $95.4 \pm 5.4$  (range: 85 – 100), preinjury Tegner  $7.2 \pm 1.2$  (range: 5 – 9), postoperative Tegner  $6.6 \pm 1.8$  (range: 3 – 9) and IKDC subjective score  $92.3 \pm 11.3$  (range: 64 – 100).

### **Conclusions**

The clinical outcomes of arthroscopic primary repair of proximal ACL tears with suture anchors are excellent and maintained at mid-term follow-up in a carefully selected subset of patients with proximal tears and excellent tissue quality.

### **Level of Evidence**

Therapeutic case series, level IV



## Introduction

Primary repair of the anterior cruciate ligament (ACL) was a commonly performed technique in the twentieth century.<sup>1-11</sup> Initially, several authors reported good outcomes of open primary repair at short-term (two year) follow-up,<sup>5,6,10,12-14</sup> but these outcomes were reported to deteriorate at mid-term (five year) follow-up.<sup>9,11,15-19</sup> This ultimately led to a shift towards augmented repair and, ultimately, primary reconstruction, which is now the current gold standard in surgically treating ACL injuries.<sup>20-22</sup>

In the historical outcomes of open primary repair, however, several factors can be identified that may have negatively influenced these outcomes. Firstly, patients with all tear types were historically treated, while, in hindsight, outcomes were significantly better in patients with proximal tears.<sup>19,20,23</sup> Secondly, surgery consisted of an invasive arthrotomy, while it is known that significantly less complications and better results can be achieved with arthroscopic surgery.<sup>24</sup> Thirdly, postoperative rehabilitation historically consisted of joint immobilization for 4 to 6 weeks, while modern-day rehabilitation with early range of motion (ROM) decreases the risk for pain, stiffness and decreased function.<sup>25,26</sup> Finally, sutures were tied over bone, and even used absorbable sutures were used,<sup>5,15</sup> while modern day suture anchors can be used for more direct tensioning of the repair to the femoral wall.

With the implementation of modern-day technology, such as magnetic resonance imaging (MRI) for patient selection, arthroscopy for minimal invasive surgery, advanced rehabilitation programs to prevent stiffness, and suture anchors for direction tensioning, it can be expected that outcomes of arthroscopic primary repair in patients with proximal tears will be significantly better.<sup>20,21,27,28</sup> Indeed, DiFelice et al. was the first to report outcomes in 11 consecutive patients with proximal tears undergoing arthroscopic primary suture anchor repair noting only 1 failure (9%), and excellent clinical outcomes at short-term follow-up,<sup>29</sup> which was recently confirmed by others.<sup>30-32</sup> Mid-term outcomes, however, are currently lacking, and are necessary to assess if deterioration of outcomes occurs with this arthroscopic technique.<sup>33,34</sup>

Therefore, the purpose of this study was to assess the mid-term clinical outcomes in patients with proximal avulsion ACL tears undergoing arthroscopic suture anchor primary repair. The hypothesis was that the clinical outcomes would be maintained in this select group of patients with regard to revision rates, and functional and patient-reported outcomes.

## Methods

This retrospective study is a follow-up study of the previously reported short-term outcomes of the same group of patients.<sup>29</sup> Following institutional review board approval (IRB No. 16006), all patients treated with arthroscopic primary repair of proximal ACL tears between April 2008 and June 2012 were identified. A total of 190 operative ACL treatment were performed during this period. Surgical indications for arthroscopic primary repair consisted of (I) preoperative clinical instability (Lachman, anterior drawer and/or pivot shift testing), (II) the desire to return to previous level of activities, (III) a proximal avulsion (type I) ACL tear characterized by the possibility to reapproximate the torn distal remnant towards the femoral footprint, and (IV) excellent tissue quality characterized by the ability to withhold suture passage.<sup>35</sup> Patients were included if they had undergone arthroscopic primary repair of proximal ACL tears, and were excluded for this retrospective chart review when they (I) had insufficient tissue length and/or tissue quality and were thus treated with ACL reconstruction (n = 133), or (II) had (II) multiligamentous injuries (>2 ligaments) (n = 46). Ultimately, 11 out of 144 patients had isolated ACL tears (7.6%) that underwent arthroscopic primary ACL repair between April 2008 and June 2012 and these 11 consecutive patients were included for this mid-term follow-up study.

### Surgical technique

Preoperative MRI confirmed complete proximal tears in all 11 patients. All patients consented to the preoperative treatment plan that arthroscopic primary repair would be performed if sufficient tissue length and tissue quality was present at surgery, and if not, they would undergo ACL reconstruction. All patients underwent surgery by the senior author (G.S.D.). Standard knee arthroscopy was first performed to assess if sufficient tissue length and tissue quality was present for the primary repair technique. The surgical technique of arthroscopic suture anchor primary ACL repair has been previously described.<sup>29,36,37</sup> In brief, after identifying the anteromedial and posterolateral bundle, suturing is started at the intact distal end, and a Scorpion suture passer (Arthrex, Naples, FL) is used to pass No. 2 TigerWire sutures (Arthrex) proximally in the anteromedial bundle in an alternating, interlocking Bunnel-type pattern. The same process is then repeated for the posterolateral bundle using No. 2 FiberWire (Arthrex). Then, via an accessory inferomedial portal, a hole is drilled, tapped or punched, depending on bone quality, into the origin of the anteromedial femoral footprint. The TigerWire sutures of the anteromedial bundle are then retrieved, and passed through the eyelet of a 4.75mm vented BioComposite SwiveLock suture anchor (Arthrex). With the knee at 90° flexion, the suture anchor is deployed in the anteromedial footprint hole, while the ligament is tensioned to the femoral wall in order to prevent gap formation.<sup>38</sup> The same technique is then repeated for the posterolateral bundle with the knee at 115° flexion. The knee is flexed during suture anchor deployment in order to avoid posterior blow-out of the suture anchors. The repair is then complete, the knee is cycled through its ROM to test for impingement, and with a probe the tension and stiffness of the repaired ligament remnant

are tested. An intraoperative Lachman is performed to confirm minimal anteroposterior translation.

### **Rehabilitation**

Rehabilitation goals were controlling swelling and regaining early ROM, as this has been shown to be safe following this technique.<sup>38,39</sup> A brace was worn in the first month. During weight bearing, the brace was locked in extension until quadriceps control returned, at which point the brace was unlocked for ambulation. Patients were motivated to start ROM exercises without the brace, and without weight bearing, in the first days after surgery.<sup>29,36</sup> Patients were weaned off the brace after one month, and were advanced to gentle strengthening and standard ACL rehabilitation protocols.<sup>40,41</sup>

### **Outcome measures**

Patients were routinely seen in clinic at one week, one month, three months, six months, one year, two years and five years postoperatively. Data collected from medical records included age, BMI, delay from injury to surgery, gender, injury mechanism, concomitant injuries, and radiological follow-up.

Primary outcomes of surgery were clinical failure rates (defined as 2+ Lachman, 2+ pivot shift, patient complaining of instability, and/or radiologically shown discontinuity of the repaired ligament), and reoperation rates. Secondary outcomes were clinical stability examination (Lachman test, anterior drawer test and pivot shift test), functional and patient-reported outcomes. Lysholm<sup>42</sup> scores and Modified Cincinnati<sup>43, 44</sup> scores were collected to patient-reported impact of knee function and symptoms on daily activities. Tegner<sup>45</sup> scores were collected to assess the level of activity both before injury, and at mid-term follow-up. Using the Single Assessment Numeric Evaluation (SANE)<sup>46</sup>, patients were asked how they graded their knee function on a scale of 0 to 100 (with 100 being the best score). Objective International Knee Documentation Committee (IKDC) score was completed by the surgeon of the initial surgery in order to assess the objective outcomes of surgery. Finally, patients completed the subjective IKDC score to assess the subjective outcome following surgery.<sup>47</sup> Data was reported in mean  $\pm$  standard deviation (SD) with the range.

### **Statistical analysis**

All data was collected using SPSS Version 21 (SPSS Inc., Armonk, NY, USA). Descriptive statistics were used to assess patient demographics and outcomes.

## Results

The mean age of the eleven patients was  $37 \pm 12$  years (range: 17 – 57 years), mean BMI was  $25 \pm 4$  (range: 21 – 35), and ten patients were males. Mean delay from injury to surgery was  $39 \pm 28$  days (range 10 – 93 days). Mean follow-up was  $6.0 \pm 1.5$  years (range: 4.8 – 9.2 years).

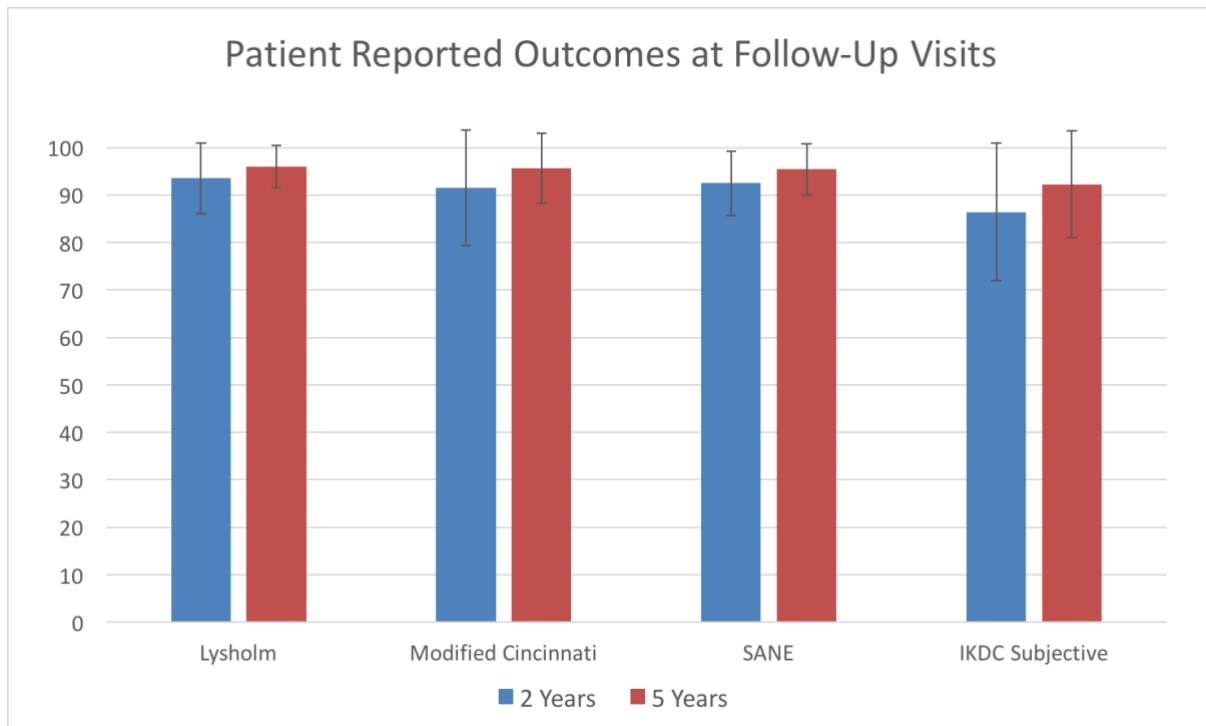
### Failures and reoperations

One patient (9%, patient 9) had an atraumatic rerupture of the ACL descending stairs three months postoperatively while admittedly noncompliant with brace usage and physical therapy. This patient moved out-of-state and could not be seen for mid-term follow-up evaluation. At two-year follow-up, this patient had an IKDC objective score of C (Lachman 1A, pivot shift 2+), KT-1000 leg difference of 6 mm, and fair functional outcome scores.

One patient (9%, patient 7) had a new twisting injury playing football after 2.5 years and complained of medial joint line tenderness but no instability. MRI revealed a medial meniscus tear, and intraoperatively this patient had a complex parrot-beak medial meniscus tear for which partial meniscectomy was performed. A partial ACL tear of a large part of the AM bundle was noted during surgery and this was left because the knee was intraoperatively stable. At final visit 2.5 years later, this patient had a stable knee and had excellent outcome scores (Table 1).

### Clinical assessment

All patients had knee extension of  $0^\circ$  and minimum  $135^\circ$  flexion at the most recent follow-up visit. Of the ten patients that returned for a visit, nine patients had an IKDC A score with a negative Lachman examination and negative pivot shift examination and one patient had an IKDC B score with a 1A Lachman and 1+ pivot shift. Mean Lysholm score was  $96.0 \pm 4.5$  (range: 88 – 100), mean modified Cincinnati score was  $95.6 \pm 7.4$  (range: 80 – 100), mean SANE score was  $95.4 \pm 5.4$  (range: 85 – 100), and mean subjective IKDC score was  $92.3 \pm 11.3$  (range: 64.4 – 100). Mean preinjury Tegner score was  $7.2 \pm 1.2$  (range: 5 – 9) and mean postoperative Tegner  $6.6 \pm 1.8$  (range: 3 – 9). No deterioration (clinically relevant differences) were noted between the two-year and five-year outcomes in any of the outcome scores (Table 1, Figure 1). The outcomes of the individual patients at short- and mid-term follow-up are displayed in Table 1.



**Figure 1.** Histogram that shows functional outcomes of patients at minimum two-year and minimum five-year follow-up visits. No differences were seen in any of the scores at the different follow-up visits.

One patient (patient 8) reported only fair functional outcome scores and a decrease of Tegner score (6 to 4). This patient was a 55-year-old female at the time of latest follow-up and is mainly limited by osteoarthritis of both hips and the lumbar spine. MRI of the knee of this patient showed continuity of the ACL, and the knee was noted to be stable at examination (IKDC A).

Two other patients had a decrease in Tegner score. Patient 10 reported excellent functional outcomes but a decrease in Tegner score (9 to 7). He finished college in which he played rugby and football, and subsequently stopped playing those sports at high-level. He plays recreational pivoting and cutting sports without any problems. Patient 2 had a decrease of Tegner score (5 to 3) and was less active without any reason attributed to knee problems, although he reported occasional pain with weather changes.

**TABLE 1.** Objective and subjective clinical outcomes of the 10 patients that could be evaluated at mid-term follow-up (patient 9 moved out-of-state and was lost to follow-up, and was a clinical failure)

Pt.	Age (yrs)	Gender	Concom. injuries	Final FU (yrs)	Lachman		Pivot		Lysholm		Modified Cincinnati		SANE		Tegner		IKDC				
					2 yr	5yr	2 yr	5yr	2 yr	5yr	2 yr	5yr	Pre	2 yr	5yr	2 yr	5yr	Subjective	Objective	2 yr	5yr
1	37	Male	Chondro, MCL, MM Tear	9.2	neg	1A	neg	1+	100	91	100	89	90	90	7	8	7	100	92	A	B
2	38	Male		7.3	neg	neg	neg	neg	90	92	92	87	95	90	5	5	3	91	82	A	A
3	22	Male		7.3	neg	neg	neg	neg	95	95	92	100	95	99	7	8	7	91	94	A	A
4	57	Male	Chondro, LM Tear	6.0	neg	neg	neg	1+	83	100	63	100	90	100	7	6	7	95	99	B	A
5	47	Male	MIM Tear	6.1	neg	neg	neg	neg	94	100	96	100	95	100	8	7	8	84	100	A	A
6	23	Male		4.7	neg	neg	neg	neg	100	100	100	100	95	100	9	9	9	100	100	A	A
7	41	Male		5.2	neg	neg	neg	neg	100	95	100	100	95	95	7	7	7	87	95	A	A
8	50	Female	Chondro, MCL	5.0	neg	neg	neg	neg	79	88	77	80	75	85	6	5	4	52	64	A	A
10	17	Male	MCL	4.8	neg	neg	neg	neg	100	100	100	100	100	100	9	9	7	91	100	A	A
11	37	Male	MCL	4.8	neg	neg	neg	neg	94	99	95	100	95	95	7	6	7	74	97	A	A
<b>Tot</b>	<b>37±</b>			<b>6.0±</b>					<b>93.5</b>	<b>96.0</b>	<b>91.5±</b>	<b>95.6±</b>	<b>92.5</b>	<b>95.4</b>	<b>7.2±</b>	<b>7.0±</b>	<b>6.6±</b>	<b>86.4</b>	<b>92.3</b>		
<b>13</b>				<b>1.5</b>					<b>±7.5</b>	<b>±4.5</b>	<b>12.2</b>	<b>7.4</b>	<b>±6.8</b>	<b>±5.4</b>	<b>1.2</b>	<b>1.5</b>	<b>1.8</b>	<b>±14.</b>	<b>±11.</b>		

Pt. indicates patient number (chronological); FU, follow-up; yrs, years; concom., concomitant; SANE, Single Assessment Numeric Evaluation on question how patients rate their knee with 0 as completely abnormal and 100 as completely normal; IKDC, International Knee Documentation Committee; chondro., chondromalacia; MCL, medial collateral ligament grade 3 tear conservatively treated; MM, medial meniscus tears; LM, lateral meniscus tear.

## Discussion

The main finding of this study was that excellent short-term clinical outcomes of arthroscopic primary repair in patients with proximal ACL tears and excellent tissue quality were maintained at mid-term follow-up. In this study, the clinical outcomes in ten out of eleven patients were good with stable knees (i.e. Lachman and pivot shift), excellent patient-reported outcomes, and return to activity levels. Although MRI confirmation of ligament continuity was not assessed in this study, all patients were clinically stable (as opposed to preoperatively) and could participate in activities up to five years postoperatively they could not preoperatively. Arthroscopic primary repair of proximal ACL is an excellent minimally-invasive treatment in carefully selected patients with proximal tear and excellent tissue quality of which the results are maintained at mid-term follow-up.

Recently, promising short-term outcomes of arthroscopic primary repair of proximal tears have been reported,<sup>29,30</sup> which has increased the enthusiasm for this procedure.<sup>29,30,33,34,48</sup> In the historical literature, however, outcomes of open primary repair were also promising at short-term follow-up,<sup>5,6,10,12-14</sup> but deteriorated at mid-term (5 year) follow-up.<sup>9,11,15-17,19</sup> When comparing the results in this study with the outcomes of these patients at two-year follow-up, no deterioration or differences were noted in any of the outcomes between the two-year and five-year assessment. Several factors could play a role in the finding of this study that the results were maintained at mid-term follow-up, as opposed to the findings in many historical studies.<sup>9,11,15-17,19</sup> First of all, in the historical studies primary repair was performed for all tear types and sutures were often placed in both the femoral and tibial remnant stumps after which they were guided through drill holes in the tibia and femur and tied over bone.<sup>7,13</sup> Sherman et al. showed in their extensive subgroup analysis, however, that better outcomes were noted in patients with proximal avulsion tears.<sup>19</sup> In our current study only patients with proximal avulsion tear types were repaired and reattached to the femoral wall. Several experimental studies have shown that healing of the midsubstance of the ACL is limited because the synovial fluid washes away the fibrin clot that is necessary for ligament healing.<sup>49,50</sup> In contrast, other studies have shown that the proximal part of the ACL has significant healing capacity,<sup>51,52</sup> that explains the previously described phenomena of ACL reattachment to the posterior cruciate ligament or femoral notch<sup>53,54</sup> and observed healing<sup>55-57</sup> of proximal tears. Indeed, some studies in the historical literature reported mid-term outcomes of open primary repair of only proximal tears and reported excellent outcomes.<sup>23,58,59</sup> Genelin et al. reported outcomes on 42 out of 49 patients treated with open primary repair of proximal tears.<sup>23</sup> They noted that 86% of patients were satisfied, and that 81% of patients had negative or 1+ Lachman, a negative pivot shift and less than 3mm leg difference with the contralateral side on the KT-1000. Furthermore, they noted that 95% returned to sports and 66% returned to previous level of sports. In the historical studies on open primary repair and the more recent experimental studies, tear location seems to be a critical predictor for the success of primary repair.<sup>28,60</sup> It is proximal tears that can be repaired

and heal to the femur, and this likely explains why our results were maintained at mid-term follow-up, as opposed to many of the historical primary repair studies.

Another factor that seems to explain the lack of deterioration is the arthroscopic approach to surgery. Historically, primary repair was performed via an arthrotomy, which is invasive, and likely contributed to the high incidence of stiffness and patellofemoral pain that were reported.<sup>15,61</sup> In 2005, Strand et al. reported their long-term (>15 years) results of open primary repair and also noted the invasiveness of the old procedure.<sup>24</sup> They suggested that the use of arthroscopy in primary repair might reduce the number of patients needing later reconstructions as this changes the risk-benefit ratio for patients.<sup>24</sup> Indeed, with the development of arthroscopy, primary repair can be performed in a minimally invasive manner,<sup>36,39</sup> and we believe this may also explain why our results were maintained at mid-term follow-up. In this study, nearly all patients reported their knee felt normal and four patients reported their knee felt completely normal (SANE 100), of which one patient could not recall which knee was operated on.

In this study, rehabilitation focused on regaining early ROM and controlling swelling, whereas historical studies focused on joint immobilization with a cast or brace for several weeks.<sup>10,23</sup> Modern rehabilitation protocols, however, focus on regaining early ROM in order to prevent postoperative stiffness that was reported in up to 71% of patients in the historical studies.<sup>15,16</sup> Genelin also noticed the role of joint immobilization in their mid-term study in which they showed excellent results when only treating proximal tears.<sup>23</sup>

In this study, only 11 out of 144 ACL tears (7.6%) were found to have sufficient tissue length (i.e. distal remnant can be approximated towards the femoral footprint) and tissue quality (i.e. tissue can withhold sutures) for this surgical technique. This can be explained by the fact that the senior author applied strict patient selection criteria as this was a novel procedure. A recent study assessed the prevalence of proximal tears using MRI, and found, however, that 16% of patients had tears located in the most proximal 10% of the ligament (type I) and fully 43% had tears in the most proximal 25% of the ligament (16% type I tears and 27% type II tears (tear in proximal 10 – 25% of ligament)).<sup>35</sup> It has also been shown that 90% of these type I tears and approximately 50% of the type II tears can be treated by arthroscopic primary repair.<sup>62</sup> Combining the numbers of these studies indicates that a larger share (approximately 28%) of all ACL tears could potentially be treated with arthroscopic primary ACL repair. Further studies are necessary to exactly define which percentage of patients can be repaired and which patient characteristics are associated with proximal avulsion tears. In our practice, patients are recommended to undergo primary repair if the tear type and tissue quality are sufficient for repair, as we believe the risk-benefit ratio has changed.<sup>20,22,37</sup> Arthroscopic primary repair is a safe and quick procedure with a low complication rate and quick return of ROM.<sup>38,39</sup> Furthermore, in our practice, patients have no graft harvesting complications,<sup>39</sup> and low incidence of quadriceps atrophy, and this allows them to go through rehabilitation milestones quickly. Finally, if primary repair fails, they can still undergo primary ACL



reconstruction (tunnels or grafts). ACL reconstruction is only performed when primary repair is not possible.

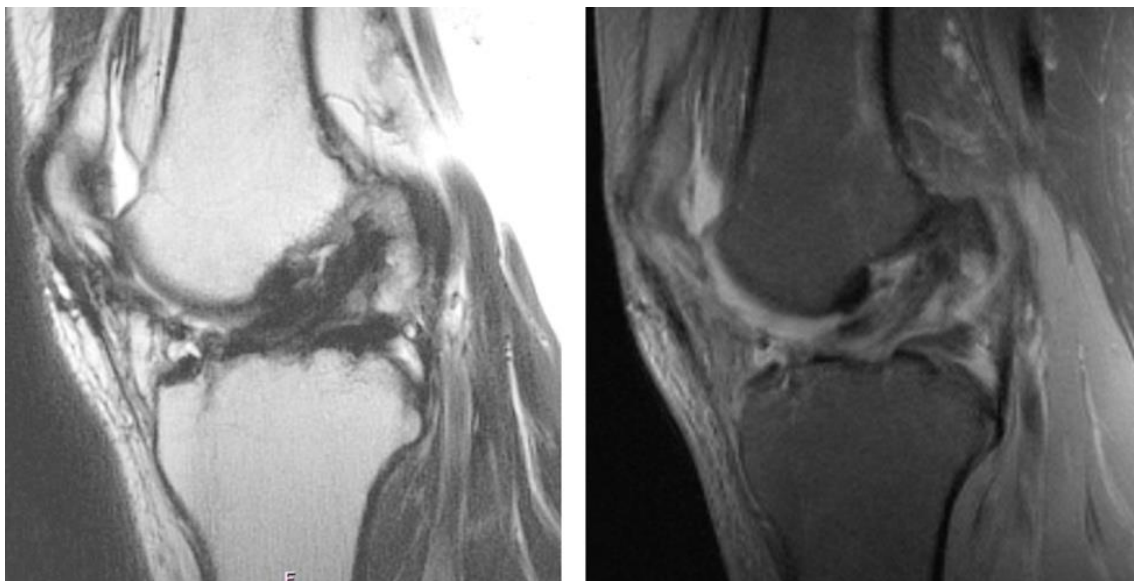
Although the average outcomes scores were high in this study, two patients had a decrease in Tegner score and one patient had suboptimal functional outcomes. This latter patient was a 50-year-old female (55 years of age at follow-up, patient 8) who had severe bilateral hip and lumbar spine osteoarthritis, and beginning knee osteoarthritis that limited her activities. Two other patients had a decrease in Tegner score alone. One patient was a 17-year old male (22 years of age at follow-up, patient 10) who played at high-level sports during college (Tegner score 9) and his activity level decreased when he left college and started to play recreational sports, which was situational and unrelated to his knee function. The third patient was a 38-year old man (46 years of age at follow-up, patient 2) who decreased his activities unrelated to his knee function, but he noticed some pain with weather changes.

In the early 1990s, some authors recognized the role of tear location on outcomes of primary repair and reported good results of open primary repair of proximal tears.<sup>23,28,58,59</sup> As a result, some surgeons used a treatment algorithm in the early 1990s that was based on tear location and tissue quality: proximal avulsion tears that could be reattached into the femoral wall were repaired, whereas tear types that were too short for reattachment or had insufficient tissue quality were reconstructed.<sup>13,23,63-66</sup> Because of the several prospective studies in the early 1990s that showed more predictable outcomes of ACL reconstruction compared to primary ACL repair, which is not surprising as the role of tear location was not considered in these studies, ACL reconstruction became the gold standard for all tear types, rather than only for irreparable tears.<sup>20</sup> The results in this study show that good outcomes can be achieved in appropriately selected patients with a significantly less invasive surgery than reconstruction surgery,<sup>39</sup> and one in which no bridges are burned for future reconstruction surgery if it becomes necessary.

It should be noted that the average age in this study was 37 years at time of operation, which is higher than most of the ACL studies. This could be explained by the fact that the procedure was initially only performed in somewhat lower-demand patients. However, three male patients were young at time of surgery (17, 22 and 23 years of age) and played competitive football and rugby (Tegner 9), competitive rugby (Tegner score 9) or recreational basketball (Tegner 7) before and after injury, respectively. These patients had stable knees at examination, reported their knee felt normal (SANE 100, 99 and 100, respectively), and all returned to pivoting and/or high-impact (tackling) sports. The two patients playing rugby both endured valgus tackles several years after their return to sports, and came to the clinic for evaluation. They both had grade 3+ medial collateral ligament injuries, and in both cases the ACL was intact (negative Lachman, negative pivot shift, IKDC objective A). These injuries were treated conservatively.

## Limitations

Limitations are present in this study. First of all, this is a retrospective study with a small sample size and selection bias cannot be excluded in this study. Secondly, the patients in this study had a higher age than average studies reporting outcomes of ACL surgery. Outcomes in younger patients might be inferior as higher failure rates of ACL reconstruction surgery are also reported in younger patients (up to 30%).<sup>67,68</sup> However, the youngest patients in this study reported excellent outcomes and had among the highest outcome scores and activity levels. Thirdly, this study consists of clinical outcomes and does not contain radiologic confirmation of the intact repaired ligament. Although this would have been beneficial for this novel treatment, MRI was not routinely performed in clinically stable patients as it generally not performed in the ACL literature.<sup>69</sup> Three patients had postoperative MRI at final follow-up in which a continuous ligament was seen with hypo-intense homogenous signal (Figure 2). Finally, no objective return to sports assessment and no KT-1000 examinations were performed for logistic reasons, although at two-year follow-up KT-1000 examinations were performed and all tested patients had <3mm leg difference (except the failed patient).



**Figure 2.** Postoperative MRI of patient 8 at 4.9-year follow-up. The sagittal T1 (left) and T2 (right) images show a homogeneous signal in the ligament with continuity of the fibers from the tibial footprint to the femoral footprint. This patient had a stable Lachman and pivot shift examination.

## **Conclusion**

The clinical outcomes of arthroscopic primary repair of proximal ACL tears with suture anchors are excellent and maintained at mid-term follow-up in a carefully selected subset of patients with proximal tears and excellent tissue quality.

## **Disclosures**

Authors J.P.L. and D.N.M. declare they have no conflict of interest. Author G.S.D. declares he is a paid consultant for Arthrex (Naples, FL, USA) but this has not conflicted this study.

## References

1. Robson AW. Vi. Ruptured crucial ligaments and their repair by operation. *Ann Surg.* 1903;37(5):716-718.
2. Palmer I. On the injuries to the ligaments of the knee joint. *Acta Orthop Scand.* 1938;53.
3. O'Donoghue DH. Surgical treatment of fresh injuries to the major ligaments of the knee. *J Bone Joint Surg Am.* 1950;32(4):721-738.
4. O'Donoghue DH. An analysis of end results of surgical treatment of major injuries to the ligaments of the knee. *J Bone Joint Surg Am.* 1955;37(1):1-13.
5. Feagin JA, Abbott HG, Rokous JR. The isolated tear of the anterior cruciate ligament. *J Bone Joint Surg Am.* 1972;54(6):1340-1341.
6. England RL. Repair of the ligaments about the knee. *Orthop Clin North Am.* 1976;7(1):195-204.
7. Marshall JL, Warren RF, Wickiewicz TL, Reider B. The anterior cruciate ligament: A technique of repair and reconstruction. *Clin Orthop Relat Res.* 1979;143:97-106.
8. Heim U, Bachmann B, Infanger K. Reinsertion of the anterior cruciate ligament or primary ligamentous plasty? *Helv Chir Acta.* 1982;48(5):703-708.
9. Lysholm J, Gillquist J, Liljedahl SO. Long-term results after early treatment of knee injuries. *Acta Orthop Scand.* 1982;53(1):109-118.
10. Marshall JL, Warren RF, Wickiewicz TL. Primary surgical treatment of anterior cruciate ligament lesions. *Am J Sports Med.* 1982;10(2):103-107.
11. Odensten M, Lysholm J, Gillquist J. Suture of fresh ruptures of the anterior cruciate ligament. A 5-year follow-up. *Acta Orthop Scand.* 1984;55(3):270-272.
12. Liljedahl SO, Lindvall N, Wetterfors J. Early diagnosis and treatment of acute ruptures of the anterior cruciate ligament; a clinical and arthrographic study of forty-eight cases. *J Bone Joint Surg Am.* 1965;47(8):1503-1513.
13. Sherman MF, Bonamo JR. Primary repair of the anterior cruciate ligament. *Clin Sports Med.* 1988;7(4):739-750.
14. Straub T, Hunter RE. Acute anterior cruciate ligament repair. *Clin Orthop Relat Res.* 1988;227:238-250.
15. Feagin JA, Jr., Curl WW. Isolated tear of the anterior cruciate ligament: 5-year follow-up study. *Am J Sports Med.* 1976;4(3):95-100.
16. Engebretsen L, Benum P, Sundalsvoll S. Primary suture of the anterior cruciate ligament a 6-year follow-up of 74 cases. *Acta Orthop Scand.* 1989;60(5):561-564.
17. Lysholm J, Gillquist J, Liljedahl SO. Long-term results after early treatment of knee injuries. *Acta Orthop Scand.* 1989;53(1):109-118.
18. Kaplan N, Wickiewicz TL, Warren RF. Primary surgical treatment of anterior cruciate ligament ruptures. A long-term follow-up study. *Am J Sports Med.* 1990;18(4):354-358.
19. Sherman MF, Lieber L, Bonamo JR, Podesta L, Reiter I. The long-term followup of primary anterior cruciate ligament repair. Defining a rationale for augmentation. *Am J Sports Med.* 1991;19(3):243-255.
20. van der List JP, DiFelice GS. Primary repair of the anterior cruciate ligament: A paradigm shift. *Surgeon.* 2017;15(3):161-168.
21. van der List JP, DiFelice GS. The role of ligament repair in anterior cruciate ligament surgery. In: Mascarenhas R, Bhatia S, Lowe WR, editors. *Ligamentous injuries of the knee.* 1 ed. Houston: Nova Science Publishers; 2016. p. 199-220.
22. van der List JP, DiFelice GS. Preservation of the anterior cruciate ligament: A treatment algorithm based on tear location and tissue quality. *Am J Orthop (Belle Mead NJ).* 2016;45(7):E393-E405.
23. Genelin F, Trost A, Primavesi C, Knoll P. Late results following proximal reinsertion of isolated ruptured ACL ligaments. *Knee Surg Sports Traumatol Arthrosc.* 1993;1(1):17-19.
24. Strand T, Molster A, Hordvik M, Krukhaug Y. Long-term follow-up after primary repair of the anterior cruciate ligament: Clinical and radiological evaluation 15-23 years postoperatively. *Arch Orthop Trauma Surg.* 2005;125(4):217-221.
25. Millett PJ, Wickiewicz TL, Warren RF. Motion loss after ligament injuries to the knee. Part i: Causes. *Am J Sports Med.* 2001;29(5):664-675.

26. Shelbourne KD, Wilckens JH, Mollabashy A, DeCarlo M. Arthrofibrosis in acute anterior cruciate ligament reconstruction. The effect of timing of reconstruction and rehabilitation. *Am J Sports Med.* 1991;19(4):332-336.
27. Taylor SA, Khair MM, Roberts TR, DiFelice GS. Primary repair of the anterior cruciate ligament: A systematic review. *Arthroscopy.* 2015;31(11):2233-2247.
28. van der List JP, DiFelice GS. Role of tear location on outcomes of open primary repair of the anterior cruciate ligament: A systematic review of historical studies. *Knee.* 2017; 24(5):898-908.
29. DiFelice GS, Villegas C, Taylor SA. Anterior cruciate ligament preservation: Early results of a novel arthroscopic technique for suture anchor primary anterior cruciate ligament repair. *Arthroscopy.* 2015;31(11):2162-2171.
30. Achtnich A, Herbst E, Forkel P, Metzloff S, Sprenger F, Imhoff AB, Petersen W. Acute proximal anterior cruciate ligament tears: Outcomes after arthroscopic suture anchor repair versus anatomic single-bundle reconstruction. *Arthroscopy.* 2016;32(12):2562-2569.
31. Bigoni M, Gaddi D, Gorla M, Munegato D, Pungitore M, Piatti M, Turati M. Arthroscopic anterior cruciate ligament repair for proximal anterior cruciate ligament tears in skeletally immature patients: Surgical technique and preliminary results. *Knee.* 2017;24(1):40-48.
32. Smith JO, Yasen SK, Palmer HC, Lord BR, Britton EM, Wilson AJ. Paediatric ACL repair reinforced with temporary internal bracing. *Knee Surg Sports Traumatol Arthrosc.* 2016;24(6):1845-1851.
33. Hohmann E. Editorial commentary: Renaissance of primary anterior cruciate ligament repair: Is history repeating itself? *Arthroscopy.* 2016;32(12):2570-2571.
34. Lubowitz JH. Editorial commentary: Anterior cruciate ligament primary repair, revisited. *Arthroscopy.* 2015;31(11):2172.
35. van der List JP, Mintz DN, DiFelice GS. The location of anterior cruciate ligament tears: A prevalence study using magnetic resonance imaging. *Orthop J Sports Med.* 2017;5(6):2325967117709966.
36. DiFelice GS, van der List JP. Arthroscopic primary repair of proximal anterior cruciate ligament tears. *Arthrosc Tech.* 2016;5(5):E1057-E1061.
37. van der List JP, DiFelice GS. Preservation of the anterior cruciate ligament: Surgical techniques. *Am J Orthop (Belle Mead NJ).* 2016;45(7):E406-414.
38. van der List JP, DiFelice GS. Gap formation following primary repair of the anterior cruciate ligament: A biomechanical evaluation. *Knee.* 2017;24(2):243-249.
39. van der List JP, DiFelice GS. Range of motion and complications following primary repair versus reconstruction of the anterior cruciate ligament. *Knee.* 2017;24(4):798-807.
40. Cavanaugh JT, Powers M. ACL rehabilitation progression: Where are we now? *Curr Rev Musculoskelet Med.* 2017.
41. Wilk KE, Arrigo CA. Rehabilitation principles of the anterior cruciate ligament reconstructed knee: Twelve steps for successful progression and return to play. *Clin Sports Med.* 2017;36(1):189-232.
42. Lysholm J, Gillquist J. Evaluation of knee ligament surgery results with special emphasis on use of a scoring scale. *Am J Sports Med.* 1982;10(3):150-154.
43. Noyes FR, Barber SD, Mooar LA. A rationale for assessing sports activity levels and limitations in knee disorders. *Clin Orthop Relat Res.* 1989 (246):238-249.
44. Shelbourne KD, Barnes AF, Gray T. Correlation of a single assessment numeric evaluation (sane) rating with modified Cincinnati knee rating system and IKDC subjective total scores for patients after ACL reconstruction or knee arthroscopy. *Am J Sports Med.* 2012;40(11):2487-2491.
45. Tegner Y, Lysholm J. Rating systems in the evaluation of knee ligament injuries. *Clin Orthop Relat Res.* 1985 (198):43-49.
46. Williams GN, Taylor DC, Gangel TJ, Uhorchak JM, Arciero RA. Comparison of the single assessment numeric evaluation method and the Lysholm score. *Clin Orthop Relat Res.* 2000 (373):184-192.
47. Hefti F, Muller W, Jakob RP, Staubli HU. Evaluation of knee ligament injuries with the IKDC form. *Knee Surg Sports Traumatol Arthrosc.* 1993;1(3-4):226-234.
48. Lubowitz JH. Editorial commentary: Anterior cruciate ligament primary repair is a holy grail. *Arthroscopy.* 2015;31(11):2248.
49. Proffen BL, Sieker JT, Murray MM. Bio-enhanced repair of the anterior cruciate ligament. *Arthroscopy.* 2015;31(5):990-997.
50. Murray MM. Current status and potential of primary ACL repair. *Clin Sports Med.* 2009;28(1):51-61.

51. Nguyen DT, Ramwadhoebe TH, van der Hart CP, Blankevoort L, Tak PP, van Dijk CN. Intrinsic healing response of the human anterior cruciate ligament: An histological study of reattached ACL remnants. *J Orthop Res.* 2014;32(2):296-301.
52. Nguyen DT, Geel J, Schulze M, Raschke MJ, Woo SL, van Dijk CN, Blankevoort L. Healing of the goat anterior cruciate ligament after a new suture repair technique and bioscaffold treatment. *Tissue Eng Part A.* 2013;19(19-20):2292-2299.
53. Crain EH, Fithian DC, Paxton EW, Luetzow WF. Variation in anterior cruciate ligament scar pattern: Does the scar pattern affect anterior laxity in anterior cruciate ligament-deficient knees? *Arthroscopy.* 2005;21(1):19-24.
54. van der List JP, DiFelice GS. Successful arthroscopic primary repair of a chronic anterior cruciate ligament tear 11 years following injury. *HSS J.* 2017;13(1):90-95.
55. Hetsroni I, Delos D, Fives G, Boyle BW, Lillemo K, Marx RG. Nonoperative treatment for anterior cruciate ligament injury in recreational alpine skiers. *Knee Surg Sports Traumatol Arthrosc.* 2013;21(8):1910-1914.
56. Jorjani J, Altmann D, Auen R, Koopmann C, Lyutenski B, Wirtz DC. Mittel- bis langfristige ergebnisse nach vorderer kreuzbandruptur und versorgung in healing-response-technik. *Z Orthop Unfall.* 2013;151(6):570-579.
57. Steadman JR, Matheny LM, Briggs KK, Rodkey WG, Carreira DS. Outcomes following healing response in older, active patients: A primary anterior cruciate ligament repair technique. *J Knee Surg.* 2012;25(3):255-260.
58. Higgins RW, Steadman JR. Anterior cruciate ligament repairs in world class skiers. *Am J Sports Med.* 1987;15(5):439-447.
59. Bram J, Plaschy S, Lutolf M, Leutenegger A. [the primary cruciate ligament suture--is the method outdated? Results in follow-up of 58 patients]. *Z Unfallchir Versicherungsmed.* 1994;87(2):91-109.
60. van Eck CF, Limpisvasti O, ElAttrache NS. Is there a role for internal bracing and repair of the anterior cruciate ligament? A systematic literature review. *Am J Sports Med.* 2017;363546517717956.
61. Strand T, Engesaeter LB, Molster AO, Raugstad TS, Stangeland L, Stray O, Alho A. Knee function following suture of fresh tear of the anterior cruciate ligament. *Acta Orthop Scand.* 1984;55(2):181-184.
62. van der List JP, DiFelice GS. Preoperative magnetic resonance imaging predicts eligibility for arthroscopic primary anterior cruciate ligament repair. *Knee Surg Sports Traumatol Arthrosc.* 2017.
63. Kuhne JH, Refior HJ. Die primäre naht des vorderen kreuzbands: Eine kritische analyse. *Unfallchirurg.* 1993;96(9):451-456.
64. Andersson C, Odensten M, Good L, Gillquist J. Surgical or non-surgical treatment of acute rupture of the anterior cruciate ligament. A randomized study with long-term follow-up. *J Bone Joint Surg Am.* 1989;71(7):965-974.
65. Cross MJ, Paterson RS, Capito CP. Acute repair of the anterior cruciate ligament with lateral capsular augmentation. *Am J Sports Med.* 1989;17(1):63-67.
66. Raunest J, Derra E, Ohmann C. Long term results following primary reconstruction of the cruciate ligaments without augmentation. *Unfallchirurg.* 1989;17(3):166-174.
67. Webster KE, Feller JA. Exploring the high reinjury rate in younger patients undergoing anterior cruciate ligament reconstruction. *Am J Sports Med.* 2016;44(11):2827-2832.
68. Wiggins AJ, Grandhi RK, Schneider DK, Stanfield D, Webster KE, Myer GD. Risk of secondary injury in younger athletes after anterior cruciate ligament reconstruction: A systematic review and meta-analysis. *Am J Sports Med.* 2016;44(7):1861-1876.
69. Sonnery-Cottet B, Saithna A, Cavalier M, Kajetanek C, Temponi EF, Daggett M, Helito CP, Thaunat M. Anterolateral ligament reconstruction is associated with significantly reduced ACL graft rupture rates at a minimum follow-up of 2 years. *Am J Sports Med.* 2017;363546516686057.

# Chapter 12

## **Repair versus reconstruction for proximal anterior cruciate ligament tears: a study protocol for a prospective randomized controlled trial**

Jelle P. van der List

Harmen D. Vermeijden

Inger N. Sierevelt

Maarten V. Rademakers

Mark L.M. Falke

Gijs T.T. Helmerhorst

Roy A.G. Hoogslag

Wybren A. van der Wal

Arthur van Noort

Gino M.M.J. Kerkhoffs

*BMC Musculoskelet Disord. 2021 Apr 30;22(1):399.*

## **Abstract**

### **Background**

For active patients with a tear of the anterior cruciate ligament (ACL) who would like to return to active level of sports, the current surgical gold standard is reconstruction of the ACL. Recently, there has been renewed interest in repairing the ACL in selected patients with a proximally torn ligament. Repair of the ligament has (potential) advantages over reconstruction of the ligament such as decreased surgical morbidity, faster return of range of motion, and potentially decreased awareness of the knee. Studies comparing both treatments in a prospective randomized method are currently lacking.

### **Methods**

This study is a multicenter prospective block randomized controlled trial. A total of 74 patients with acute proximal isolated ACL tears will be assigned in a 1:1 allocation ratio to either (I) ACL repair using cortical button fixation and additional suture augmentation or (II) ACL reconstruction using an all-inside autologous hamstring graft technique. The primary objective is to assess if ACL repair is non-inferior to ACL reconstruction regarding the subjective International Knee Documentation Committee (IKDC) score at two-years postoperatively. The secondary objectives are to assess if ACL repair is non-inferior with regards to (I) other patient-reported outcomes measures (i.e. Knee Injury and Osteoarthritis Outcome Score, Lysholm score, Forgotten Joint Score, patient satisfaction and pain), (II) objective outcome measures (i.e. failure of repair or graft defined as rerupture or symptomatic instability, reoperation, contralateral injury, and stability using the objective IKDC score and Rollimeter/KT-2000), (III) return to sports assessed by Tegner activity score and the ACL-Return to Sports Index at two-year follow-up, and (IV) long-term osteoarthritis at 10-year follow-up.

### **Discussion**

Over the last decade there has been a resurgence of interest in repair of proximally torn ACLs. Several cohort studies have shown encouraging short-term and mid-term results using these techniques, but prospective randomized studies are lacking. Therefore, this randomized controlled trial has been designed to assess whether ACL repair is at least equivalent to the current gold standard of ACL reconstruction in both subjective and objective outcome scores.

### **Trial registration**

Registered at Netherlands Trial Register (NL9072) on 25<sup>th</sup> of November 2020.



## Background

### Historical overview of ACL repair

The first documented surgical treatment of an anterior cruciate ligament (ACL) injury consisted of open repair in 1895 when Mayo Robson repaired a proximally avulsed ACL and posterior cruciate ligament back to the femur in a 41-year old male with good outcomes at six-year follow-up.<sup>1</sup> In the twentieth century, Ivar Palmar<sup>2,3</sup> and Don O'Donoghue<sup>4,5</sup> reported on open primary repair as a treatment of ACL injuries, and in the early 1970s open primary repair became a popular treatment for ACL injuries.<sup>6-9</sup>

Feagin and Curl were the first to present the outcomes of open repair in 1972 and noted good outcomes at short-term follow-up.<sup>8</sup> A few years later in 1976, however, they noted a deterioration of outcomes at mid-term follow-up in their cohort.<sup>10</sup> Similarly, several other surgeons and researchers noted good short-term<sup>11-16</sup> but disappointing mid-term outcomes<sup>17-21</sup>. With these disappointing results and the promising outcomes of ACL reconstruction, several (randomized) prospective studies were started in the 1980s comparing open ACL repair with open ACL reconstruction.<sup>19,22-24</sup> These prospective studies noted more reliable outcomes with ACL reconstruction when compared to ACL repair, which ultimately led to an abandonment of open ACL repair and to the current gold standard of ACL reconstruction for all patients.<sup>9</sup>

In 1991, Sherman et al. were the first analyzing the disappointing mid-term outcomes of open ACL repair by performing an extensive subgroup analysis.<sup>21</sup> The authors found that a trend towards better outcomes in patients with proximal avulsion type tears and good tissue quality when compared to patients with midsubstance tears and/or tears with poor tissue quality. Unfortunately, the inclusion of the aforementioned prospective trials was already completed before the study by Sherman et al. was published, and thus the prospective trials contained all tear types including patients that might not have been ideal candidates for ACL repair (i.e., those with midsubstance tears or tears with poor tissue quality).

When critically reviewing the historical literature, and bearing in mind these findings by Sherman et al., it can be noted that the results of open repair of proximal ACL tears were indeed better. A recent systematic review of all historical studies on open repair noted that outcomes of open repair of proximal ACL tears showed 83 to 90% clinical stability, 80% return to sports, 79% good to excellent Lysholm score and 86% satisfaction in 539 patients in 11 studies.<sup>25</sup> These findings indicate that ACL repair may have been prematurely abandoned for all tear types and perhaps may be a good treatment option for patients with proximal tears. Furthermore, outcomes of ACL repair can be expected to improve when benefiting from modern development, such as arthroscopy (instead of open repair) and modern rehabilitation (instead of casting and immobilization).

## **Rationale for ACL repair**

The rationale behind better outcomes of ACL repair of proximal tears compared to midsubstance tears is that better vascularity is present at the proximal end of the ligament<sup>26</sup> and, as a result, proximal tears have healing potential for reattachment that is similar to medial collateral ligament (MCL) tears.<sup>27</sup> The reason for the continued pursuit of repair as a treatment of ACL injuries can also be explained by the potential advantages of repair over reconstruction. With ACL repair, the native tissue can be preserved along with proprioception which may provide patients with a more normal feeling of the knee compared to ACL reconstruction.<sup>28,29</sup> Also, ACL repair is a less invasive surgery when compared to ACL reconstruction as no (or only small) tunnels need to be drilled and no graft tissues need to be harvested, leading to lower surgical morbidity,<sup>30-33</sup> faster return of range of motion and fewer complications<sup>34</sup>. Furthermore, in case of failure of both treatments, revision surgery following primary repair is expected to be similar to primary reconstruction (no or only small tunnels have been drilled or grafts harvested), whereas revision of reconstruction surgery can be complicated by tunnel malpositioning or widening and pre-existing hardware and is associated with inferior outcomes compared to primary ACL reconstruction.<sup>35-37</sup>

## **Recent literature on ACL repair**

With the recognized relevance of tear location in ACL repair and the potential advantages of this treatment, several surgeons and researchers have pursued the concept of ACL repair of proximal tears.<sup>38-47</sup> Most of these studies were retrospective small case series reporting good short-term outcomes with an overall reported failure rates of 6 to 9%, reoperation rates of 0 to 4% and patient-reported outcome measures (PROMs) >85% of the maximum score.<sup>48</sup> Three studies have also shown that the good outcomes are maintained at mid-term follow-up.<sup>44,45,49</sup> One prospective study has compared the outcomes of repair (n = 20) versus reconstruction (n = 20) in patients with proximal tears and reported similar outcomes regarding functional outcomes, failure rates and laxity examination.<sup>46</sup> However, no randomized studies or studies with sufficient number of patients to assess differences between the treatments have been performed, and a recent systematic review also concluded higher-level evidence studies for ACL repair are currently lacking.<sup>48</sup> Recent studies have also suggested that primary repair with suture augmentation results in lower failure rates when compared to primary repair without suture augmentation.<sup>42,48</sup>

The current surgical gold standard of treating ACL injuries is ACL reconstruction using autograft tissue of either hamstring tendons, patellar tendon or quadriceps tendon. As for all new surgical techniques, the outcomes of arthroscopic ACL repair need to be compared to the current gold standard in order to assess whether this treatment can be used for standard patient care. Therefore, a randomized controlled trial (RCT) comparing ACL repair with ACL reconstruction is needed. The ACL study group of the Dutch Arthroscopy Association also recently declared that *“the application of ACL repair could be considered in a medial ethical*

*committee-approved study until there is high-grade and long-term evidence regarding the efficacy of modern-day ACL repair.”*

### **Goal and hypotheses**

The goal of this multicenter non-inferior prospective randomized controlled trial is therefore to compare the outcomes of arthroscopic ACL repair with suture augmentation to ACL reconstruction for patients with proximal tears in a 1:1 allocation ratio. The primary outcome is the subjective International Knee Documentation Committee (IKDC) score and the secondary outcomes are other patient-reported outcomes, objective outcomes and return to sports. It is hypothesized that patients following ACL repair with suture augmentation have non-inferior primary and secondary outcomes when compared to ACL reconstruction due to the less invasive surgery.

### **Methods**

This study and manuscript have been designed in accordance to the Standard Protocol Items: Recommendations for Interventional Trials (SPIRIT) guidelines.

#### **Study design**

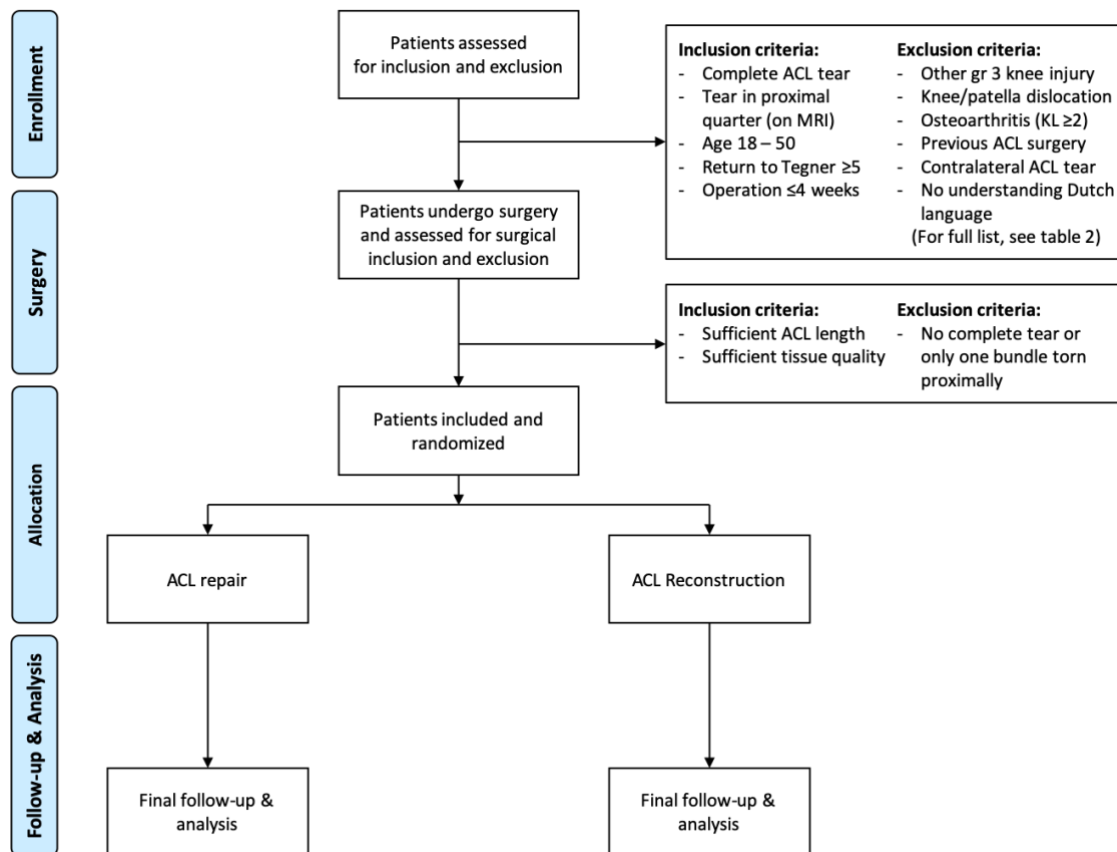
This study is a multicenter prospective RCT with randomization into two treatment arms: (I) arthroscopic ACL repair with suture augmentation and (II) arthroscopic ACL reconstruction surgery. This study is a non-inferiority study with the hypothesis that arthroscopic ACL repair is non-inferior to (equivalent or better than) arthroscopic ACL reconstruction. All patients with proximal tears will be randomized during the operation into one of these treatment arms and will be followed up to ten-years postoperatively.

#### **Study sample**

Potential candidates will be selected from five participating orthopaedic surgery departments, of which one is an academic hospital, three are teaching hospitals and one is a private hospital. Inclusion and exclusion criteria for participation in the study are displayed in Table 1. In general, potential inclusion involves all patients with acute, isolated, complete, proximal ACL tears that have a desire to return to pre-injury activities and exclusion involves all concomitant ligamentous and osteoarthritic injuries and skeletally immature patients. A flowchart of the study is shown in Figure 1. Patients can withdraw their participation in this study at any time point, at which their data will be deleted.

**Table 1.** Inclusion and exclusion criteria for participating in this trial

Inclusion criteria	Exclusion criteria
<b>Pre-operative</b>	
<p>Complete primary ACL tear on physical examination and MRI</p> <p>Tear in proximal quarter on MRI<sup>50,51</sup></p> <p>Age 18 – 50 years<sup>22,52</sup></p> <p>Preinjury Tegner level <math>\geq 5</math> &amp; desired Tegner level <math>\geq 5</math><sup>53</sup></p> <p>Operation within 4 weeks of injury<sup>54</sup></p>	<p>Complete ipsilateral concomitant knee ligament injury requiring surgery</p> <p>Concomitant ipsilateral knee dislocation or patellar dislocation</p> <p>Osteoarthritis KL grade <math>\geq 2</math></p> <p>Previous ipsilateral ACL reconstruction/repair</p> <p>Intra-articular corticosteroids 6 months prior</p> <p>No understanding of Dutch language or not capable of understanding the study and participation</p> <p>No preoperative flexion of 90 degrees</p> <p>Grade 3 pivot shift indicating gross ligament instability that requires additional procedures</p> <p>Gross lower leg malalignment requiring bony osteotomies</p> <p>Muscular, neurological or vascular diseases that influence rehabilitation or surgery</p> <p>Prolonged use medication use of prednisone or cytostatics</p> <p>Pregnancy during injury or surgery</p> <p>Osteoporosis that influence rehabilitation or surgery</p>
<b>Intra-operative</b>	
<p>Sufficient tissue length for retensioning to femoral insertion</p> <p>Sufficient tissue quality to withhold sutures</p>	<p>No complete tear at arthroscopy or only one bundle (AM or PL) with proximal tear</p> <p>Grade 3 or grade 4 cartilage lesions</p>
<p>ACL indicates anterior cruciate ligament; MCL, medial collateral ligament; LCL, lateral collateral ligament; PCL, posterior cruciate ligament; PLC, posterolateral corner.</p>	



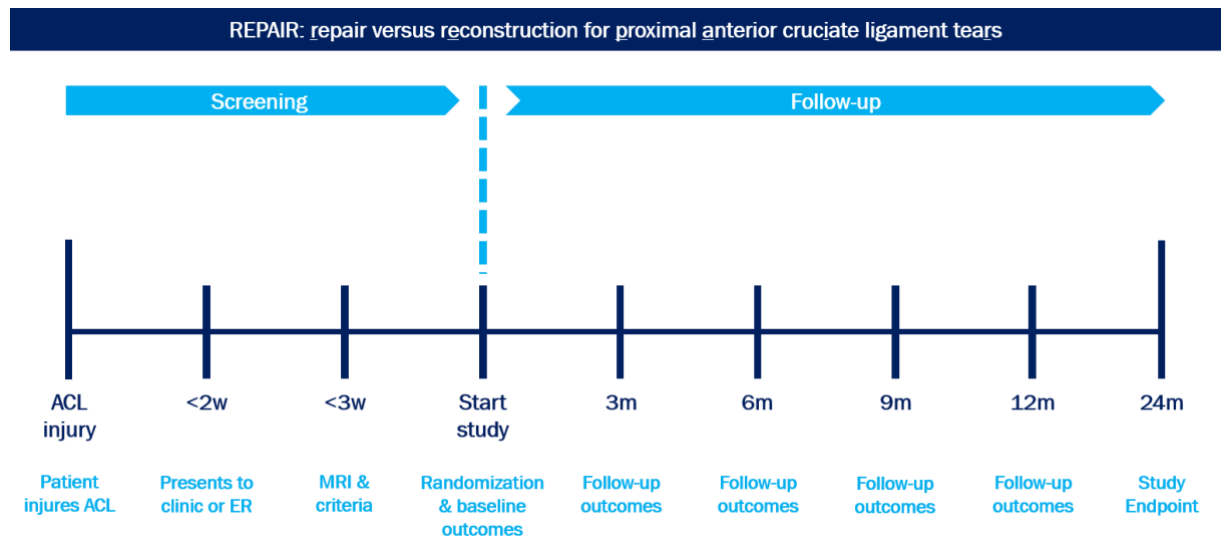
**Figure 1.** Flowchart of the REPAIR-trial

## Randomization

All patients will be consented preoperatively for the study. Patients are taken into the operating room, general or epidural anesthesia is induced, and the leg is prepped and draped for standard arthroscopic knee surgery with a tourniquet high at the upper thigh. Then standard anteromedial and anterolateral portals are created, and the knee is assessed for cartilage, meniscus and ligamentous injuries. After cartilage and meniscus injuries are addressed, the tear type of the ACL and eligibility for this study is assessed. First, it should be confirmed whether a proximal tear is present (i.e., whether the distal remnant of the ACL is of sufficient length to be reattached to the anatomical femoral footprint of the ACL) and whether sufficient tissue quality is present (i.e., whether the ligament remnant is of sufficient quality to withhold suture passage and can be tensioned towards the femur).

If these conditions are present, patients are randomized between both treatment arms, and if these conditions are not present, the patient is excluded, and standard ACL reconstruction will be performed. A computer block randomization of 10 patients per block will be done digitally prior to the study, and the allocation concealment is performed by sequentially numbered, opaque, sealed envelopes containing the name of the procedure in a randomized

order. The envelopes are placed in the operating room and opened when the surgeon deems the ACL tear eligible for the study. A participant timeline is shown in Figure 2.



**Figure 2.** Timeline for patients in the REPAIR-trial

### Surgical techniques

Prior to the start of the trial, a cadaver session will be held in order to standardize the technique of ACL repair and ACL reconstruction for all surgeons and to minimize the learning curve. All surgeons have extensive experience with ACL reconstruction and two out of five participating centers have experience with ACL repair.

The surgical technique of arthroscopic ACL repair has been more extensively described in the literature.<sup>39,43,50</sup> In brief, first the native torn ACL will be sutured with a loop using FiberWire sutures and advanced with one to two passes, so that the sutures exit the avulsed ligament towards the femur. Then, a small tunnel will be drilled from the native femoral insertion towards the lateral epicondyle using an ACL drill guide. The sutures will be passed through a TightRope button along with an additional FiberTape. The sutures and TightRope will be passed through the femoral tunnel and the button will be flipped. Then, a small tunnel will be drilled through the tibia from the anteromedial cortex towards the anterior part of the tibial footprint, and the FiberTape will be channeled through the tibial tunnel and, after cycling the knee, the FiberTape is fixed into the anteromedial cortex using a suture anchor at full extension. Finally, the repair sutures will be tensioned and tied in order to reapproximate the ACL towards the femoral footprint at 90° flexion.

For ACL reconstruction, a standard all-inside autograft hamstring tendon anatomic reconstruction technique is used.<sup>51,52</sup> First, autologous hamstrings (semitendinosus and

gracilis tendon) are harvested to the preference of the surgeon and will be prepared for graft usage with a minimum graft diameter of 8 mm.<sup>53,54</sup> Then, femoral and tibial sockets are independently drilled in retrograde fashion using a FlipCutter drill. The graft is placed into the sockets, the knee is cycled in order to achieve optimal tension of the graft, and the graft is then fixed at the femoral and tibial side using a cortical button.

### **Rehabilitation**

Both treatment arms undergo the same rehabilitation program and consists of a milestone-based program according to the Dutch national guidelines for rehabilitation following ACL reconstruction and consists of three phases.<sup>55-57</sup> The first phase focuses on controlling swelling, restoration of range of motion and return of quadriceps muscle control, and generally takes 4 to 8 weeks. The second phase focuses on resuming light sporting activities and work without symptoms, and phase three focuses on full return to sports activities and heavy work. In case of meniscus repair, the first 6 weeks patients are partial weight bearing, range of motion is restricted to 0-90° and patients are not allowed deep bending or squatting for 4 months. Although the rehabilitation is milestone based and no strict time goals can be set, generally cycling on a stationary bike is allowed at 4-6 weeks, running at 10-12 weeks and return to sports and pivoting activities at a minimum of 9 months postoperatively.

### **Blinding**

Blinding for patients is not possible due to different scars, different postoperative radiographs and practical reasons. However, the data analysis will be performed in blinded fashion.

### **Primary outcomes/endpoint (Table 2)**

The primary outcome of this non-inferiority RCT is the subjective patient reported outcome (PROM) at two-year follow-up consisting of the subjective IKDC score<sup>58</sup> (Dutch validation<sup>59</sup>), as to a recent RCT on a similar topic.<sup>60,61</sup> The primary endpoint is the subjective IKDC at two-years postoperatively. Patients will ultimately be followed for 10 years.

**Table 2.** This chart provides an overview of which outcomes are collected at the different follow-up visits

	Pre	3 mns	6 mns	9 mns	1 yr	2 yrs	5 yrs	10 yrs
<b>Primary outcomes</b>								
IKDC subjective	X	X	X	X	X	X	X	X
<b>Secondary outcomes</b>								
KOOS	X	X	X	X	X	X	X	X
Lysholm	X	X	X	X	X	X	X	X
Forgotten Joint Score	X	X	X	X	X	X	X	X
Satisfaction & pain	X	X	X	X	X	X	X	X
Failure		X	X	X	X	X	X	X
Reoperation		X	X	X	X	X	X	X
Contralateral injury	X	X	X	X	X	X	X	X
IKDC objective	X	X	X	X	X	X	X	X
KT-1000	X	X	X	X	X	X	X	X
Return to sports		X	X	X	X	X	X	X
Tegner score	X	X	X	X	X	X	X	X
ACL-RSI		X	X	X	X	X	X	X
Osteoarthritis (X-ray)	X							X
AE, SAE, SUSAR	X	X	X	X	X	X	X	X

IKDC indicates International Knee Documentation Committee; KOOS, Knee Injury and Osteoarthritis Outcome Score; AE, adverse events; SAE, serious adverse event; SUSAR, Suspected Unexpected Serious Adverse Reaction; Pre, preoperatively; mns, months; yr(s), year(s).

### Secondary outcomes (Table 2)

The secondary outcomes of this RCT are fourfold and consist of (I) other subjective outcomes, (II) objective outcomes, (III) return to sports, and (IV) long-term osteoarthritis.

Other collected PROMs for this study are the Knee Injury and Osteoarthritis Outcome Score (KOOS)<sup>62</sup> (Dutch validation<sup>63</sup>), Lysholm score<sup>64</sup> (Dutch validation<sup>65</sup>), and Forgotten Joint Score (FJS)<sup>28</sup> (Dutch validation<sup>66</sup>). Furthermore, patient satisfaction and pain scores are collected using a numeric rating scale (range 0 – 10).

The objective outcomes consist of failure of ACL repair/graft, reoperation, contralateral injury, and laxity. Failure is defined as a (traumatic) rerupture or symptomatic instability with activities. Reoperation is defined as any new operation on the same knee for any other reason than revision (e.g., symptomatic meniscus tear, hardware irritation, infection or stiffness/arthrofibrosis). Contralateral injury was defined as a complete ACL rupture of the



contralateral ACL. Stability is defined as the laxity found with physical examination using the IKDC objective score form,<sup>67</sup> which includes the Lachman, anterior drawer and pivot shift test, and side-to-side differences is assessed using KT-2000 or Rollimeter.

Return to sports is defined as (I) returning to sports, (II) returning to the same sport, and (III) returning to the preinjury level of sport. The preinjury and postoperative Tegner activity scale are also collected, which enables comparison with other studies<sup>68</sup> (Dutch validation<sup>65</sup>). Finally, confidence of return to sports and fear of reinjury are assessed using the ACL-Return to Sports Index (ACL-RSI) score<sup>69</sup> (Dutch validation<sup>70</sup>).

Osteoarthritis will be reviewed at ten-year follow-up. Radiographs of both knees will be performed, and the operated knee will be compared to (I) the contralateral knee if no operation occurred in that knee, and (II) the ipsilateral knee radiograph preoperatively. The Kellgren-Lawrence (KL) grade will be used to assess the incidence and grades of osteoarthritis.

### **Sample size**

The sample size calculation was based on the primary outcome of this study (subjective IKDC score), similar to another RCT design on this topic.<sup>60</sup> It has been shown that a difference of 8.8 points in the subjective IKDC score is the minimal clinically important difference (MCID).<sup>71</sup> Using this non-inferiority limit of 8.8 points, and a standard deviation of 11 points<sup>42,60,72</sup> along with a two-sided alpha of 0.05, a power of 90%, and a lost-to-follow-up rate of 10%, a total of 37 patients in each group (74 patients in total) are needed to assess the primary outcome of this non-inferiority RCT. This sample size is also sufficient for the MCID of KOOS<sup>73</sup> and Lysholm score.<sup>74</sup> Given the recent studies that showed that 30-40% of the acute tears will have repairable proximal ACL tears,<sup>75,76</sup> we estimate that approximately 200 patients will be needed to be screened preoperatively to achieve the sample size of 74 patients.<sup>77</sup>

### **Statistical analysis**

Both an intention to treat analysis and per protocol analysis will be performed for this non-inferiority study. Comparison of nominal variables between ACL repair and ACL reconstruction will be performed using two-by-two tables with Pearson's Chi-square test or Fisher's exact test (in case one of the cells is <5). For comparison of continuous variables, first tests for normal distribution of values are performed and independent t-tests are used of normal distributed values and non-parametric t-tests are used for not-normally distributed values.

A mixed model analysis for repeated measures will be performed to assess differences between both groups. Furthermore, a multivariate regression analysis will be performed for the primary endpoint of IKDC at two-years follow-up in order to correct for potential confounders. Statistical analysis will be performed using SPSS version 25.0 (IBM Software, Armonk, NY, USA). All tests are two-sided and a p-value of <0.05 is considered statistically significant.

## Discussion

This study reports on the study design of the REPAIR-trial (**R**epair versus **rE**construction for **P**roximal **A**nterior cruciate **I**lgament **tEaR**s). Few studies have examined the outcomes of repair versus reconstruction with favorable outcomes for ACL reconstruction.<sup>22-24</sup> However, these studies were performed over 30 years ago and are limited by the fact that all tear types were repaired rather than only proximal tears and that repair was performed using an arthrotomy.<sup>9,25,78</sup> Recently, four RCT studies have been designed to assess the outcomes of ACL repair<sup>60,79-81</sup> but these are either performed in midsubstance tears,<sup>60,79</sup> assess the outcomes of dynamic intraligamentary stabilization (DIS) versus ACL reconstruction,<sup>60,79</sup> repair versus DIS<sup>80</sup> or Bridge-Enhanced ACL Repair (BEAR) with reconstruction<sup>81</sup>. Our current RCT differs from these studies as only proximal tears will be treated rather than all tear types and as the ligament will be reattached to the femoral footprint in a minimally invasive way.

The renewed interest of repair of proximal tears can be explained by improved understanding of patient selection. Research has shown that proximal tears have a better vascularity compared to midsubstance tears<sup>26</sup> and therefore have excellent healing capacity by reattachment to the femoral wall which is similar to the healing capacity of MCL tears.<sup>27</sup> Both historical studies on open ACL repair,<sup>9,25,78</sup> and more recent studies on repair with DIS (also known as Ligamys) have shown that the clinical outcomes are indeed better when repairing proximal tears. Two studies have shown failure rates of repair with DIS in midsubstance tears of 24% in all patients and 36% in competitive athletes with midsubstance tears.<sup>82,83</sup> Our current study applies strict patient selection criteria of proximal tears and good tissue quality. As the length of distal remnant and possibility of repair can only be assessed intraoperatively, randomization in this study should perform during surgery after the surgeon has confirmed the possibility of repair. Consequently, patients will be consented that they might be excluded during surgery if a non-repairable tear is present, and these patients will undergo standard ACL reconstruction.

It should be noted that there is also a potential disadvantage of ACL repair. By performing ACL surgery in the early phase (since early surgery prevents ligament retraction and preserves tissue quality that is both needed for repair<sup>4,5,84</sup>), it is likely that too many ACL surgeries will be performed. Current day standards recommend that patients following ACL injury will be treated conservatively first as approximately half of the patient may be copers and do not need surgical intervention.<sup>55,85,86</sup> By performing surgery on all ACL injured patients, patients will undergo surgery while they might be copers and do not need surgery. This risk is minimized in this study by only including patients aged 18 – 50 and only patients that desire to return to sports. It would be best if it is known preoperatively which patients will not do well with conservative treatment and ultimately require ACL surgery, as this both increases the chance of performing ACL repair and as early reconstruction outcomes decreases the risk for meniscal and chondral damage<sup>55</sup> at longer follow-up when compared to delayed reconstruction.

Several studies have recently reported good short-term outcomes of arthroscopic ACL repair using different techniques: in some studies femoral fixation consisted of using two suture anchors,<sup>42,44</sup> one suture anchor (for both bundles)<sup>40,45,46</sup> or transosseous tunnels with or without cortical button fixation<sup>39,41,43,50,87</sup>, and some studies used ACL repair without<sup>40,41,45,46</sup> or with<sup>39,43,50,87</sup> additional suture augmentation. For this study, femoral fixation will consist of cortical button fixation with additional suture augmentation (FiberTape) in order to protect the repair in the early phases of rehabilitation, because it has been suggested that additional suture augmentation leads to lower rerupture rates.<sup>42,48</sup>

This study has been designed to assess the outcomes following repair and reconstruction of proximal ACL tears. We hypothesize that the repair treatment is a good treatment for proximal tears as it has potential advantages over ACL reconstruction: the surgery is short and minimally invasive, it has a low complication rate, rehabilitation is easier, and in case ACL repair fails then primary reconstruction surgery can be performed. Non-inferiority of arthroscopic ACL repair compared to arthroscopic ACL reconstruction may lead to a treatment algorithm in which patients with proximal avulsion tears can be repaired in the acute setting whereas patients with midsubstance tears will undergo ACL reconstruction in either the acute or delayed setting.<sup>88,89</sup>

## **Declarations**

### **Ethics approval and consent to participate**

This study has been approved by the Medial Ethics Committee of the Amsterdam Medical Center at the 16<sup>th</sup> of February 2021 under the reference numbers 2020\_322#B202163 and 2020\_322#B202189. The study has been registered at the Netherlands Trial Register (NL9072) on 25<sup>th</sup> of November 2020. All patients will be asked to give their written informed consent for this study and can stop participation of this study at any time point, at which their data will be deleted. The results of this study will be presented at national and international conferences and peer-reviewed journals in a de-identified manner.

### **Consent for publication**

Not applicable

### **Availability of data and materials**

Available at study publication

### **Competing interests**

The authors declare that they have no competing interests

### **Funding**

This study is funded by the Dutch Association of Arthroscopy (NVA) for which the authors are grateful. This funding source had no role in the design of this study and will not have any role during its execution, analyses, interpretation of the data, or decision to submit results.

### **Authors' contributions**

JPvdL conceived of the study. AvN, GMMJK, MVR and JPvdL initiated the study design. INS provided statistical expertise in clinical trial design and INS and HDV are conducting the primary statistical analysis. MVR, RvD, MLMF, GTTH, RAGH, WAvdW, AvN and GMMJK will be performing the operations. All authors contributed to refinement of the study protocol and approved the final manuscript.

## References

1. Robson AW. VI. Ruptured Crucial Ligaments and their Repair by Operation. *Ann Surg.* 1903;37(5):716-718.
2. Palmer I. On the injuries to the ligaments of the knee joint. *Acta Orthop Scand.* 1938;53.
3. Palmer I. On the injuries to the ligaments of the knee joint: a clinical study. 1938. *Clin Orthop Relat Res.* 2007;454:17-22.
4. O'Donoghue DH. An analysis of end results of surgical treatment of major injuries to the ligaments of the knee. *J Bone Joint Surg Am.* 1955;37(1):1-13.
5. O'Donoghue DH. Surgical treatment of fresh injuries to the major ligaments of the knee. *J Bone Joint Surg Am.* 1950;32 A(4):721-738.
6. van der List WP. De operatieve behandeling van de bandverscheuringen van de knie. *Ned Tijdschr Geneesk.* 1964;108:830-833.
7. Liljedahl SO, Lindvall N, Wetterfors J. Early diagnosis and treatment of acute ruptures of the anterior cruciate ligament; a clinical and arthrographic study of forty-eight cases. *J Bone Joint Surg Am.* 1965;47(8):1503-1513.
8. Feagin JA, Abbott HG, Rokous JR. The isolated tear of the anterior cruciate ligament. *J Bone Joint Surg Am.* 1972;54(6):1340-1341.
9. van der List JP, DiFelice GS. Primary repair of the anterior cruciate ligament: A paradigm shift. *Surgeon.* 2017;15(3):161-168.
10. Feagin JA, Jr., Curl WW. Isolated tear of the anterior cruciate ligament: 5-year follow-up study. *Am J Sports Med.* 1976;4(3):95-100.
11. Cabitza P, Colombo A, Verdoia C. Follow-up of results obtained with O'Donoghue's technique in the repair of recent lesions of the anterior cruciate ligament. *Minerva Ortop.* 1978;29(12):579-583.
12. Nixon JE. Acute injuries of the anterior cruciate ligament of the knee: primary repair. *Bull N Y Acad Med.* 1980;56(5):483-487.
13. Marshall JL, Warren RF, Wickiewicz TL. Primary surgical treatment of anterior cruciate ligament lesions. *Am J Sports Med.* 1982;10(2):103-107.
14. Warren RF. Primary repair of the anterior cruciate ligament. *Clin Orthop Relat Res.* 1983 (172):65-70.
15. Marcacci M, Spinelli M, Chiellini F, Buccolieri V. Notes on 53 cases of immediate suture of acute lesions of the anterior cruciate ligament. *Ital J Orthop Traumatol.* 1985;7(2):69-79.
16. Sherman MF, Bonamo JR. Primary repair of the anterior cruciate ligament. *Clin Sports Med.* 1988;7(4):739-750.
17. Odensten M, Lysholm J, Gillquist J. Suture of fresh ruptures of the anterior cruciate ligament. A 5-year follow-up. *Acta Orthop Scand.* 1984;55(3):270-272.
18. Engebretsen L, Benum P, Sundalsvoll S. Primary suture of the anterior cruciate ligament A 6-year follow-up of 74 cases. *Acta Orthop Scand.* 1989;60(5):561-564.
19. Jonsson T, Peterson L, Renstrom P. Anterior cruciate ligament repair with and without augmentation. A prospective 7-year study of 51 patients. *Acta Orthop Scand.* 1990;61(6):562-566.
20. Kaplan N, Wickiewicz TL, Warren RF. Primary surgical treatment of anterior cruciate ligament ruptures. A long-term follow-up study. *Am J Sports Med.* 1990;18(4):354-358.
21. Sherman MF, Lieber L, Bonamo JR, Podesta L, Reiter I. The long-term followup of primary anterior cruciate ligament repair. Defining a rationale for augmentation. *Am J Sports Med.* 1991;19(3):243-255.
22. Engebretsen L, Benum P, Fasting O, Molster A, Strand T. A prospective, randomized study of three surgical techniques for treatment of acute ruptures of the anterior cruciate ligament. *Am J Sports Med.* 1990;18(6):585-590.
23. Grontvedt T, Engebretsen L. Comparison between two techniques for surgical repair of the acutely torn anterior cruciate ligament. A prospective, randomized follow-up study of 48 patients. *Scand J Med Sci Sports.* 1995;5(6):358-363.
24. Grontvedt T, Engebretsen L, Benum P, Fasting O, Molster A, Strand T. A prospective, randomized study of three operations for acute rupture of the anterior cruciate ligament. Five-year follow-up of one hundred and thirty-one patients. *J Bone Joint Surg Am.* 1996;78(2):159-168.
25. van der List JP, DiFelice GS. Role of tear location on outcomes of open primary repair of the anterior cruciate ligament: a systematic review of historical studies. *Knee.* 2017;24(5):898-908.

26. Toy BJ, Yeasting RA, Morse DE, McCann P. Arterial supply to the human anterior cruciate ligament. *J Athl Train.* 1995;30(2):149-152.
27. Nguyen DT, Ramwadhoebe TH, van der Hart CP, Blankevoort L, Tak PP, van Dijk CN. Intrinsic healing response of the human anterior cruciate ligament: An histological study of reattached ACL remnants. *J Orthop Res.* 2014;32(2):296-301.
28. Behrend H, Zdravkovic V, Giesinger JM, Giesinger K. Joint awareness after ACL reconstruction: patient-reported outcomes measured with the Forgotten Joint Score-12. *Knee Surg Sports Traumatol Arthrosc.* 2017 Oct 19;25(5):1454-1460.
29. Vermeijden HD, van der List JP, O'Brien R, DiFelice GS. Patients Forget About Their Operated Knee More Following Arthroscopic Primary Repair of the Anterior Cruciate Ligament Than Following Reconstruction. *Arthroscopy.* 2020;36(3):797-804.
30. Murray MM. Current status and potential of primary ACL repair. *Clin Sports Med.* 2009;28(1):51-61.
31. Adachi N, Ochi M, Uchio Y, Iwasa J, Ryoke K, Kuriwaka M. Mechanoreceptors in the anterior cruciate ligament contribute to the joint position sense. *Acta Orthop Scand.* 2002;73(3):330-334.
32. Gao F, Zhou J, He C, Ding J, Lou Z, Xie Q, Li H, Li F, Li G. A Morphologic and Quantitative Study of Mechanoreceptors in the Remnant Stump of the Human Anterior Cruciate Ligament. *Arthroscopy.* 2016;32(2):273-280.
33. Murray MM, Fleming BC, Badger GJ, Team BT, Freiburger C, Henderson R, Barnett S, Kiapour A, Ecklund K, Proffen B, Sant N, Kramer DE, Micheli LJ, Yen YM. Bridge-Enhanced Anterior Cruciate Ligament Repair Is Not Inferior to Autograft Anterior Cruciate Ligament Reconstruction at 2 Years: Results of a Prospective Randomized Clinical Trial. *Am J Sports Med.* 2020 May;48(6):1305-1315.
34. van der List JP, DiFelice GS. Range of motion and complications following primary repair versus reconstruction of the anterior cruciate ligament. *Knee.* 2017;24(4):798-807.
35. Andriolo L, Filardo G, Kon E, Ricci M, Della Villa F, Della Villa S, Zaffagnini S, Marcacci M. Revision anterior cruciate ligament reconstruction: clinical outcome and evidence for return to sport. *Knee Surg Sports Traumatol Arthrosc.* 2015 Oct;23(10):2825-2845.
36. Arianjam A, Inacio MCS, Funahashi TT, Maletis GB. Analysis of 2019 Patients Undergoing Revision Anterior Cruciate Ligament Reconstruction From a Community- Based Registry. *Am J Sports Med.* 2017:363546517700882.
37. van der List JP, Vermeijden HD, O'Brien R, DiFelice GS. Anterior cruciate ligament reconstruction following failed primary repair: surgical technique and a report of three cases. *Minerva Ortop Traumatol.* 2019;70:70-77.
38. DiFelice GS, Villegas C, Taylor SA. Anterior Cruciate Ligament Preservation: Early Results of a Novel Arthroscopic Technique for Suture Anchor Primary Anterior Cruciate Ligament Repair. *Arthroscopy.* 2015;31(11):2162-2171.
39. Smith JO, Yasen SK, Palmer HC, Lord BR, Britton EM, Wilson AJ. Paediatric ACL repair reinforced with temporary internal bracing. *Knee Surg Sports Traumatol Arthrosc.* 2016;24(6):1845-1851.
40. Bigoni M, Gaddi D, Gorla M, Munegato D, Pungitore M, Piatti M, Turati M. Arthroscopic anterior cruciate ligament repair for proximal anterior cruciate ligament tears in skeletally immature patients: Surgical technique and preliminary results. *Knee.* 2017;24(1):40-48.
41. Mukhopadhyay R, Shah N, Vakta R, Bhatt J. ACL femoral avulsion repair using suture pull-out technique: A case series of thirteen patients. *Chin J Traumatol.* 2018;21(6):352-355.
42. Jonkergouw A, van der List JP, DiFelice GS. Arthroscopic primary repair of proximal anterior cruciate ligament tears: outcomes of the first 56 consecutive patients and the role of additional internal bracing. *Knee Surg Sports Traumatol Arthrosc.* 2018;27(1):21-28.
43. Heusdens CHW, Hopper GP, Dossche L, Roelant E, Mackay GM. Anterior cruciate ligament repair with Independent Suture Tape Reinforcement: a case series with 2-year follow-up. *Knee Surg Sports Traumatol Arthrosc.* 2019;27(1):60-67.
44. DiFelice GS, van der List JP. Clinical Outcomes of Arthroscopic Primary Repair of Proximal Anterior Cruciate Ligament Tears Are Maintained at Midterm Follow-up. *Arthroscopy.* 2018;34(4):1085-1093.
45. Hoffmann C, Friederichs J, von Ruden C, Schaller C, Buhren V, Moessmer C. Primary single suture anchor re-fixation of anterior cruciate ligament proximal avulsion tears leads to good functional mid-term results: a preliminary study in 12 patients. *J Orthop Surg Res.* 2017;12(1):171.

46. Achtnich A, Herbst E, Forkel P, Metzlaß S, Sprenger F, Imhoff AB, Petersen W. Acute Proximal Anterior Cruciate Ligament Tears: Outcomes After Arthroscopic Suture Anchor Repair Versus Anatomic Single-Bundle Reconstruction. *Arthroscopy*. 2016;32(12):2562-2569.
47. Vermeijden HD, Yang XA, van der List JP, DiFelice GS. Role of age on success of arthroscopic primary repair of proximal anterior cruciate ligament tears. *Arthroscopy*. 2020;10.1016/j.arthro.2020.11.024.
48. van der List JP, Vermeijden HD, Sierevelt IN, DiFelice GS, van Noort A, Kerkhoffs GMMJ. Arthroscopic primary repair of proximal anterior cruciate ligament tears seems safe but higher level of evidence is needed: a systematic review and meta-analysis of recent literature. *Knee Surg Sports Traumatol Arthrosc*. 2020;28(6):1946-1957.
49. Hopper GP, Aithie JMS, Jenkins JM, Wilson WT, Mackay GM. Satisfactory patient-reported outcomes at 5 years following primary repair with suture tape augmentation for proximal anterior cruciate ligament tears. *Knee Surgery, Sports Traumatology, Arthroscopy*. 2021;10.1007/s00167-021-06485-z.
50. Mackay GM, Blyth MJ, Anthony I, Hopper GP, Ribbans WJ. A review of ligament augmentation with the InternalBrace: the surgical principle is described for the lateral ankle ligament and ACL repair in particular, and a comprehensive review of other surgical applications and techniques is presented. *Surg Technol Int*. 2015;26:239-255.
51. Connaughton AJ, Geeslin AG, Uggen CW. All-inside ACL reconstruction: How does it compare to standard ACL reconstruction techniques? *Journal of Orthopaedics*. 2017;14(2):241-246.
52. Vinagre G, Kennedy NI, Chahla J, Cinque ME, Hussain ZB, Olesen ML, LaPrade RF. Hamstring Graft Preparation Techniques for Anterior Cruciate Ligament Reconstruction. *Arthrosc Tech*. 2017 Dec;6(6):e2079-e2084.
53. Fu CW, Chen WC, Lu YC. Is all-inside with suspensory cortical button fixation a superior technique for anterior cruciate ligament reconstruction surgery? A systematic review and meta-analysis. *BMC Musculoskelet Disord*. 2020;21(1):445.
54. Tang SP, Wan KH, Lee RH, Wong KK, Wong KK. Influence of hamstring autograft diameter on graft failure rate in Chinese population after anterior cruciate ligament reconstruction. *Asia Pac J Sports Med Arthrosc Rehabil Technol*. 2020;22:45-48.
55. Meuffels DE, Poldervaart MT, Diercks RL, Fievez AW, Patt TW, Hart CP, Hammacher ER, Meer F, Goedhart EA, Lenssen AF, Muller-Ploeger SB, Pols MA, Saris DB. Guideline on anterior cruciate ligament injury. *Acta Orthop*. 2012 Aug;83(4):379-386.
56. van Melick N, van Cingel RE, Brooijmans F, Neeter C, van Tienen T, Hullegie W, Nijhuis-van der Sanden MW. Evidence-based clinical practice update: practice guidelines for anterior cruciate ligament rehabilitation based on a systematic review and multidisciplinary consensus. *Br J Sports Med*. 2016;50(24):1506-1515.
57. Engelen-van Melick N, Hullegie W, Brooijmans F, Hendriks E, Neeter C, Van Tienen T, van Cingel R. KNGF Evidence Statement; Revalidatie na voorste-kruisbandreconstructie. 2014.
58. Irrgang JJ, Anderson AF, Boland AL, Harner CD, Kurosaka M, Neyret P, Richmond JC, Shelborne KD. Development and validation of the international knee documentation committee subjective knee form. *Am J Sports Med*. 2001;29(5):600-613.
59. Haverkamp D, Sierevelt IN, Breugem SJ, Lohuis K, Blankevoort L, van Dijk CN. Translation and validation of the Dutch version of the International Knee Documentation Committee Subjective Knee Form. *Am J Sports Med*. 2006;34(10):1680-1684.
60. Boer BC, Hoogeslag RAG, Brouwer RW, Demmer A, Huis In 't Veld R. Self-reported functional recovery after reconstruction versus repair in acute anterior cruciate ligament rupture (ROTOR): a randomized controlled clinical trial. *BMC Musculoskelet Disord*. 2018 Apr 20;19(1):127.
61. Hoogeslag RAG, Brouwer RW, Boer BC, de Vries AJ, Huis in 't Veld R. Acute Anterior Cruciate Ligament Rupture: Repair or Reconstruction? Two-Year Results of a Randomized Controlled Clinical Trial. *Am J Sports Med*. 2019;47(3):567-577.
62. Roos EM, Roos HP, Lohmander LS, Ekdahl C, Beynon BD. Knee Injury and Osteoarthritis Outcome Score (KOOS)--development of a self-administered outcome measure. *J Orthop Sports Phys Ther*. 1998 Aug;28(2):88-96.
63. de Groot IB, Favejee MM, Reijman M, Verhaar JA, Terwee CB. The Dutch version of the Knee Injury and Osteoarthritis Outcome Score: a validation study. *Health Qual Life Outcomes*. 2008 Feb 26;6:16.

64. Lysholm J, Gillquist J. Evaluation of knee ligament surgery results with special emphasis on use of a scoring scale. *Am J Sports Med.* 1982;10(3):150-154.
65. Eshuis R, Lentjes GW, Tegner Y, Wolterbeek N, Veen MR. Dutch Translation and Cross-cultural Adaptation of the Lysholm Score and Tegner Activity Scale for Patients With Anterior Cruciate Ligament Injuries. *J Orthop Sports Phys Ther.* 2016 Nov;46(11):976-983.
66. Shadid MB, Vinken NS, Marting LN, Wolterbeek N. The Dutch version of the Forgotten Joint Score: test-retesting reliability and validation. *Acta Orthop Belg.* 2016 Mar;82(1):112-118.
67. Hefti F, Muller W, Jakob RP, Staubli HU. Evaluation of knee ligament injuries with the IKDC form. *Knee Surg Sports Traumatol Arthrosc.* 1993;1(3-4):226-234.
68. Tegner Y, Lysholm J. Rating systems in the evaluation of knee ligament injuries. *Clin Orthop Relat Res.* 1985 (198):43-49.
69. Webster KE, Feller JA, Lambros C. Development and preliminary validation of a scale to measure the psychological impact of returning to sport following anterior cruciate ligament reconstruction surgery. *Phys Ther Sport.* 2008 Feb;9(1):9-15.
70. Slagters AJ, Reininga IHF, van den Akker-Scheek I. The Dutch language anterior cruciate ligament return to sport after injury scale (ACL-RSI) – validity and reliability. *J Sports Sci.* 2017;35(4):393-401.
71. Irrgang JJ, Anderson AF, Boland AL, Harner CD, Neyret P, Richmond JC, Shelbourne KD. Responsiveness of the International Knee Documentation Committee Subjective Knee Form. *Am J Sports Med.* 2006 Oct;34(10):1567-1573.
72. Li YL, Ning GZ, Wu Q, Wu QL, Li Y, Hao Y, Feng SQ. Single-bundle or double-bundle for anterior cruciate ligament reconstruction: a meta-analysis. *Knee.* 2014 Jan;21(1):28-37.
73. Aga C, Risberg MA, Fagerland MW, Johansen S, Troan I, Heir S, Engebretsen L. No Difference in the KOOS Quality of Life Subscore Between Anatomic Double-Bundle and Anatomic Single-Bundle Anterior Cruciate Ligament Reconstruction of the Knee: A Prospective Randomized Controlled Trial With 2 Years' Follow-up. *Am J Sports Med.* 2018 Aug;46(10):2341-2354.
74. Briggs KK, Lysholm J, Tegner Y, Rodkey WG, Kocher MS, Steadman JR. The reliability, validity, and responsiveness of the Lysholm score and Tegner activity scale for anterior cruciate ligament injuries of the knee: 25 years later. *Am J Sports Med.* 2009 May;37(5):890-897.
75. van der List JP, DiFelice GS. Preoperative magnetic resonance imaging predicts eligibility for arthroscopic primary anterior cruciate ligament repair. *Knee Surg Sports Traumatol Arthrosc.* 2017 July 13;26(2):660-671.
76. van der List JP, Mintz DN, DiFelice GS. The location of anterior cruciate ligament tears: a prevalence study using magnetic resonance imaging. *Orthop J Sports Med.* 2017;5(6):2325967117709966.
77. Frobell RB, Lohmander LS, Roos EM. The challenge of recruiting patients with anterior cruciate ligament injury of the knee into a randomized clinical trial comparing surgical and non-surgical treatment. *Contemp Clin Trials.* 2007 May;28(3):295-302.
78. van Eck CF, Limpisvasti O, ElAttrache NS. Is There a Role for Internal Bracing and Repair of the Anterior Cruciate Ligament? A Systematic Literature Review. *Am J Sports Med.* 2017;46(9):2291-2298.
79. Descamps P, Silbert H. Ligamys Technique Versus Standard Technique for the Anterior Cruciate Ligament Rupture. <https://clinicaltrials.gov/show/nct02740452> [Internet]. 2016. Available from: <https://www.cochranelibrary.com/central/doi/10.1002/central/CN-01595312/full>.
80. Heusdens CH. Single-blind, Multi-centre, Randomized Controlled Trial Comparing Ligamys Anterior Cruciate Ligament (ACL) Repair, Internal Bracing ACL Repair and Conventional ACL Reconstruction for Relative Clinical Efficacy and Economic Benefit. <https://clinicaltrials.gov/show/nct03441295> [Internet]. 2018. Available from: <https://www.cochranelibrary.com/central/doi/10.1002/central/CN-01523203/full>.
81. Murray MM, Yeng YM. A Prospective, Randomized, Controlled, Clinical Trial Evaluating the Non-Inferiority of Bridge-Enhanced Anterior Cruciate Ligament Repair (BEAR) to Anterior Cruciate Ligament Reconstruction With an Autologous Tendon Graft (ACLR). <https://clinicaltrials.gov/show/nct02664545> [Internet]. 2016. Available from: <https://www.cochranelibrary.com/central/doi/10.1002/central/CN-01555321/full>.
82. Evangelopoulos DS, Kohl S, Schwienbacher S, Gantenbein B, Exadaktylos A, Ahmad SS. Collagen application reduces complication rates of mid-substance ACL tears treated with dynamic intraligamentary stabilization. *Knee Surg Sports Traumatol Arthrosc.* 2017 Aug;25(8):2414-2419.



83. Krismer AM, Gousopoulos L, Kohl S, Ateschrang A, Kohlhof H, Ahmad SS. Factors influencing the success of anterior cruciate ligament repair with dynamic intraligamentary stabilisation. *Knee Surg Sports Traumatol Arthrosc.* 2017;25(12):3923-3928.
84. Murray MM, Martin SD, Martin TL, Spector M. Histological changes in the human anterior cruciate ligament after rupture. *J Bone Joint Surg Am.* 2000 Oct;82-A(10):1387-1397.
85. Frobell RB, Roos EM, Roos HP, Ranstam J, Lohmander LS. A Randomized Trial of Treatment for Acute Anterior Cruciate Ligament Tears. *N Engl J Med.* 2010;363(4):331-342.
86. van der List JP, Hagemans FJA, Hofstee DJ, Jonkers FJ. The Role of Patient Characteristics on the Success of Nonoperative Treatment of Anterior Cruciate Ligament Injuries. *Am J Sports Med.* 2020;48(7):1657-1664.
87. Dabis J, Yasen SK, Foster AJ, Pace JL, Wilson AJ. Paediatric proximal ACL tears managed with direct ACL repair is safe, effective and has excellent short-term outcomes. *Knee Surg Sports Traumatol Arthrosc.* 2020 Aug;28(8):2551-2556.
88. Träger D, Pohle K, Tschirner W. Anterior cruciate ligament suture in comparison with plasty. A 5-year follow-up study. *Arch Orthop Trauma Surg.* 1995;114(5):278-280.
89. van der List JP, DiFelice GS. Preservation of the anterior cruciate ligament: A treatment algorithm based on tear location and tissue quality. *Am J Orthop (Belle Mead NJ).* 2016;45(7):E393-E405.



# **Chapter 13**

**General discussion, future perspectives,  
and conclusions**

## General discussion

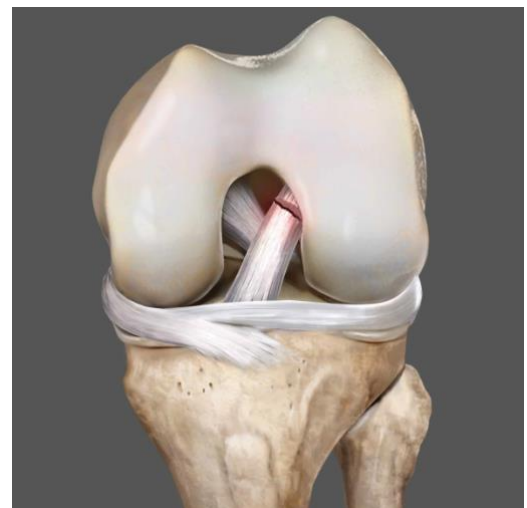In this thesis, we reviewed the history of primary ACL repair, identified factors that are important for patient selection of ACL repair, and assessed the early outcomes of arthroscopic primary repair. Taking the studies of this thesis into account, we can conclude that there might be a role for arthroscopic primary repair for the select group of patients with proximal tears and sufficient tissue quality, and that surgical treatment should be personalized rather than using a “one size fits all” approach. In this general discussion, we evaluate the answers to the research questions that were formulated in the introduction of this thesis. Finally, the future directions for research and the role of arthroscopic primary repair in the modern treatment algorithm for ACL injuries is discussed.

### 1. Which factors led to the abandoning of primary ACL repair in the historical literature?

In the first part of this thesis, the history of open primary repair was critically reviewed (**chapter 2** and **chapter 3**). Several factors were recognized which led to a paradigm shift of replacing primary repair by reconstruction surgery for all patients, rather than only abandoning primary repair for midsubstance tears

#### Tear location and tissue quality

The role of tear location and tissue quality were not recognized until very late in the primary repair era. Although several authors had suggested that tear location may play a role in the (mid-term) outcomes of primary repair,<sup>1-5</sup> Sherman et al. were the first to perform a subgroup analysis and show this correlation in 1991.<sup>6</sup> Because the role of tear location and tissue quality on patient outcomes was largely unknown during the open primary repair era, several authors concluded that the outcomes of open primary repair were unpredictable.<sup>7</sup> As a result, several prospective trials were started to compare primary ACL repair with ACL reconstruction. Unfortunately, the enrollment of patients in the prospective studies was already completed *before* the role of tear location started to become recognized.<sup>8-14</sup> As a result, these studies, that were mostly published *after* the study by Sherman et al., showed that open primary repair was an unpredictable procedure. Subsequently, the treatment algorithm shifted from primary repair to reconstruction for all patients (**chapter 2**). In our systematic review (**chapter 3**), we reviewed the outcomes of these historical studies and aimed to stratify these by tear location.



**Figure 1.** A schematic drawing of a proximal avulsion (type I) tear

Although a thorough meta-analysis was not possible due to the lack of comparative studies, it was found that indeed good outcomes were reported in the studies with proximal tears. Some studies recognized better outcomes after repair of proximal tears and decided to solely use primary repair for proximal tears (Figure 1), and use reconstruction for midsubstance tears.<sup>15-18</sup> Because of the results in the aforementioned prospective trials, primary repair was ultimately abandoned for all tear types rather than only for midsubstance tears, and it can be concluded that a paradigm shift was present in the historical literature on primary ACL repair. Reviewing these historical results, studies have shown that good outcomes of primary repair are possible when only selecting to repair proximal ACL tears. Modern developments, such as MRI, may help orthopaedic surgeon with appropriate patient selection.

The rationale behind the better outcomes of primary repair can be explained by the findings that the proximal part of the ligament has the best vascularity.<sup>19</sup> Recent studies showed that the healing capacity of proximal ACL tears is equivalent to medial collateral ligament (MCL) tears, of which the general consensus is that these tears can heal.<sup>20</sup> Furthermore, proximal tears often have an intact synovial sheet (chapter 5) which might be associated with further preservation of vessels and nerve fibers that are known to run in this synovial sheet. Midsubstance tears, on the contrary, have inferior vascularity and the synovial sheet is often ruptured, and consequently do not form a clot and scar tissue that is needed for ligament healing.<sup>21,22</sup> A research group led by Martha Murray has examined the potential of primary repair of midsubstance tears and added a biological scaffold to their repair in order to protect it from the synovial fluid. Although the results of experimental studies are promising, longer-term outcomes remain to be reported.<sup>23</sup> Furthermore, this technique is currently invasive as it is performed via an arthrotomy and patients are postoperatively immobilized. This treatment has to be further improved to avoid errors that were made in the historical literature. In the future, it might be possible that tears with sufficient tissue length (proximal tears) and tissue quality are treated with arthroscopic primary ACL repair as described in this thesis, whereas tears with insufficient tissue length could be repaired with the addition of a biological scaffold.

### **Arthrotomy**

Another factor that has contributed to the historical abandonment of primary repair was the invasiveness of the surgery. In the 1970s, surgery consisted of an arthrotomy for both primary repair and reconstruction surgery. In this time, it was important to have a “one-stop surgery” rather than having to undergo multiple (revision) surgeries with the risk of adhesions and pain following these invasive surgeries. Since reconstruction surgery was perceived as more reliable, it was reasonable to prefer this treatment in those days. Furthermore, after these treatments, patients often complained of pain and stiffness in their knee due to the invasive character of the surgery. With the modern developments in arthroscopy, primary repair can now be performed using arthroscopy and is less invasive than ACL reconstruction as no (large) tunnels are drilled and no grafts are required. These modern advances have therefore

significantly changed the risk-benefit ratio of primary repair versus reconstruction: historically, the more reliable reconstruction surgery was preferred over primary repair as both surgeries were invasive, while these days arthroscopic primary ACL repair may be preferred in the select group of patients with proximal tears given the less invasive nature of the surgery.

### **Postoperative immobilization**

A third factor that has contributed to the abandonment of primary repair in the historical literature was the postoperative regimen. In the era of open primary repair, joints were often postoperatively immobilized for four to six weeks. As a result, up to 70% of patients complained of stiffness and patellofemoral symptoms.<sup>24-26</sup> Pioneering work from Shelbourne et al. has taught us, however, that early postoperative range of motion (ROM) exercises significantly improve the postoperative stiffness, patellofemoral pain and decreases motion loss when compared to joint immobilization.<sup>27</sup> The rehabilitation consisting of joint immobilization has led to inferior outcomes of primary repair, while in modern rehabilitation, patients are encouraged to regain ROM early to prevent these symptoms and optimize outcomes of ACL surgery.<sup>28</sup>

It is important to carefully review the historical literature on outcomes of primary repair as several confounders are present in these studies. When considering the aforementioned factors, primary repair may have been prematurely abandoned for all tear types and one may expect better outcomes performing primary repair only in carefully selected patients (i.e. those with proximal tears and good tissue quality), using non-absorbable sutures and using arthroscopy.

## **2. Which patients are candidates for primary ACL repair, and can we preoperatively identify them?**

The historical studies showed that good outcomes are possible when treating patients with proximal tears and sufficient tissue quality, and this part of the thesis has focused on the preoperative identification of those patients eligible for arthroscopic ACL repair.

First, we performed a retrospective study (**chapter 4**) in which we assessed the role of several patient characteristics and radiological parameters on the success of conservative treatment of ACL injuries, including the role of tear location. This study is important because it assesses if proximal tears have a different course with conservative treatment compared to midsubstance tears, especially since primary ACL repair is performed acutely and conservative treatment cannot be performed when performing acute surgery. It is possible that patients with proximal tears may have better outcomes of conservative treatment compared to patients with midsubstance tears given the aforementioned better vascularity<sup>19</sup> and healing potential.<sup>20</sup> In this study, no clear predictive role for tear location on coping with ACL

deficiency was noted. Although in the univariate analysis a trend was noted towards more proximal tears in the coping group, a confounding effect of age was noted, as patients with higher age are more often copers with ACL deficiency and patients with higher age also have more often proximal tears (**chapter 5** and **chapter 7**). Multivariate analysis showed no predictive role of tear location on coping with ACL deficiency. This study showed that proximal tears do not seem to result in better coping with ACL deficiency, and this suggests that the proximal ACL tears might need fixation to the femoral insertion site (repair) to heal and that this healing will not occur without fixation of the remnant.<sup>29</sup>

At the start of this thesis, it was unknown how many patients were eligible for primary repair. Some studies have stated that most tears are proximal tears,<sup>18,30</sup> whereas others stated that the numbers of patients with proximal tears is negligible.<sup>31,32</sup> Therefore, the goal was to assess the prevalence of tear locations of the ACL. A classification system for different tear types, based on both clinical relevance and feasibility, was therefore designed to assess the ACL tear location and this was done during meetings with a fellowship trained musculoskeletal radiologist and orthopaedic surgeon. We presented this classification system first in a review article<sup>33</sup> along with clinical relevance of the system with the different surgical preservation techniques.<sup>34</sup> With this classification system, it was then possible to determine the incidence of different tear types on MRI. It was noted that 42% of all ACL tears occurred in the proximal quarter of the ligament, of which 16% had a tear in the top 10% and 26% had a tear in the proximal 10 – 25% of the ligament, whereas the majority of tears (52%) occurred in the middle half of the ligament (25% – 75% of distal-proximal length) (**chapter 5**).

In order to convert these numbers to the percentage of patients eligible for primary repair, it is necessary to correlate these findings to arthroscopy. In **chapter 6**, it was noted that 90% of the MRI type I tears and 46% of the MRI type II tears were considered arthroscopically repairable by the orthopaedic surgeon during surgery. Preoperatively, the tissue quality on MRI was also scored and found to be correlated with the final eligibility for repair intraoperatively. It was especially helpful for type II tears in order to differentiate between repairable tears (good tissue quality) and patients that had to undergo reconstruction surgery (fair or poor tissue quality). Using these numbers and the estimated prevalence of ACL injuries, it can be estimated that approximately 70,000 out of 200,000 patients in the United States and 3,500 out of 10,000 patients in the Netherlands might be potential candidates for arthroscopic primary ACL repair if all tears would have been treated acutely. Although this is only a rough estimation, partially based on the technical skills of one surgeon and it assumes that all tears are acute tears, these numbers indicate that in a significant group of patients this treatment could be performed. It should be highlighted that most of these numbers are based on preoperative MRI while the final decision for arthroscopic primary ACL repair is ultimately made during arthroscopy. It would be recommended to start with the arthroscopic procedure, rather than with graft harvesting, in order to assess the possibility of ligament preservation.

In our next study (**chapter 7**) we aimed to understand which factors predict the (intraoperative) possibility of arthroscopic primary repair in a larger cohort of patients treated by one experienced surgeon. It was noted that older age, lower BMI and no lateral meniscus injury were predictive of the possibility of primary repair, whereas gender and type of sports injury (i.e. skiing or football injury) were not found to be independent predictors of primary repair. Furthermore, a 3.3 higher chance of primary repair was noted when surgery was performed within 4 weeks of surgery when compared to later than 4 weeks of surgery. Based on this data, it is recommended that surgery will be performed within 4 weeks of surgery if primary repair is one of the surgical options for a patient. Finally, a significant learning effect was noted in our cohort indicating that the surgeon is more able to perform primary repair with more years of experience with this surgery.

This timing of surgery within 4 weeks is, however, not in line with the current Dutch guidelines on ACL surgery, in which there is an important role for attempting conservative treatment first in patients with ACL injury.<sup>35</sup> The guideline states that conservative treatment should be attempted first and that surgery should be reserved for patients that are symptomatic despite neuromuscular training. The rationale behind this is that surgery can be prevented in potential copers or in patients who want to adjust their activity level and prevent surgery. In young and more active patients who participate in sports and pivoting activities, however, the likelihood of successful conservative treatment is fairly low (between 40% and 50%),<sup>36,37</sup> and has a low return to sports rate.<sup>38</sup> Furthermore, as conservative treatment fails in most of the younger and active patients, this will cause a delay from injury to surgery that is associated with a higher risk of meniscal and cartilage injuries.<sup>35,36,39-41</sup> In addition, some recent studies have suggested that outcomes of early reconstruction might be better than delayed reconstruction<sup>42-44</sup> and have lower costs,<sup>45</sup> while there is no increased risk of arthrofibrosis with modern-day surgery.<sup>46,47</sup> It is therefore important to assess which patients might be potential copers with their ACL injury and start conservative treatment in those patients, whereas early surgery seems to have benefits in potential non-copers. This means that potential copers and non-copers should be identified early, and that a shift from delaying surgery to more acute surgery (for example 1 – 4 weeks after injury) might be beneficial for patients that are unlikely to be copers given the aforementioned advantages with early ACL reconstruction. When this treatment algorithm is applied, patients with proximal tears might then also benefit from primary repair as is outlined in the next discussion section.

### **3. What are the safety and early outcomes of arthroscopic primary ACL repair?**

In the third part of this thesis, the safety and early outcomes of arthroscopic primary repair have been assessed in various studies.



First, a clinical evaluation of the postoperative course in the first six months was performed to assess if the procedure was indeed safe (complications) and what the recovery (ROM) was when compared to the gold-standard of ACL reconstruction (**chapter 8**). It was noted that the procedure of primary repair was safe with a low complication rate. This can be explained by the fact that the primary repair procedure is relatively quick, minimally invasive, no grafts need to be harvested and no tunnels need to be drilled. Likely because of the lower morbidity of the surgery, patients also regained ROM earlier during rehabilitation, and this might facilitate an easier recovery as milestones are reached earlier,<sup>48, 49</sup> but future prospective studies are needed to assess if this indeed influences other rehabilitation milestones or shortens time to return to sports.

In **chapter 9**, we assessed the outcomes of ACL repair of proximal tears in the literature to understand if similarly satisfying outcomes are experienced by other authors and if these results are not just the experience of a single surgeon. In this systematic review, three categories of surgical techniques were identified: primary repair without any augmentation, primary repair with static augmentation using a braided suture (InternalBrace) and primary repair with dynamic augmentation (dynamic intraligamentary stabilization (DIS; Ligamys)). It was noted that no large differences were noted in failure rate between the three groups with failures rates ranging between 6% and 14%. Similarly, patient-reported outcomes were generally good with these treatments and not different between the techniques. Interestingly, there were significant differences in reoperation rates between the techniques. Additional dynamic augmentation was noted to increase the reoperation rate for meniscus surgery and arthrofibrosis surgery when compared to primary repair with static augmentation and repair without augmentation, and it also required removal of hardware surgery in an additional 32% of operated patients. This can be explained by the large device that is used for dynamic augmentation and these findings question the use of this additional augmentation, especially given that the failure rates or patient-reported outcomes are not improved when compared to primary repair without any augmentation or with static augmentation.

Next, we assessed the outcomes of a larger group of 56 patients at short-term (two-year) follow-up (**chapter 10**), which comprises the outcomes of the first consecutive patients treated with modern-day primary repair. It was noted that 11% of patients suffered a re-injury of their repaired ACL and that 7% required a reoperation for either meniscus injury or hardware irritation. The strength of this study was that all patients were followed, and no patients were lost to follow-up. Furthermore, it was noted that the functional outcomes in these patients were good with most patient-reported outcome scores around 90% of the maximum score. When comparing the outcomes between primary repair alone and primary repair with additional suture augmentation in our cohort study (**chapter 10**) and the systematic review (**chapter 9**), a trend towards lower failure rates was noted with the use of static augmentation in our cohort study (7% vs. 14%) and in our systematic review (6% vs. 14%). Although these findings were not statistically significant, which could be explained by insufficiently powered sample sizes for this analysis, it is possible that static augmentation

indeed protects the repaired ligament in the early rehabilitation phases and therefore protects the ligament healing. Future studies with larger cohorts or systematic reviews are needed to assess this.

As discussed in the introduction section, the historical short-term outcomes of open primary repair were promising,<sup>50-52</sup> but deteriorated at mid-term follow-up.<sup>6,7,26,53</sup> In the first part of this thesis, we have reviewed the historical studies on open primary repair and have noted that tear location was a significant confounder in these studies as some studies reported encouraging outcomes of open primary repair when only treating proximal tears.<sup>15,54</sup> Moreover, even better outcomes can be expected with several modern developments, such as arthroscopy, suture anchors and non-absorbable sutures. Another goal of this thesis was therefore to assess if the outcomes of arthroscopic primary repair of proximal ACL tears with suture anchors remained good and did not deteriorate after the short-term follow-up. The results shown in **chapter 11** showed that the outcomes arthroscopic primary repair were maintained at six-year follow-up in our pilot study which can likely be explained by the careful patient selection of only treating patients with proximal tears and sufficient tissue quality and the use of arthroscopic surgery. Although the average age of patients at time of surgery was higher than most cohorts treating ACL injuries (37), good results were also achieved in the youngest three patients as well (17 to 21 years of age). Despite these promising outcomes, the failure rate needs to be assessed in a larger cohort of patients. This is especially of interest in the younger age group, as the failure rates in these patients with ACL reconstruction are very high (up to 25%).<sup>55,56</sup> The goal of the next years is therefore also to follow-up the patients of the larger cohort (from **chapter 10**) to mid-term follow-up and assess if deterioration in this larger group occurs.

Finally, in our systematic review (**chapter 9**) we have assessed the level of evidence of the available recent literature on primary repair and noted that this was mainly limited to level III and IV studies. In the literature, four designs of prospective randomized studies have been published of which two studies did not limit their inclusion criteria to proximal tears<sup>57,58</sup> and one study was on primary repair of midsubstance tears.<sup>59</sup> As a result, we have designed a multicenter randomized trial in the Netherlands for patients with proximal tears (**chapter 12**). In this study, arthroscopy will be performed first to assess the tear location and the quality of the ligament remnant, and then patients are randomized between primary ACL repair and ACL reconstruction. With this study, we aim to understand the outcomes of arthroscopic ACL repair and compare this prospectively with ACL reconstruction.

## Future directions

The work in this thesis has provided information on the modern role of arthroscopic primary repair in the treatment algorithm of ACL injuries. It is, however, far from complete as even more new research topics arise.

The most important topic for the next years will be the early identification of potential copers and non-copers with their ACL deficiency, and start ACL treatment early. As discussed previously, most patients in the Netherlands are treated conservatively and ACL reconstruction will be performed if persistent symptomatic instability is present or patients are not able to return to sports with their ACL deficient knee.<sup>35</sup> This has the benefit of not performing acute surgery on all patients including patients that might be potential copers and therefore reduce the number of surgeries, subsequent complications and surgical costs.<sup>37, 60</sup> There are, however, also some important disadvantages with delaying surgery in the non-copers. Delayed surgery is associated with increased risk of meniscus and chondral injury, a higher proportion of patients require meniscectomy rather than meniscus repair and this might be associated with higher risk of future osteoarthritis.<sup>41, 61-65</sup> Furthermore, delayed ACL reconstruction increases the time from injury to final return to sport, which can be important in these patients, is associated with higher sick-leave costs and results in inferior outcomes when compared to early ACL reconstruction in terms of quadriceps muscle atrophy, functional testing and pain with acute ACL reconstruction.<sup>43, 44</sup> Arthrofibrosis has been shown not to play a role with modern-day early ACL reconstruction.<sup>46, 47</sup> It would be important to early identify potential copers with ACL deficiency and treat these patients conservatively in order to avoid surgical overtreatment in these patients, and to identify non-copers early and perform surgery in these patients in an earlier phase given these disadvantages of delaying surgery. Performing early surgery in the patients that have a likelihood of failing conservative treatment (non-copers) also has the benefit of performing primary repair in those patients in which the ligament is proximally torn and has good tissue quality for primary repair, as these patients have earlier return of range of motion<sup>28</sup> and less joint awareness at follow-up<sup>66</sup>.

It is also important for future studies on primary ACL repair to expand the current cohorts to more carefully assess the failure rates, assess objective stability, and identify which types of patients are at risk for failure. With more patients performing at higher-activity levels, individual risk factors can be determined for which patients are at risk for re-injury, especially in younger patients as a recent study have suggested a high failure rates in adolescents undergoing primary repair.<sup>67</sup> Additionally, it can be assessed which patients have better functional outcomes and return to higher level of sports following primary repair. Furthermore, the outcomes need to be compared to ACL reconstruction in large prospective and preferable randomized studies. As shown in this thesis, there are differences in patient characteristics between both groups and prospective randomized studies are needed confirm the findings that are noted in cohort studies. Also, not much is currently known about the risk for osteoarthritis following both treatments, and this is important for patients with ACL

injuries. Long-term follow-up studies following open primary repair<sup>68</sup> and recent experimental studies<sup>69</sup> have suggested that the incidence of osteoarthritis might be good following primary repair but studies assessing this are necessary.

Furthermore, with the constant improvement of MRI quality,<sup>70</sup> more emphasis should be paid on the predictive role of MRI on the eligibility of primary repair. Better MRI quality enables us to not only determine the tear location but also tissue quality, and may provide the patient with more information preoperatively on the treatment and timing of surgery (e.g., if tear type seems eligible for repair, a patient could consider early surgery to benefit from arthroscopic primary repair). Also, objective MRI measurements should be performed to predict the preoperative possibility of primary repair.

Future research should also focus on the role of primary repair of other knee ligaments, such as the posterior cruciate ligament<sup>71</sup>, MCL<sup>72</sup> and posterolateral corner and combined injuries in the multiligamentous injured knee.<sup>73</sup> Reconstruction of multiple ligaments is invasive with harvesting multiple grafts, drilling of multiple tunnels with the risk of tunnel convergence, and postoperative stiffness often occurs as a result.<sup>74</sup> Primary repair of (some of) these ligaments<sup>75</sup>, possibly with augmentation, may potentially decrease the morbidity in the setting of multiligamentous injured knees and this should be assessed in future studies.

## **Conclusions**

This thesis has focused on the role of arthroscopic primary ACL repair in the modern treatment algorithm of ACL injuries. First, the historical literature on open primary repair was reviewed and a paradigm shift was noted: despite several studies reporting better outcomes following primary ACL repair of proximal tears, the outcomes of several prospective trials (without selection for tear location) led to an abandoning of repair for all ACL types of tears instead of abandoning primary repair only for midsubstance tears. This paradigm shift led to the current modern treatment algorithm for ACL injuries with an 'all or nothing' approach in which patients are either treated conservatively or treated with ACL reconstruction.

This thesis shows there is increasing evidence of reversing this paradigm shift and returning to a treatment algorithm based on tear location. The work in this thesis, but also other studies, shows there might be a role for arthroscopic primary repair in the modern treatment algorithm of ACL injuries. Appropriately selected patients – those with proximal tears and sufficient tissue quality, and preferably in the acute setting – can be treated with arthroscopic primary ACL repair. In order to accomplish this, surgeons should be aware to not harvest the graft first, as is often performed, but to first assess the ACL for tissue length and tissue quality and recognize those patients that are eligible for primary repair. Furthermore, patients should be informed about the different treatment options of ACL injuries: conservative treatment, arthroscopic ACL repair or ACL reconstruction with their corresponding advantages and disadvantages.

## References

1. Heim U, Bachmann B, Infanger K. Reinsertion of the anterior cruciate ligament or primary ligamentous plasty? *Helv Chir Acta*. 1982;48(5):703-708.
2. Strand T, Engesaeter LB, Molster AO, Raugstad TS, Stangeland L, Stray O, Alho A. Knee function following suture of fresh tear of the anterior cruciate ligament. *Acta Orthop Scand*. 1984;55(2):181-184.
3. Marcacci M, Spinelli M, Chiellini F, Buccolieri V. Notes on 53 cases of immediate suture of acute lesions of the anterior cruciate ligament. *Italian Journal of Sports Traumatology*. 1985;7(2):69-79.
4. Weaver JK, Derkash RS, Freeman JR, Kirk RE, Oden RR, Matyas J. Primary knee ligament repair--revisited. *Clin Orthop Relat Res*. 1985 (199):185-191.
5. Marshall JL, Warren RF, Wickiewicz TL. Primary surgical treatment of anterior cruciate ligament lesions. *Am J Sports Med*. 1982;10(2):103-107.
6. Sherman MF, Lieber L, Bonamo JR, Podesta L, Reiter I. The long-term followup of primary anterior cruciate ligament repair. Defining a rationale for augmentation. *Am J Sports Med*. 1991;19(3):243-255.
7. Kaplan N, Wickiewicz TL, Warren RF. Primary surgical treatment of anterior cruciate ligament ruptures. A long-term follow-up study. *Am J Sports Med*. 1990;18(4):354-358.
8. Andersson C, Odensten M, Gillquist J. Knee function after surgical or nonsurgical treatment of acute rupture of the anterior cruciate ligament: A randomized study with a long-term follow-up period. *Clin Orthop Relat Res*. 1991 (264):255-263.
9. Andersson C, Odensten M, Good L, Gillquist J. Surgical or non-surgical treatment of acute rupture of the anterior cruciate ligament. A randomized study with long-term follow-up. *J Bone Joint Surg Am*. 1989;71(7):965-974.
10. Engebretsen L, Benum P, Fasting O, Molster A, Strand T. A prospective, randomized study of three surgical techniques for treatment of acute ruptures of the anterior cruciate ligament. *Am J Sports Med*. 1990;18(6):585-590.
11. Grontvedt T, Engebretsen L, Benum P, Fasting O, Molster A, Strand T. A prospective, randomized study of three operations for acute rupture of the anterior cruciate ligament. Five-year follow-up of one hundred and thirty-one patients. *J Bone Joint Surg Am*. 1996;78(2):159-168.
12. Grontvedt T, Engebretsen L. Comparison between two techniques for surgical repair of the acutely torn anterior cruciate ligament. A prospective, randomized follow-up study of 48 patients. *Scand J Med Sci Sports*. 1995;5(6):358-363.
13. Odensten M, Hamberg P, Nordin M, Lysholm J, Gillquist J. Surgical or conservative treatment of the acutely torn anterior cruciate ligament. A randomized study with short-term follow-up observations. *Clin Orthop Relat Res*. 1985 (198):87-93.
14. Sandberg R, Balkfors B, Nilsson B, Westlin N. Operative versus non-operative treatment of recent injuries to the ligaments of the knee. A prospective randomized study. *J Bone Joint Surg Am*. 1987;69(8):1120-1126.
15. Genelin F, Trost A, Primavesi C, Knoll P. Late results following proximal reinsertion of isolated ruptured acl ligaments. *Knee Surg Sports Traumatol Arthrosc*. 1993;1(1):17-19.
16. Kuhne JH, Refior HJ. Die primäre naht des vorderen kreuzbands: Eine kritische analyse. *Unfallchirurg*. 1993;96(9):451-456.
17. McCarroll JR, Shelbourne KD, Porter DA, Rettig AC, Murray S. Patellar tendon graft reconstruction for midsubstance anterior cruciate ligament rupture in junior high school athletes. *Am J Sports Med*. 1994;22(4):478-484.
18. Sherman MF, Bonamo JR. Primary repair of the anterior cruciate ligament. *Clin Sports Med*. 1988;7(4):739-750.
19. Toy BJ, Yeasting RA, Morse DE, McCann P. Arterial supply to the human anterior cruciate ligament. *J Athl Train*. 1995;30(2):149-152.
20. Nguyen DT, Ramwadhoebe TH, van der Hart CP, Blankevoort L, Tak PP, van Dijk CN. Intrinsic healing response of the human anterior cruciate ligament: An histological study of reattached acl remnants. *J Orthop Res*. 2014 Feb;32(2):296-301.
21. Murray MM. Current status and potential of primary acl repair. *Clin Sports Med*. 2009;28(1):51-61.

22. Crain EH, Fithian DC, Paxton EW, Luetzow WF. Variation in anterior cruciate ligament scar pattern: Does the scar pattern affect anterior laxity in anterior cruciate ligament-deficient knees? *Arthroscopy*. 2005;21(1):19-24.
23. Murray MM, Fleming BC, Badger GJ, Team BT, Freiburger C, Henderson R, Barnett S, Kiapour A, Ecklund K, Proffen B, Sant N, Kramer DE, Micheli LJ, Yen YM. Bridge-enhanced anterior cruciate ligament repair is not inferior to autograft anterior cruciate ligament reconstruction at 2 years: Results of a prospective randomized clinical trial. *Am J Sports Med*. 2020 May;48(6):1305-1315.
24. Sgaglione NA, Warren RF, Wickiewicz TL, Gold DA, Panariello RA. Primary repair with semitendinosus tendon augmentation of acute anterior cruciate ligament injuries. *Am J Sports Med*. 1990;18(1):64-73.
25. Millett PJ, Wickiewicz TL, Warren RF. Motion loss after ligament injuries to the knee. Part i: Causes. *Am J Sports Med*. 2001;29(5):664-675.
26. Feagin JA, Jr., Curl WW. Isolated tear of the anterior cruciate ligament: 5-year follow-up study. *Am J Sports Med*. 1976;4(3):95-100.
27. Shelbourne KD, Nitz P. Accelerated rehabilitation after anterior cruciate ligament reconstruction. *J Orthop Sports Phys Ther*. 1992;15(6):256-264.
28. van der List JP, DiFelice GS. Range of motion and complications following primary repair versus reconstruction of the anterior cruciate ligament. *Knee*. 2017;24(4):798-807.
29. Jorjani J, Altmann D, Auen R, Koopmann C, Lyutenski B, Wirtz DC. Mittel- bis langfristige ergebnisse nach vorderer kreuzbandruptur und versorgung in healing-response-technik. *Z Orthop Unfall*. 2013 Dec;151(6):570-579.
30. Higgins RW, Steadman JR. Anterior cruciate ligament repairs in world class skiers. *Am J Sports Med*. 1987;15(5):439-447.
31. Vahey TN, Broome DR, Kayes KJ, Shelbourne KD. Acute and chronic tears of the anterior cruciate ligament: Differential features at mr imaging. *Radiology*. 1991;181(1):251-253.
32. Remer EM, Fitzgerald SW, Friedman H, Rogers LF, Hendrix RW, Schafer MF. Anterior cruciate ligament injury: Mr imaging diagnosis and patterns of injury. *Radiographics*. 1992;12(5):901-915.
33. van der List JP, DiFelice GS. Preservation of the anterior cruciate ligament: A treatment algorithm based on tear location and tissue quality. *Am J Orthop (Belle Mead NJ)*. 2016;45(7):E393-E405.
34. van der List JP, DiFelice GS. Preservation of the anterior cruciate ligament: Surgical techniques. *Am J Orthop (Belle Mead NJ)*. 2016;45(7):E406-414.
35. Meuffels DE, Poldervaart MT, Diercks RL, Fievez AW, Patt TW, Hart CP, Hammacher ER, Meer F, Goedhart EA, Lenssen AF, Muller-Ploeger SB, Pols MA, Saris DB. Guideline on anterior cruciate ligament injury. *Acta Orthop*. 2012 Aug;83(4):379-386.
36. van der List JP, Hagemans FJA, Hofstee DJ, Jonkers FJ. The role of patient characteristics on the success of nonoperative treatment of anterior cruciate ligament injuries. *Am J Sports Med*. 2020;48(7):1657-1664.
37. Frobell RB, Roos HP, Roos EM, Roemer FW, Ranstam J, Lohmander LS. Treatment for acute anterior cruciate ligament tear: Five year outcome of randomised trial. *BMJ*. 2013 Jan 24;346:f232.
38. Keays SL, Newcombe P, Keays AC. Nearly 90% participation in sports activity 12 years after non-surgical management for anterior cruciate ligament injury relates to physical outcome measures. *Knee Surg Sports Traumatol Arthrosc*. 2019 Aug;27(8):2511-2519.
39. Järvelä T, Nyssönen M, Kannus P, Paakkala T, Järvinen M. Bone-patellar tendon-bone reconstruction of the anterior cruciate ligament. A long-term comparison of early and late repair. *Int Orthop*. 1999;23(4):227-231.
40. Noyes FR, Barber-Westin SD. A comparison of results in acute and chronic anterior cruciate ligament ruptures of arthroscopically assisted autogenous patellar tendon reconstruction. *Am J Sports Med*. 1997;25(4):460-471.
41. Sommerfeldt M, Goodine T, Raheem A, Whittaker J, Otto D. Relationship between time to acl reconstruction and presence of adverse changes in the knee at the time of reconstruction. *Orthop J Sports Med*. 2018;6(12):232596711881391.
42. Herbst E, Hoser C, Gfoller P, Hepperger C, Abermann E, Neumayer K, Musahl V, Fink C. Impact of surgical timing on the outcome of anterior cruciate ligament reconstruction. *Knee Surg Sports Traumatol Arthrosc*. 2017;25(2):569-577.

43. Eriksson K, von Essen C, Jonhagen S, Barenius B. No risk of arthrofibrosis after acute anterior cruciate ligament reconstruction. *Knee Surg Sports Traumatol Arthrosc.* 2018;26(10):2875-2882.
44. von Essen C, Eriksson K, Barenius B. Acute acl reconstruction shows superior clinical results and can be performed safely without an increased risk of developing arthrofibrosis. *Knee Surg Sports Traumatol Arthrosc.* 2019;28(7):2036-2043.
45. von Essen C, McCallum S, Barenius B, Eriksson K. Acute reconstruction results in less sick-leave days and as such fewer indirect costs to the individual and society compared to delayed reconstruction for acl injuries. *Knee Surg Sports Traumatol Arthrosc.* 2019 02/14;28(7):2044-2052.
46. Deabate L, Previtali D, Grassi A, Filardo G, Candrian C, Delcogliano M. Anterior cruciate ligament reconstruction within 3 weeks does not increase stiffness and complications compared with delayed reconstruction: A meta-analysis of randomized controlled trials. *Am J Sports Med.* 2019;48(5):1263-1272.
47. Kwok CS, Harrison T, Servant C. The optimal timing for anterior cruciate ligament reconstruction with respect to the risk of postoperative stiffness. *Arthroscopy.* 2013 Mar;29(3):556-565.
48. Ekhtiari S, Horner NS, de Sa D, Simunovic N, Hirschmann MT, Ogilvie R, Berardelli RL, Whelan DB, Ayeni OR. Arthrofibrosis after acl reconstruction is best treated in a step-wise approach with early recognition and intervention: A systematic review. *Knee Surg Sports Traumatol Arthrosc.* 2017.
49. Nyland J, Mattocks A, Kibbe S, Kalloub A, Greene JW, Caborn DN. Anterior cruciate ligament reconstruction, rehabilitation, and return to play: 2015 update. *Open Access J Sports Med.* 2016;7:21-32.
50. Liljedahl SO, Lindvall N, Wetterfors J. Early diagnosis and treatment of acute ruptures of the anterior cruciate ligament; a clinical and arthrographic study of forty-eight cases. *J Bone Joint Surg Am.* 1965;47(8):1503-1513.
51. Feagin JA, Abbott HG, Rokous JR. The isolated tear of the anterior cruciate ligament. *J Bone Joint Surg Am.* 1972;54(6):1340-1341.
52. England RL. Repair of the ligaments about the knee. *Orthop Clin North Am.* 1976;7(1):195-204.
53. Straub T, Hunter RE. Acute anterior cruciate ligament repair. *Clin Orthop Relat Res.* 1988;227:238-250.
54. Bram J, Plaschy S, Lutolf M, Leutenegger A. [the primary cruciate ligament suture--is the method outdated? Results in follow-up of 58 patients]. *Z Unfallchir Versicherungsmed.* 1994;87(2):91-109.
55. Webster KE, Feller JA. Exploring the high reinjury rate in younger patients undergoing anterior cruciate ligament reconstruction. *Am J Sports Med.* 2016;44(11):2827-2832.
56. Wiggins AJ, Grandhi RK, Schneider DK, Stanfield D, Webster KE, Myer GD. Risk of secondary injury in younger athletes after anterior cruciate ligament reconstruction: A systematic review and meta-analysis. *Am J Sports Med.* 2016;44(7):1861-1876.
57. Evangelopoulos DS, Kohl S, Schwienbacher S, Gantenbein B, Exadaktylos A, Ahmad SS. Collagen application reduces complication rates of mid-substance acl tears treated with dynamic intraligamentary stabilization. *Knee Surg Sports Traumatol Arthrosc.* 2017 Aug;25(8):2414-2419.
58. Krismer AM, Gousopoulos L, Kohl S, Ateschrang A, Kohlhof H, Ahmad SS. Factors influencing the success of anterior cruciate ligament repair with dynamic intraligamentary stabilisation. *Knee Surg Sports Traumatol Arthrosc.* 2017;25(12):3923-3928.
59. Murray MM, Yeng YM. A prospective, randomized, controlled, clinical trial evaluating the non-inferiority of bridge-enhanced anterior cruciate ligament repair (bear) to anterior cruciate ligament reconstruction with an autologous tendon graft (aclr). <https://clinicaltrials.gov/show/nct02664545> [Internet]. 2016. Available from: <https://www.cochranelibrary.com/central/doi/10.1002/central/CN-01555321/full>.
60. Frobell RB, Roos EM, Roos HP, Ranstam J, Lohmander LS. A randomized trial of treatment for acute anterior cruciate ligament tears. *N Engl J Med.* 2010;363(4):331-342.
61. Fithian DC, Paxton EW, Stone ML, Luetzow WF, Csintalan RP, Phelan D, Daniel DM. Prospective trial of a treatment algorithm for the management of the anterior cruciate ligament-injured knee. *Am J Sports Med.* 2005;33(3):335-346.
62. Ajuied A, Wong F, Smith C, Norris M, Earnshaw P, Back D, Davies A. Anterior cruciate ligament injury and radiologic progression of knee osteoarthritis: A systematic review and meta-analysis. *Am J Sports Med.* 2014;42(9):2242-2252.

63. Karikis I, Ahlen M, Sernert N, Ejerhed L, Rostgard-Christensen L, Kartus J. The long-term outcome after early and late anterior cruciate ligament reconstruction. *Arthroscopy*. 2018 Jun;34(6):1907-1917.
64. Karlsson J, Kartus J, Magnusson L, Larsson J, Brandsson S, Eriksson BI. Subacute versus delayed reconstruction of the anterior cruciate ligament in the competitive athlete. *Knee Surg Sports Traumatol Arthrosc*. 1999;7(3):146-151.
65. Cinque ME, Dornan GJ, Chahla J, Moatshe G, LaPrade RF. High rates of osteoarthritis develop after anterior cruciate ligament surgery: An analysis of 4108 patients. *Am J Sports Med*. 2018 Jul;46(8):2011-2019.
66. Vermeijden HD, van der List JP, O'Brien R, DiFelice GS. Patients forget about their operated knee more following arthroscopic primary repair of the anterior cruciate ligament than following reconstruction. *Arthroscopy*. 2020 Mar;36(3):797-804.
67. Gagliardi AG, Carry PM, Parikh HB, Traver JL, Howell DR, Albright JC. Acl repair with suture ligament augmentation is associated with a high failure rate among adolescent patients. *Am J Sports Med*. 2019 Feb 7:363546518825255.
68. Strand T, Molster A, Hordvik M, Krukhaug Y. Long-term follow-up after primary repair of the anterior cruciate ligament: Clinical and radiological evaluation 15-23 years postoperatively. *Arch Orthop Trauma Surg*. 2005;125(4):217-221.
69. Murray MM, Fleming BC. Use of a bioactive scaffold to stimulate anterior cruciate ligament healing also minimizes posttraumatic osteoarthritis after surgery. *Am J Sports Med*. 2013;41(8):1762-1770.
70. Van Dyck P, Vanhoenacker FM, Lambrecht V, Wouters K, Gielen JL, Dossche L, Parizel PM. Prospective comparison of 1.5 and 3.0-t mri for evaluating the knee menisci and acl. *J Bone Joint Surg Am*. 2013;95(10):916-924.
71. DiFelice GS, van der List JP. Arthroscopic primary repair of posterior cruciate ligament injuries. *Op Tech Sports Med*. 2015;23(4):307-314.
72. van der List JP, DiFelice GS. Primary repair of the medial collateral ligament with internal bracing. *Arthrosc Tech*. 2017;6(4):e933-e937.
73. Jonkergouw A, van der List JP, DiFelice GS. Multiligament repair with suture augmentation in a knee dislocation with medial-sided injury. *Arthrosc Tech*. 2018;7(8):e839-e843.
74. Hanley J, Westermann R, Cook S, Glass N, Amendola N, Wolf BR, Bollier M. Factors associated with knee stiffness following surgical management of multiligament knee injuries. *J Knee Surg*. 2016;30(6):549-554.
75. Vermeijden HD, Jonkergouw A, van der List JP, DiFelice GS. The multiple ligament-injured knee: When is primary repair an option? *Knee*. 2020 Jan;27(1):173-182.



# Appendices

**Surgical technique:  
Arthroscopic primary anterior cruciate ligament  
repair with suture augmentation**

Jelle P. van der List

Gregory S. DiFelice

*Arthrosc Tech. 2017 Sep 11;6(5):e1529-e1534*

## **Abstract**

Historically, poor results of open primary repair of anterior cruciate ligament (ACL) injuries have been reported. In hindsight, however, appropriate patient selection (i.e., proximal tears and good tissue quality) was not performed, as it has recently been recognized that good outcomes of primary ACL repair are possible when selectively performed in patients with proximal tears and good tissue quality.

Moreover, with modern-day advances, arthroscopic primary repair can be an excellent treatment option for patients with proximal tears. Preserving the native ACL has several advantages, including maintaining native proprioceptive function and biology. The procedure is also minimally invasive and prevents the need for formal ACL reconstruction. Recently, it has been suggested that additional internal bracing of the primary repair technique may be beneficial for protecting ligament healing during early range of motion. In this article, we present the surgical technique of arthroscopic primary repair with internal bracing for patients with proximal ACL tears.

## Introduction

Primary repair of the anterior cruciate ligament (ACL) was a popular treatment in the 1970s and 1980s using an open procedure.<sup>1</sup> Although the short-term outcomes were initially good, they deteriorated at longer-term follow-up and were considered unpredictable. In the early 1990s, Sherman et al. suggested that tear location was a possible explanation for these unpredictable outcomes when noting a trend towards better results with open primary repair of proximal tears.<sup>2</sup> Although some surgeons indeed showed excellent results of open primary repair of proximal tears,<sup>3</sup> the concept of primary repair was abandoned, and ACL reconstruction became the gold standard for all tear types.<sup>1</sup>

Several disadvantages of ACL reconstruction, however, exist, including: not preserving proprioception, not restoring native kinematics, not preventing osteoarthritis, and potential problems with revision surgery. Therefore, a resurgence of interest has recently been noted in ACL preservation using arthroscopic primary repair.<sup>4,5</sup> In 2008, DiFelice et al. performed the first arthroscopic primary repair in patients with proximal tears, and recently reported excellent outcomes at an average of 3.5 years follow-up on his first eleven patients.<sup>4</sup> A few years later, Achtnich et al. performed arthroscopic primary repair and noted that the outcomes and stability examinations were equivalent when compared to ACL reconstruction.

In 2015, Mackay et al. presented the concept of internal bracing that could be added to arthroscopic primary repair, which is thought to protect ligament healing during early range of motion (ROM).<sup>6</sup> In this technical note, we describe the surgical technique of arthroscopic primary ACL repair with internal bracing using a suture anchor approach. This surgical technique can be used for all patients with proximal ACL tears that have sufficient length for reapproximation to the femoral wall and sufficient tissue quality to withhold sutures. The procedure can be performed in patients of all age groups and activity levels, and for both isolated ACL injuries as well as ACL injuries in the multiligamentous injured knee.

## Surgical Technique

### Patient selection

Learning from earlier experiences, appropriate patient selection is critical with this technique.<sup>2</sup> Arthroscopic primary repair is only performed in patients with proximal tears (type I tears<sup>2,7</sup>) and excellent tissue quality in order to have good re-approximation of the ligament towards the femoral wall. These conditions are usually seen in the acute phase (i.e., first 3 months<sup>4-6</sup>), but can be seen in the chronic setting if the ACL is reattached to the posterior cruciate ligament<sup>8</sup> (Table 1).

**Table 1.** Indications and contraindications of arthroscopic primary anterior cruciate ligament repair with internal bracing

Indications	Absolute Contraindications
Proximal avulsion tears	Midsubstance tears
Sufficient tissue quality	Poor tissue quality
Patient with chronic proximal avulsion tears in which ACL is reattached to PCL <sup>8</sup>	Re-rupture of a repaired ligament
Patients of all age groups	<b>Relative Contraindications</b>
Isolated ACL injuries and ACL injuries in multiligamentous injured knees	Fair tissue quality (depending on surgical experience)

### General preparation

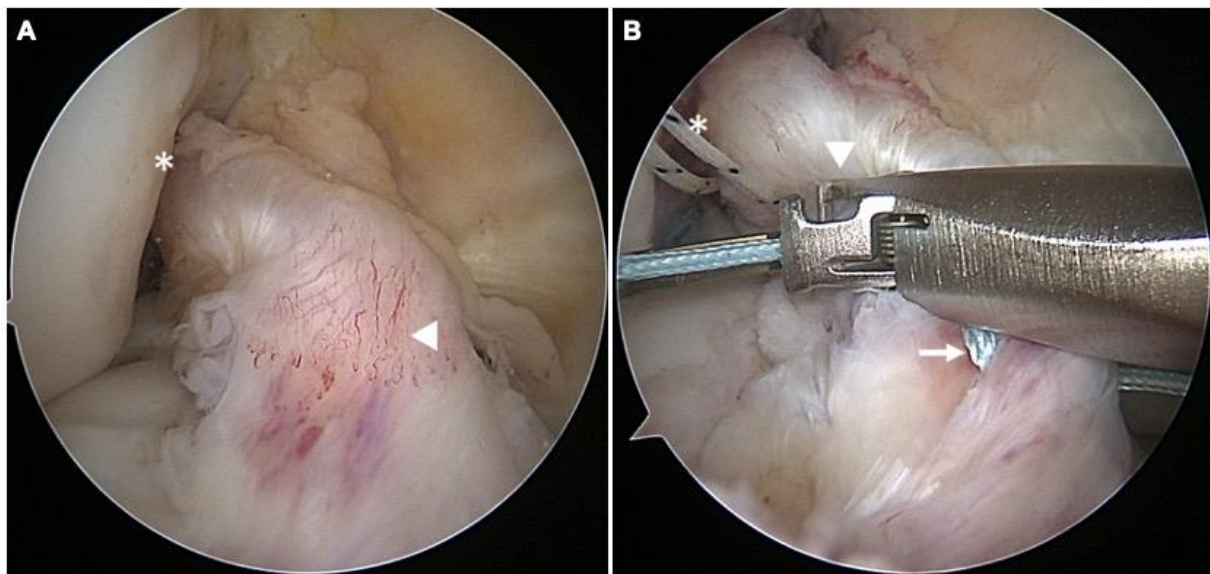
The patient is placed in the supine position, and the operative leg is prepped and draped as for standard knee arthroscopy. First, anteromedial and anterolateral portals are created, and a malleable Passport cannula (Arthrex, Naples, FL, USA) is placed in the anteromedial portal for suture passage and management. A general inspection of the knee is performed for tear type and tissue quality, assessing the possibility of primary repair surgery (Figure 1A).<sup>7</sup>

### Suturing of bundles

The first part of this surgical technique is similar to arthroscopic primary repair without internal bracing.<sup>9</sup> First, the anteromedial and posterolateral bundle of the ACL are identified, and the suturing is commenced. The sutures are passed through the anteromedial bundle using the Scorpion Suture Passer (Arthrex, Naples, FL, USA) with a #2 FiberWire suture (Arthrex, Naples, FL, USA) from the intact distal end in an alternating, interlocking Bunnell-type pattern towards the avulsed proximal end (Figure 1B). Three to four passes can usually be made before the final pass exits the proximal end towards the femur. Similarly, the suturing of the posterolateral bundle is performed using a #2 TigerWire suture (Arthrex, Naples, FL,

USA). It should be noted that the suture-passing device should be repositioned if great resistance is experienced, as this can lead to transection of the previously passed suture.

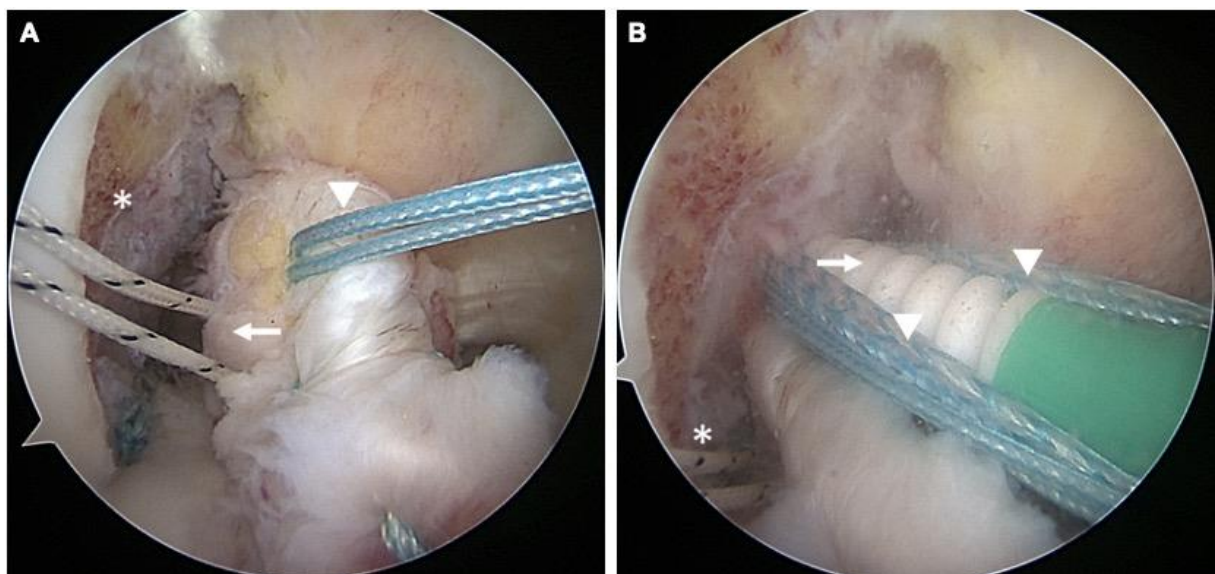
The sutures are then docked in an accessory portal just above the medial portal and the ligament can be retracted away for good visibility of the femoral footprint (Figure 2A). Bleeding of the notch wall is then induced using a shaver or burr by performing a small opening notchplasty to encourage healing, but the femoral footprint is left alone. With the knee in flexion and under direct visualization, an accessory inferomedial portal is then created for direct access to the femoral footprint.



**Figure 1. (A)** Arthroscopic view of a right knee, viewed from the anterolateral portal with the patient supine and the knee in 90° flexion. The anterior cruciate ligament is shown with a type I avulsion tear (asterix) and an intact distal and middle part of the ligament with excellent tissue quality and vascularity (arrowhead). **(B)** Arthroscopic view of a right knee, viewed from the anterolateral portal with the patient supine and the knee in 90° flexion. A suture passer (arrowhead) is used to pass a #2 FiberWire suture through the anteromedial bundle. The suture is passed in an alternating, interlocking Bunnell-type pattern and advancing proximally when compared to the previous stitches (arrow). In the left top corner of the image, the #2 TigerWire sutures of the posterolateral bundle are seen (asterix), as these were performed first in this patient.

## Suture anchor fixation

With the knee at 90° flexion, a 4.5 x 20mm hole is drilled, punched or tapped (depending on the bone density), into the origin of the anteromedial bundle within the femoral footprint. The FiberWire sutures are then retrieved through the accessory portal and passed through the eyelet of a 4.75mm Vented BioComposite SwiveLock suture anchor (Arthrex, Naples, FL, USA) that is preloaded with FiberTape (Arthrex, Naples, FL, USA) that will act as the internal brace. With the knee flexed at 90° for optimal visualization, the first suture anchor is deployed into the femur towards the anteromedial origin while tensioning the ACL remnant to the wall in order to prevent gap formation (Figure 2B). This procedure is then repeated for the posterolateral bundle with the FiberWire sutures and a non-preloaded suture anchor at 110 to 115° of flexion, which is necessary for optimal visualization and prevention of posterior condyle perforation. Once the anchors are deployed and flush with the femoral footprint, the handle is removed, the core stitches are unloaded and the free ends of the repair sutures are cut with an Open Ended Suture Cutter (Arthrex, Naples, FL, USA).

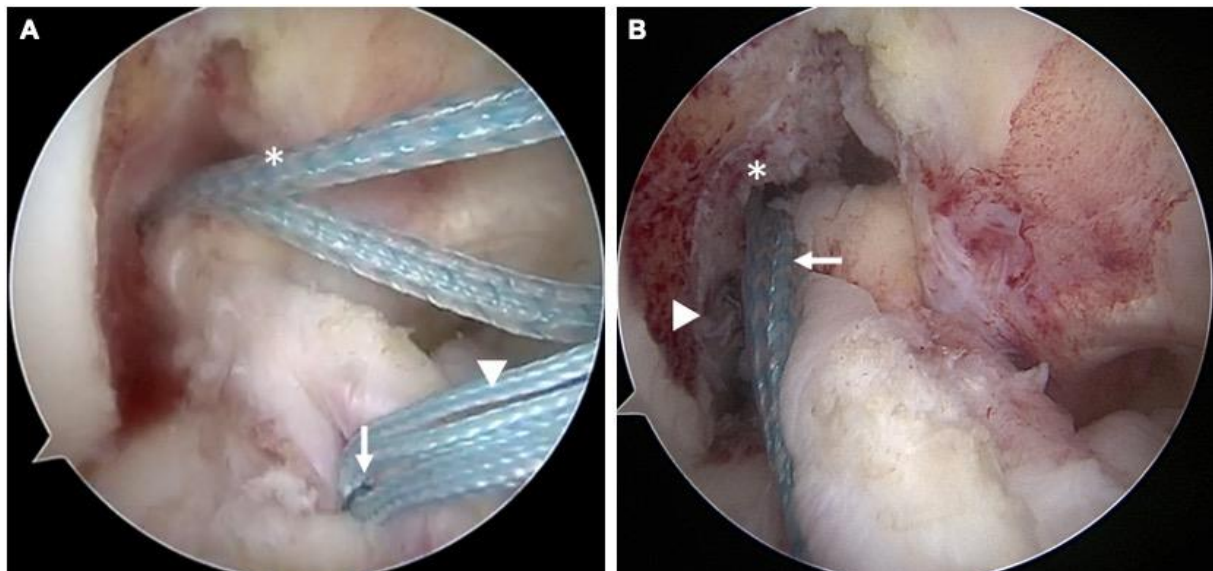


**Figure 2. (A)** Arthroscopic view of a right knee, viewed from the anterolateral portal with the patient supine and the knee in 90° flexion. Sutures are passed through both the anteromedial bundle (arrowhead) and posterolateral bundle (arrow). In the left top corner of the image, the femoral footprint can be seen, which has been roughened to induce a healing response (asterix). **(B)** Arthroscopic view of a right knee, viewed from the anterolateral portal with the patient supine and the knee in 90° flexion. The suture anchor of the anteromedial bundle is deployed in the anteromedial region within the femoral footprint (arrow). The arrowheads show the FiberTape internal brace. In the left bottom corner of the image, the sutures of the posterolateral bundle can be seen (asterix).

### Internal brace fixation distally

The FiberTape internal brace is now fixed through the anteromedial suture anchor proximally and needs to be fixed distally. First, an ACL guide is used to drill a 2.4mm drill pin up through the tibia from the anteromedial cortex and into the anterior half of the ACL tibial insertion. This is then switched for a Straight Microsuture Lasso (Arthrex, Naples, FL, USA), and the nitinol wire is retrieved out the anteromedial portal with the FiberTape. The FiberTape is then passed through the nitinol wire, and shuttled along the ACL substance (Figure 3A) and down through the tibia where it is fixed with a suture anchor perpendicular to the tibial cortex after cycling the knee and tensioning near full extension. It should be checked that the suture anchor is flush with the tibial cortex to avoid hardware irritation, and the FiberTape is then cut short.

The repair with internal bracing is now complete (Figure 3B), and the ACL remnant is tested for tension and stiffness with a probe. ROM and anatomic positioning should be visualized without graft impingement, and intraoperative Lachman testing should reveal minimal anteroposterior translation with a firm endpoint.



**Figure 3. (A)** Arthroscopic view of a right knee, viewed from the anterolateral portal with the patient supine and the knee in 90° flexion. The suture anchor of the anteromedial bundle with the internal brace (asterix) has been deployed in the femoral footprint. A micro suture lasso (arrow) with channel sutures (arrowhead) are used to channel the internal brace (asterix) through the drilled tibial tunnel. **(B)** Arthroscopic view of a right knee, viewed from the anterolateral portal with the patient supine and the knee in 90° flexion. A completed primary repair of the ACL reinserting both the anteromedial bundle (asterix) and the posterolateral bundle (arrowhead) into the anatomic femoral footprint can be seen. The internal brace (arrow) is channeled along the ligament and provides stability in the early phases of rehabilitation, and thus enables early range of motion and fast recovery.

## Rehabilitation

Postoperative management is similar as for arthroscopic primary repair without internal bracing.<sup>4,9</sup> Patients leave the operating room with a brace locked in extension. For the first 4 weeks, patients can weight bear with brace as tolerated, and perform ROM exercises without brace. After volitional quadriceps control has returned, the brace is unlocked for ambulation. After 4 weeks, formal physical therapy is started and a standard ACL rehabilitation program is followed. Early recovery tends to be significantly faster than ACL reconstruction, likely due to the minimal invasive procedure.

## Discussion

Recently, a resurgence of interest has been noted in ACL preservation using arthroscopic primary repair of proximal tears<sup>4,5</sup>. DiFelice reported excellent outcomes following this procedure without internal bracing with one failure (9%) at mean 3.5-year follow-up<sup>4</sup>. Moreover, Achtnich et al. compared primary repair with the gold standard of ACL reconstruction and noted equivalent functional outcomes following both procedures with a trend towards more revision following primary repair<sup>5</sup>.

The surgical procedure of arthroscopic primary repair with internal bracing can be performed in patients of all age groups (i.e. both pediatric and adult patients) and activity levels. Patients are indicated for this procedure when a type I tear is noted, which is a proximal soft tissue avulsion tear that occurs in approximately 16% of the adults according to a recent MRI study.<sup>10</sup> Absolute contra-indications for this technique are patients with tears that have a distal remnant that is too short for reinsertion, tissue quality that cannot withhold sutures (i.e. poor tissue quality) or rerupture of a repaired ACL. Relative contra-indications for this technique are surgical experience and surgical familiarity with the procedure: more familiarity and experience with the procedure can lead to the ability to also perform primary repair with internal bracing in patients with fair tissue quality (i.e. tissue can withhold sutures but is not a perfect tissue quality (Video 1)).

Very recently, Mackay et al. have described the internal brace technique with the rationale of protecting the ligament during early rehabilitation.<sup>6</sup> Experimental studies have assessed the role of augmenting the repair on biomechanical and histological outcomes during the first year<sup>11,12</sup>. Seitz et al. recreated proximal avulsion tears in sheep, and either performed primary repair, or primary repair with augmentation with a 3-mm polyethylene terephthalate (PET) band<sup>11</sup>. Histologically, they noted that ACL healing occurred in both groups, but that healing was achieved after 16 weeks for the augmented repair sheep, and after 26 weeks for the non-augmented repair sheep. They suggested that augmentation protected the ligament from necrosis and ligamentization, and therefore earlier healing was observed in the augmentation group. In another study, Seitz et al. assessed the biomechanical outcomes in both groups, and



noted that sheep with augmented repair had more anteroposterior stability in early postoperative phase (until 6 – 16 weeks) but that this difference was not evident at longer follow-up<sup>12</sup>. Furthermore, they noted that the augmented repair group at one-year had more ligament stiffness, and tensile strength when compared to the non-repair group. They concluded that augmented repair, especially in the early phases, had superior biomechanical results compared to non-augmented repair.

In the studies of DiFelice et al.<sup>4</sup> and Achtnich et al.<sup>5</sup>, some patients suffered ligament re-injury within three months after surgery following low-energy trauma. Bearing in mind the aforementioned findings by Seitz et al., it is possible that these injuries could have been prevented if the repair was internally braced. However, studies assessing reinjury rates following arthroscopic primary ACL repair with and without internal bracing are clearly needed. The senior author now prefers primary repair with internal bracing over primary repair without internal bracing or reconstructive surgery in patients with a repairable proximal type I tear<sup>7</sup>. Pearls and pitfalls, and the advantages and disadvantages of this procedure are noted in Table 2 and 3, respectively. The procedure is preferred over ACL reconstruction in all eligible patients (i.e. proximal tears and sufficient tissue quality) and this is not dependent on age, activity level or concomitant injuries. In patients with a failed primary ACL repair, however, ACL reconstruction is preferred over a second attempt to repair the ligament. Primary repair has the advantages of early return of ROM, low complications and not burning any bridges when compared to ACL reconstruction.<sup>13</sup>

**Table 2.** Surgical pearls and pitfalls of arthroscopic primary anterior cruciate ligament repair with internal bracing

Pearls	Pitfalls
<p>MRI can be used to identify proximal tears</p> <p>Use cannula in anteromedial portal for suture management</p> <p>Use self-retrieving suture passer to pass sutures</p> <p>Load anteromedial suture anchor with FiberTape as internal brace</p> <p>Utilize low accessory inferomedial portal to optimize angle for suture placement</p> <p>Flex knee at 90° for anteromedial bundle anchor placement and 110° for posterolateral bundle anchor placement to avoid posterior perforation</p> <p>Cycle the knee first and fix the FiberTape distally at near full extension for optimal function</p>	<p>Fixing FiberTape at flexion, which could cause overconstrain of the knee</p> <p>Not deploying suture anchor deep enough in tibial cortex (hardware irritation)</p>

**Table 3.** Advantages and disadvantages of arthroscopic primary anterior cruciate ligament repair with internal bracing

Advantages	Disadvantages
<p>Relatively short procedure (50 – 70 min)</p> <p>Minimally invasive (no tunnels)</p> <p>No graft harvesting complications</p> <p>Early range of motion with ligament protection</p> <p>Internal brace can be removed without damaging the repaired anterior cruciate ligament, if necessary</p> <p>No bridges burned for later ACL reconstruction</p> <p>Growth plate-sparing treatment for pediatric patients</p> <p>Faster recovery than ACL reconstruction</p> <p>Prevents osteoarthritis in experimental studies</p> <p>Preserves proprioception and native kinematics</p>	<p>Only in selective group of patients</p> <p>Long-term outcomes (<math>\geq 5</math> yrs.) unknown</p>

## Conclusion

A recent resurgence of interest in ACL preservation has been noted using arthroscopic primary repair in patients with proximal tears. In order to protect healing of the ligament and enable ROM during the early phases of rehabilitation, internal bracing can be added to the primary repair technique. In this article, we have described the surgical technique of arthroscopic primary suture anchor repair of proximal ACL tears with internal bracing.

## Acknowledgements

Author JPL has no conflict of interest. Author GSD is a paid consultant for and receives research funding from Arthrex (Naples, FL, USA).

## References

1. van der List JP, DiFelice GS. Primary repair of the anterior cruciate ligament: A paradigm shift. *Surgeon*. 2017;15(3):161-168.
2. Sherman MF, Lieber L, Bonamo JR, Podesta L, Reiter I. The long-term followup of primary anterior cruciate ligament repair. Defining a rationale for augmentation. *Am J Sports Med*. 1991;19(3):243-255.
3. Genelin F, Trost A, Primavesi C, Knoll P. Late results following proximal reinsertion of isolated ruptured ACL ligaments. *Knee Surg Sports Traumatol Arthrosc*. 1993;1(1):17-19.
4. DiFelice GS, Villegas C, Taylor SA. Anterior Cruciate Ligament Preservation: Early Results of a Novel Arthroscopic Technique for Suture Anchor Primary Anterior Cruciate Ligament Repair. *Arthroscopy*. 2015;31(11):2162-2171.
5. Achtnich A, Herbst E, Forkel P, Metzlauff S, Sprenker F, Imhoff AB, Petersen W. Acute Proximal Anterior Cruciate Ligament Tears: Outcomes After Arthroscopic Suture Anchor Repair Versus Anatomic Single-Bundle Reconstruction. *Arthroscopy*. 2016;32(12):2562-2569.
6. Mackay GM, Blyth MJ, Anthony I, Hopper GP, Ribbans WJ. A review of ligament augmentation with the InternalBrace: the surgical principle is described for the lateral ankle ligament and ACL repair in particular, and a comprehensive review of other surgical applications and techniques is presented. *Surg Technol Int*. 2015;26:239-255.
7. van der List JP, DiFelice GS. Preservation of the Anterior Cruciate Ligament: A Treatment Algorithm Based on Tear Location and Tissue Quality. *Am J Orthop (Belle Mead NJ)*. 2016;45(7):408-416;460.
8. van der List JP, DiFelice GS. Successful arthroscopic primary repair of a chronic anterior cruciate ligament tear 11 years following injury. *HSS J*. 2017;13(1):90-95.
9. DiFelice GS, van der List JP. Arthroscopic primary repair of proximal anterior cruciate ligament tears. *Arthrosc Tech*. 2016;5(5):E1057-E1061.
10. van der List JP, Mintz DN, DiFelice GS. The location of anterior cruciate ligament tears: a prevalence study using magnetic resonance imaging. *Orthop J Sports Med*. 2017;5(6):2325967117709966.
11. Seitz H, Menth-Chiari WA, Lang S, Nau T. Histological evaluation of the healing potential of the anterior cruciate ligament by means of augmented and non-augmented repair: an in vivo animal study. *Knee Surg Sports Traumatol Arthrosc*. 2008;16(12):1087-1093.
12. Seitz H, Pichl W, Matzi V, Nau T. Biomechanical evaluation of augmented and nonaugmented primary repair of the anterior cruciate ligament: an in vivo animal study. *Int Orthop*. 2013;37(11):2305-2311.
13. van der List JP, DiFelice GS. Range of motion and complications following primary repair versus reconstruction of the anterior cruciate ligament. *Knee*. 2017;24(4):798-807.



# Appendices

**Summary**

## Summary

This thesis was undertaken to examine the role of arthroscopic primary anterior cruciate ligament (ACL) repair in the modern treatment algorithm of ACL injuries. **Chapter 1** provides a general introduction of this thesis, in which the anatomy and function of the ligament, injury of the ACL, and the current treatment of the ACL are discussed. Finally, the research questions that led to the start of this thesis were presented.

In **chapter 2**, a careful review of the history of open primary repair was conducted. It was noted that a paradigm shift was present in the history of primary ACL repair: primary repair was abandoned for all tear types while, in hindsight, disappointing results of primary repair were predominantly reporting following repair of midsubstance tears. Several factors were identified that played a role in this paradigm shift. First, several studies showing excellent results of ACL repair of proximal tears were published in foreign languages or in small journals, and accessibility was limited without modern search engines such as PubMed. Furthermore, different nomenclature was present in the historical literature, and repair of proximal tears was often described as *reinsertion* rather than *repair*, leading to a potential bias when the literature was reviewed. Finally, the finding of the role of tear location on the outcomes of open primary repair was made relatively late in the era of primary repair, as several prospective studies finished the enrollment of patients before this finding, and the results were unfortunately generalized for all tear types.

In **chapter 3**, the outcomes of open primary repair in historical studies were systematically reviewed and stratified by tear location. It was noted that the outcomes were better in patients with proximal ACL tears and correlations were found between the percentage of patients with proximal tears in the studies and the percentage of satisfied patients. Furthermore, it was noted that the outcomes in the studies treating only proximal tears indeed did not deteriorate at mid-term follow-up, whereas the outcomes in the studies treating mostly midsubstance tears did deteriorate.

In **chapter 4**, the role of tear location on the success of conservative treatment of acute ACL injuries was assessed. In this retrospective study, all patients that underwent conservative treatment of acute ACL injury were assessed if they could cope with their ACL injury or that they required ACL reconstruction due to persistent instability. It was noted that tear location did not play a role on coping with ACL deficiency. This is important as primary repair is generally performed in the acute setting and these patients could therefore not undergo conservative treatment. This study showed that similar outcomes of conservative treatment can be expected for patients with proximal tears as for patients with midsubstance tears or distal tears. This study further showed that higher age, lower activity level and absence of meniscal injuries were predictive of coping with ACL injury, whereas there was no such predictive role for anterolateral ligament (ALL) injuries, tibial slope or bone marrow edema.

In **chapter 5**, an MRI classification system for tear locations of acute ACL injuries was proposed, and the intra- and interobserver reliability were assessed. This classification system, based on clinical relevance and feasibility, was then used to assess the prevalence of different tear types in adult patients with acute, complete, isolated ACL tears. It was noted that 16% had a tear in the most proximal 10% of the ligament and 27% had a tear in proximal 10 – 25% of the ligament.

In **chapter 6**, the role of preoperative MRI on the eligibility of primary repair was assessed. All patients that were treated with primary repair, if sufficient tissue length and quality were present intraoperatively, or primary reconstruction, if the ligament was not repairable, were reviewed. MRIs and arthroscopy videos were reviewed of 123 patients in blinded fashion. It was noted that 90% of the patients with a type I tear on MRI were repaired, whereas 46% of the type II tears and 14% of the type III tears were repaired. It was furthermore noted that tissue quality, graded on preoperative MRI, was also a predictor for eligibility of primary ACL repair.

In **chapter 7**, we assessed if patient characteristics or injury characteristics could predict the intraoperative possibility of arthroscopic ACL repair. It was noted that older age, lower BMI and the absence of lateral meniscus injury were associated with the eligibility for primary repair. Furthermore, a higher likelihood of repair (odds ratio 3.3) was noted when the surgery was performed within 4 weeks of injury. Finally, a significant learning curve was noted in this cohort indicating that more experience with the primary repair technique leads to a higher likelihood of being able to repair proximal ACL tears.

In **chapter 8**, the safety and postoperative course of arthroscopic primary ACL repair was assessed and compared with the gold standard of single-bundle ACL reconstruction. A total of 52 repair patients and 90 reconstruction patients could be included in this retrospective study. It was noted that patients in the repair group had more ROM after one week and one month when compared to reconstruction patients, and that repair patients also regained full ROM earlier than reconstruction patients. Furthermore, the arthroscopic primary repair procedure was considered safe as the complication rate was low (2%). The complication rate was lower than the reconstruction procedure, which could be explained by the shorter operation time and no necessity for graft tissue harvesting.

In **chapter 9**, we performed a systematic review with meta-analysis on the recent outcomes of ACL repair. Three main techniques were found to be used in the literature: primary repair without any augmentation, primary repair with static suture augmentation (internal bracing) and primary repair with dynamic augmentation (DIS). It was noted that good failure rates were reported following these treatments (14%, 6% and 11%, respectively). Furthermore, lower reoperation rates were reported following primary repair and repair with suture augmentation compared to DIS augmented repair. Moreover, significantly more additional reoperations were needed following DIS repair for hardware removal that was not

(frequently) seen following the other two treatments. In general, all three treatments reported excellent functional outcomes and high patient satisfaction rates.

In **chapter 10**, the short-term outcomes of arthroscopic ACL repair were assessed. The outcomes in the first 56 consecutive patients were assessed (100% follow-up) and it was noted that failure of the repair occurred in six patients (11%) and that an additional four patients (7%) required reoperation, two for meniscus pathology and two for hardware irritation of the tibial suture anchor. Furthermore, excellent functional outcome scores were noted with most scores in the 90s. No major complications were noted. Finally, no differences between primary repair and repair with suture augmentation were noted although there was a trend of lower failure rates following augmented ACL repair.

In **chapter 11**, the mid-term outcomes of the first 11 consecutive patients with proximal ACL tears that were treated with arthroscopic repair were reviewed. It was noted that, in contrast with historical studies that noted deterioration of outcomes at this follow-up, no worsening of outcomes was noted in this group. There was only one patient (9%) with an early failure, and one patient (9%) needing a reoperation for a medial meniscus tear. The functional outcomes were excellent in this group with a mean follow-up of 6 years (range 5 to 9 years). This cohort needs to be extended for better assessment of failure rate and to evaluate individual risk factor for failure or re-injury.

In **chapter 12**, the design for a randomized controlled trial on arthroscopic primary repair versus reconstruction of proximal ACL tears was presented. In this RCT, patients with proximal tears will be randomized between both treatments in various centers in the Netherlands and it was calculated that a total of 74 patients are needed for this study. The primary outcomes were functional outcome scores and the secondary outcomes were failure rates, return to sports and long-term osteoarthritis.

In **chapter 13**, the studies were reviewed and the place in the literature was discussed. Furthermore, the research questions were answered with the performed studies and the future directions for arthroscopic primary ACL repair research were discussed.



# Appendices

**Summary in Dutch (Samenvatting)**

## Samenvatting

Dit proefschrift werd opgezet om de rol van het primair hechten van de voorste kruisband (VKB) binnen het huidige scala aan behandelingen te bepalen. In **hoofdstuk 1** werd een algemene introductie van dit proefschrift gepresenteerd, waarin de anatomie en functie van de VKB, letsel van de VKB en de huidige behandelingsopties worden besproken. Ten slotte werden ook de onderzoeksvragen van dit proefschrift gepresenteerd.

**Hoofdstuk 2** werpt een kritische blik geworpen op de geschiedenis van het primair hechten van de VKB, wat toentertijd via een open procedure werd uitgevoerd. In de geschiedenis van VKB hechten heeft een duidelijke paradigmaverschuiving plaatsgevonden: het primair hechten werd voor alle type VKB-scheuren afgeschaft, terwijl de teleurstellende resultaten voornamelijk werden gevonden na het hechten van de scheuren in het midden van het ligament. Er zijn vele factoren geïdentificeerd die een bijdrage hebben geleverd aan deze paradigmaverschuiving. Ten eerste, de toegankelijkheid tot de studies die goede resultaten van het primair hechten van proximale VKB-scheuren lieten zien was gelimiteerd. Veel artikelen zijn in een andere taal dan het Engels geschreven of zijn gepubliceerd in kleinere tijdschriften en tevens was de toegankelijkheid minder door de afwezigheid van moderne zoekmachines zoals PubMed. Verder werd in het verleden vaak andere terminologie gebruikt voor het primair hechten van proximale scheuren (bv. 'reinsertie' in plaats van 'hechten'), waardoor bepaalde studies niet op waarde zijn geschat. Ten slotte, pas relatief laat werd bekend dat de uitkomsten beter waren bij het hechten van proximale VKB-scheuren ten opzichte van het hechten van VKB-scheuren in het midden. Doordat verscheidene prospectieve studies hun patiënten al hadden geïnccludeerd zonder naar de locatie van de scheur te kijken, werden de negatieve resultaten van deze studies gegeneraliseerd voor alle type scheuren.

In **hoofdstuk 3** zijn de uitkomsten van het primair hechten van de VKB middels een open procedure systematisch bekeken en tevens de uitkomsten bekeken per type VKB-scheur. De bevinding van deze studie was dat betere uitkomsten werden gevonden na het hechten van proximale scheuren en dat er een correlatie was tussen het aantal patiënten met proximale scheuren in de studies en het aantal tevreden patiënten. Bovendien werd er een verschil op de lange termijn gezien, namelijk dat de resultaten van primair hechten van proximale scheuren goed bleven op de lange termijn terwijl de resultaten van primair hechten van scheuren in het midden van de VKB minder werden.

In **hoofdstuk 4** werd de rol van de locatie van de scheur op het succes van conservatief beleid van VKB-scheuren onderzocht. In deze retrospectieve studie ondergingen alle patiënten een conservatief beleid van hun acute VKB-scheur en werd gekeken of ze konden omgaan met hun VKB-blessure of dat ze een VKB reconstructie nodig hadden voor hun niet-functionerende VKB. De studie liet zien dat de locatie van de VKB-scheur geen invloed had op het omgaan met de VBK-scheur. Dit is belangrijk omdat primair hechten meestal in de acute fase wordt gedaan en deze patiënten daardoor geen conservatief beleid kunnen ondergaan. Deze studie laat zien

dat vergelijkbare resultaten van conservatief beleid verwacht kan worden bij patiënten met proximale scheuren vergeleken met patiënten met scheuren in het midden van het ligament. De studie liet verder zien dat oudere leeftijd, lager activiteitsniveau en afwezigheid van meniscusscheuren voorspellend waren voor het kunnen omgaan met de VKB-blessure terwijl er niet zo'n voorspellende rol werd gezien voor blessure van het anterolaterale ligament of tibiale hellingshoek of de aanwezigheid botoedeem.

In **hoofdstuk 5** werd een MRI-classificatiesysteem voor locatie van VKB-scheuren voorgesteld en werd de intra- en interobserver betrouwbaarheid van dit systeem onderzocht. Het classificatiesysteem, dat gebaseerd is op klinische relevantie en haalbaarheid, werd gebruikt om de prevalentie van verschillende type scheuren te bepalen in volwassen patiënten met acute complete geïsoleerde VKB-scheuren. De prevalentie van een type I scheur (scheur in de meest proximale (bovenste) 10%) was 16%, terwijl 27% van de patiënten een type II scheur had (in de bovenste 10 tot 25% van de VKB).

In **hoofdstuk 6** werd de rol van preoperatieve MRI voor de indicatiestelling van primair VKB hechten onderzocht. In alle patiënten in dit studie cohort werd de VKB primair gehecht als voldoende lengte en kwaliteit van het ligament aanwezig is, anders werd een standaard VKB-reconstructie uitgevoerd. De MRI's en arthroscopische video's van 123 patiënten werden geblindeerd bekeken. De uitkomst was dat 90% van de scheuren die op MRI als type I scheuren werden gekarakteriseerd, ook daadwerkelijk gehecht werden, terwijl dit gold voor 46% van de type II scheuren en 14% van de type III scheuren. Bovendien bleek de weefselkwaliteit, naast de locatie van de scheur, op MRI een voorspellende factor van een hechtbare VKB-scheur.

In **hoofdstuk 7** bekeken we of patiënten karakteristieken of blessure karakteristieken de mogelijkheid van primair hechten van proximale VKB scheuren konden voorspellen. Oudere leeftijd, lager BMI en geen laterale meniscusscheur waren significante predictoren voor de mogelijkheid van primair VKB hechten. Ook was er een hogere kans op primair VKB hechten (odds ratio 3.3) als de operatie binnen 4 weken van de blessure werd uitgevoerd. Tenslotte werd er ook een leercurve voor deze operatie gevonden wat betekent dat de kans op primair VKB hechten groter is als de operateur meer ervaring met de techniek heeft.

In **hoofdstuk 8** werd de veiligheid en postoperatieve periode van arthroscopisch hechten van de VKB beoordeeld en vergeleken met de gouden standaard van VKB reconstructie. Voor deze retrospectieve studie werden 52 patiënten geïnccludeerd die waren behandeld met primair VKB hechten en 90 patiënten die waren behandeld met VKB reconstructie. De patiënten waarbij de VKB was gehecht, hadden meer knieflexie en -extensie na een week en na een maand en bereikten dit ook eerder dan reconstructie patiënten. Verder was de behandeling veilig door het lage aantal complicaties (2%), wat lager was dan bij de reconstructie procedure. Dit kan mogelijk verklaard worden door de kortere operatietijd en het niet hoeven oogsten van een reconstructie pees en het boren van tunnels in de botten.

In **hoofdstuk 9** werd een systematische review met meta-analyse verricht om de recente uitkomsten van verschillende primair hecht-technieken te onderzoeken. Drie belangrijke technieken werden herkend: primair hechten, primair hechten met augmentatie (intern verstevigen met sterke hechtdraad) en primair hechten met dynamisch intraligamentaire stabilisatie (DIS). Goede faalpercentages werden gezien bij alle drie de behandelingen (respectievelijk 14%, 6% en 11%). Verder werd er gevonden dat er minder her-operaties nodig waren bij primair hechten en primair hechten met augmentatie vergeleken met primair hechten met DIS augmentatie, en er werden ook veel heroperaties voor het verwijderen van materiaal nodig bij het primair hechten met DIS augmentatie dat (vrijwel) niet werd gezien bij primair hechten en hechten met augmentatie. In het algemeen werden bij alle behandelingen goede functionele uitkomsten gezien met een hoge mate van patiënt tevredenheid.

In **hoofdstuk 10** werden de korte-termijn uitkomsten van primair VKB hechten bekeken. De uitkomsten van de eerste 56 opeenvolgende patiënten werden bekeken (100% van patiënten gevolgd) en er bleek in 6 patiënten (11%) sprake van het falen van de scheur en in 4 patiënten (7%) een heroperatie nodig, twee vanwege meniscusproblemen en twee vanwege irritatie van het hechtanker in de tibia. Verder werden er uitstekende functionele uitkomsten gezien met de meeste scores in de 90. Ook werden er geen grote complicaties gezien. Tenslotte waren er geen verschillen tussen het primair hechten zonder augmentatie en het primair hechten met additionele augmentatie (intern verstevigen met een sterke hechtdraad), al werd er wel een trend naar minder falen te zijn bij primair hechten met augmentatie.

In **hoofdstuk 11** werden de uitkomsten van de eerst 11 patiënten waarbij de VKB prima is gehecht, verzameld na minimaal 5-jaar follow-up. Hoewel de historische literatuur mindere resultaten laat zien bij 5-jaar follow-up, werd in deze studies geen vermindering van de resultaten gezien in vergelijking met de 2-jaar resultaten. Er was één patiënt waarbij het primair hechten van de VKB gefaald is (9%) en één patiënt had een mediale meniscus scheur. De functionele uitkomsten waren uitstekend bij het laatste bezoek na gemiddeld 6 jaar. Het cohort zal echter moeten worden uitgebreid om een beter inzicht te verkrijgen in de precieze incidentie van falen en wat de risicofactoren zijn voor het falen van een primair gehechte VKB.

In **hoofdstuk 12** werd het ontwerp voor een gerandomiseerde studie gepresenteerd op het gebied van arthroscopisch primair hechten versus reconstructie van proximale VKB scheuren. In deze RCT zullen patiënten met proximale VKB scheuren worden gerandomiseerd tussen beide behandelingen in verschillende centra in Nederland en er wordt berekend dat 60 patiënten nodig zijn voor deze studie. De primaire uitkomsten zijn functionele uitkomsten en de secundaire uitkomsten zijn de mate van falen van de behandeling, terugkeer naar sport en de ontwikkeling van artrose op de langere termijn.

In **hoofdstuk 13** werd ten slotte teruggekeken op de studies die zijn uitgevoerd en werd de positie van primair VKB hechten in het huidige scala aan behandelingen besproken. Daarnaast werden de onderzoeksvragen van de introductie beantwoord en het toekomstige perspectief van onderzoek naar het arthroscopisch hechten van de VKB besproken.

# Appendices

PhD Portfolio

Name	Jelle Philip Jacob van der List
Research schools	Department of Orthopaedic Surgery Amsterdam University Medical Centers - Academic Medical Center University of Amsterdam, Amsterdam, the Netherlands
	Department of Orthopaedic Surgery Hospital for Special Surgery Weill Cornell Medicine, New York, USA
PhD period	2016 – 2021
Promotor	Prof. dr. G.M.M.J. Kerkhoffs
Copromotor	dr. A. van Noort

## 1. PhD Training

General courses	Year	Workload (ECTS)
BROK ('Basiscursus Regelgeving Klinisch Onderzoek')	2019	1.0
Specific courses		
NVA Arthroscopy Course 2: Knee Arthroscopy	2019	1.0
NVA Arthroscopy Course 1: Introduction	2019	1.0
AO Trauma Course: Basic Principles of Fracture Management	2018	1.0
Advanced Trauma Life Support	2017	1.0
Oral presentations and poster presentations	Year	Workload (ECTS)
<b>Van der List JP</b> , Vermeijden HD, DiFelice GS. The role of age on failure rates and outcomes following arthroscopic primary repair of proximal anterior cruciate ligament tears. Podium presentation at the Virtual Congress of the European Society for Sports Traumatology, Knee Surgery and Arthroscopy.	2021	0.5
<b>Van der List JP</b> , Hofstee DJ, Jonkers FJ. Success of conservative treatment of anterior cruciate ligament tears: the role of patient characteristics. ePoster presentation at the Virtual Congress of the European Society for Sports Traumatology, Knee Surgery and Arthroscopy.	2021	0.5

<b>Van der List JP</b> , Hofstee DJ, Jonkers FJ. Success of conservative treatment of anterior cruciate ligament tears: the role of patient characteristics. Podium presentation at the Annual Conference of the Dutch Orthopaedic Association.	2020	0.5
<b>Van der List JP</b> , Vermeijden HD, Sierevelt IN, DiFelice GS, Van Noort A, Kerkhoffs GMMJ. Systematic review with meta-analysis on recent outcomes of arthroscopic primary repair of proximal anterior cruciate ligament tears: studies with higher level of evidence are needed. Poster presentation at the Autumn Conference of the Dutch Orthopaedic Association.	2019	0.5
<b>Van der List JP</b> , Vermeijden HD, DiFelice GS. Outcomes in failure and reoperation rates, PROMs and return to sports following primary repair versus reconstruction of the anterior cruciate ligament. Podium presentation at the NVA Annual Meeting.	2019	0.5
<b>Van der List JP</b> , Jonkergouw A, van Noort A, Kerkhoffs GMMJ, DiFelice GS. Identifying candidates for arthroscopic primary repair of the anterior cruciate ligament: a case-control study [Dutch]. Podium presentation at the Annual Scientific Meeting of the Spaarne Gasthuis.	2019	0.5
<b>Van der List JP</b> , Vermeijden HD, Jonkergouw A, DiFelice GS. Less awareness of the knee following arthroscopic primary repair versus reconstruction of the anterior cruciate ligament. E-poster presentation at 12 <sup>th</sup> Biennial Congress of the International Society of Arthroscopy, Knee Surgery, and Orthopaedic Sports Medicine.	2019	0.5
<b>Van der List JP</b> , Jonkergouw A, DiFelice GS. Failure and reoperation rates following arthroscopic repair versus reconstruction of the anterior cruciate ligament. Podium presentation at the 86 <sup>th</sup> Annual Meeting of American Academy of Orthopaedic Surgeons.	2019	0.5
<b>Van der List JP</b> . Arthroscopic primary ACL repair: history, indications and outcomes. Podium presentation at the NVA Annual Meeting.	2018	0.5
<b>Van der List JP</b> , Jonkergouw A, DiFelice GS. Historical overview, patient selection, surgical technique and outcomes of primary repair of the anterior cruciate ligament. Poster presentation at the NVA Annual Meeting.	2018	0.5
<b>Van der List JP</b> , Jonkergouw A, DiFelice GS. Which patient is a candidate for primary repair of the anterior cruciate ligament? A cohort study. Poster presentation at the NVA Annual Meeting.	2018	0.5
<b>Van der List JP</b> , DiFelice GS. Good outcomes of arthroscopic primary repair of proximal anterior cruciate ligament tears are maintained at mid-term follow-up. Poster presentation at the 18 <sup>th</sup> Biannual Meeting of the European Society for Sports Traumatology, Knee Surgery and Arthroscopy.	2018	0.5

<b>Van der List JP</b> , DiFelice GS. Arthroscopic primary repair of proximal anterior cruciate ligament tears: with or without internal brace? Poster presentation at the 18 <sup>th</sup> Biannual Meeting of the European Society for Sports Traumatology, Knee Surgery and Arthroscopy.	2018	0.5
<b>Van der List JP</b> . Arthroscopic primary ACL repair: history, indications and outcomes. Podium presentation at the Inside the Knee and Shoulder Baltic Event.	2018	0.5
<b>Van der List JP</b> . Arthroscopic primary ACL repair: history, indications and outcomes. Podium presentation at the French Surgeon Specialist Meeting.	2018	0.5
<b>Van der List JP</b> , DiFelice GS. Arthroscopic primary repair of proximal anterior cruciate ligament tears: no deterioration at mid-term follow-up. Podium presentation at the 85 <sup>th</sup> Annual Meeting of American Academy of Orthopaedic Surgeons.	2018	0.5
<b>Van der List JP</b> , Mintz DN, DiFelice GS. The location of anterior cruciate ligament tears: a prevalence study using magnetic resonance imaging. Podium presentation at the 85 <sup>th</sup> Annual Meeting of American Academy of Orthopaedic Surgeons.	2018	0.5
<b>Van der List JP</b> , Mintz DN, DiFelice GS. The role of preoperative magnetic resonance imaging on eligibility for arthroscopic primary anterior cruciate ligament repair. Poster presentation at the 85 <sup>th</sup> Annual Meeting of American Academy of Orthopaedic Surgeons.	2018	0.5
<b>Van der List JP</b> , Mintz DN, DiFelice GS. Postoperative magnetic resonance imaging evaluation following arthroscopic primary anterior cruciate ligament repair. Poster presentation at the 85 <sup>th</sup> Annual Meeting of American Academy of Orthopaedic Surgeons.	2018	0.5
<b>Van der List JP</b> , DiFelice GS. Short-term rehabilitation and complications following primary repair versus reconstruction of the anterior cruciate ligament [Dutch]. Podium presentation at the Nederlands Orthopaedische Vereniging Najaarscongres.	2017	0.5
<b>Van der List JP</b> , DiFelice GS. Arthroscopic primary repair of proximal anterior cruciate ligament tears: no deterioration at mid-term follow-up. E-poster presentation at the 11 <sup>th</sup> Biennial Congress of the International Society of Arthroscopy, Knee Surgery, and Orthopaedic Sports Medicine.	2017	0.5
<b>Van der List JP</b> , DiFelice GS. The incidence of proximal avulsion anterior cruciate ligament tears: a magnetic resonance imaging evaluation. E-poster presentation at the 11 <sup>th</sup> Biennial Congress of the International Society of Arthroscopy, Knee Surgery, and Orthopaedic Sports Medicine.	2017	0.5



<b>Van der List JP</b> , DiFelice GS. Arthroscopic primary repair of proximal anterior cruciate ligament tears: no deterioration at mid-term follow-up. Podium presentation at the 36 <sup>th</sup> Annual Meeting of the Arthroscopy Association of North America.	2017	0.5
<b>Van der List JP</b> , DiFelice GS. The incidence of proximal avulsion anterior cruciate ligament tears: a magnetic resonance imaging evaluation. E-poster presentation at the 36 <sup>th</sup> Annual Meeting of the Arthroscopy Association of North America.	2017	0.5
DiFelice GS, <b>Van der List JP</b> . Arthroscopic primary repair of the anterior cruciate ligament: why we don't, why we should, and how to do it. Scientific Exhibit at the 84 <sup>th</sup> Annual Meeting of the American Academy of Orthopaedic Surgeons.	2017	0.5
<b>Van der List JP</b> , Chawla H, Villa JC, Pearle AD. Different optimal alignment but equivalent functional outcomes in medial and lateral unicompartmental knee arthroplasty. Poster presentation at the 26 <sup>th</sup> Annual Meeting of the American Association of Hip and Knee Surgeons.	2016	0.5
<b>Van der List JP</b> , Chawla H, Villa JC, Pearle AD. Different optimal alignment in medial and lateral unicompartmental knee arthroplasty. Podium presentation at the 47 <sup>th</sup> Annual Meeting of the Eastern Orthopaedic Association.	2016	0.5
<b>Van der List JP</b> , Chawla H, Zuiderbaan HA, Pearle AD. In which patient perform lateral unicompartmental or total knee arthroplasty? Podium presentation at the 47 <sup>th</sup> Annual Meeting of the Eastern Orthopaedic Association.	2016	0.5
<b>Van der List JP</b> , Chawla H, Joskowicz J, Pearle AD. Role of soft tissue balancing in computer-navigated total knee arthroplasty: a systematic review with meta-analysis. Podium presentation at the 29 <sup>th</sup> Annual Congress of the International Society for Technology in Arthroplasty.	2016	0.5
<b>Van der List JP</b> , Pearle AD, Carroll KM, Coon TM, Borus TA, Roche MW. Survivorship and patient satisfaction of robotic-assisted medial unicompartmental knee arthroplasty at a minimum two-year follow-up. Podium presentation at the 29 <sup>th</sup> Annual Congress of the International Society for Technology in Arthroplasty.	2016	0.5
<b>Van der List JP</b> , Chawla H, Pearle AD. Different optimal alignment but equivalent functional outcomes in medial and lateral robotic-assisted unicompartmental knee arthroplasty. E-poster with oral presentation at the 29 <sup>th</sup> Annual Congress of the International Society for Technology in Arthroplasty.	2016	0.5
<b>Van der List JP</b> , Zuiderbaan HA, Pearle AD. Unicompartmental knee arthroplasty versus total knee arthroplasty. Which type of artificial	2015	0.5

joint do patients forget? Poster presentation at the 27<sup>th</sup> Annual Holiday Knee and Hip Course.

**Van der List JP**, Thein R, Stone K, Boorman-Padgett J, Kia M, Nawabi DH, Wickiewicz TL, Imhauser CW, Pearle AD. The anterolateral ligament carries load and provides stability in the ACL deficient knee but bears minimal load when the ACL is intact. Podium presentation at the 10<sup>th</sup> Biennial Congress of the International Society of Arthroscopy, Knee Surgery, and Orthopaedic Sports Medicine. 2015 0.5

<b>(Inter)national conference visitor</b>	<b>Year</b>	<b>Workload (ECTS)</b>
Virtual Congress of the European Society for Sports Traumatology, Knee Surgery and Arthroscopy.	2021	0.5
Nederlandse Orthopaedische Vereniging Jaarcongres, 's Hertogenbosch, Netherlands.	2020	0.5
Nederlandse Orthopaedische Vereniging Najaarscongres, Arnhem, Netherlands.	2019	0.5
VOCA Congres, Amsterdam, Netherlands.	2019	0.25
86 <sup>th</sup> Annual Meeting of American Academy of Orthopaedic Surgeons, Las Vegas, NV, USA.	2019	1.25
Annual Meeting of the Nederlandse Vereniging voor Arthroscopie.	2018	0.25
18 <sup>th</sup> Biennial Meeting of the European Society for Sports Traumatology, Knee Surgery and Arthroscopy, Glasgow, Scotland.	2018	1.0
85 <sup>th</sup> Annual Meeting of American Academy of Orthopaedic Surgeons, New Orleans, LA, USA.	2018	1.25
Nederlandse Orthopaedische Vereniging Najaarscongres, Veldhoven, Netherlands.	2017	0.5
36 <sup>th</sup> Annual Meeting of the Arthroscopy Association of North America, Denver, CO, USA.	2017	0.75
84 <sup>th</sup> Annual Meeting of the American Academy of Orthopaedic Surgeons, San Diego, CA, USA.	2017	1.25
47 <sup>th</sup> Annual Meeting of the Eastern Orthopaedic Association, New Orleans, LA, USA.	2016	1.25
29 <sup>th</sup> Annual Congress of the International Society for Technology in Arthroplasty, Boston, MA, USA.	2016	1.0
27 <sup>th</sup> Annual Holiday Knee and Hip Course, New York, NY, USA.	2015	0.75
10 <sup>th</sup> Biennial Congress of the International Society of Arthroscopy, Knee Surgery, and Orthopaedic Sports Medicine, Lyon, France.	2015	1.25

<b>Other</b>	<b>Year</b>	<b>Workload (ECTS)</b>
Editorial Board for Arthroscopy Journal	2017 - present	5
Peer-reviewer for Knee Surgery, Sports Traumatology, Arthroscopy	2020 - present	2
Peer-reviewer for The Surgeon	2020 - present	2
Peer-reviewer for Bone and Joint Journal	2019 - present	3
Peer-reviewer for American Journal of Sports Medicine	2017 - present	5
Peer-reviewer for The Knee	2016 - present	6
Peer-reviewer for Arthroscopy Journal	2015 - 2016	2

## Teaching

<b>Supervising</b>	<b>Year</b>	<b>Workload (ECTS)</b>
Tarik Bayoumi, Robotic UKA, Orthopaedic Surgery, HSS	2021 - present	1
Daan Vermeijden, Primary ACL repair, Orthopaedic Surgery, HSS	2018 - 2019	1
Anne Jonkergouw, Primary ACL repair, Orthopaedic Surgery, HSS	2017 - 2018	1

<b>Other</b>	<b>Year</b>	<b>Workload (ECTS)</b>
Guest lecture at Boston Children's Hospital/Harvard Medical School	2017	0.5

## Parameters of Esteem

<b>Grants</b>	<b>Year</b>
Arthrex research grand	2018
Arthrex research grand	2017
Anna Fonds travel grand	2017
Marti-Keuning Eckhardt grand	2016
Arthrex research grand	2016
Anna Fonds travel grand	2015



# Appendices

**Reference list with  
contributions of the authors**

**Chapter 2.** Van der List JP, DiFelice GS. Primary repair of the anterior cruciate ligament: A paradigm shift. *Surgeon*. 2017;15(3):161-168.

Van der List: study design, data acquisition, data analysis, data interpretation, writing manuscript, revising manuscript, approval final version

DiFelice: study design, data interpretation, writing manuscript, revising manuscript, approval final version

**Chapter 3.** Van der List JP, DiFelice GS. Role of tear location on outcomes of open primary repair of the anterior cruciate ligament: A systematic review of historical studies. *Knee*. 2017;24(5):898-908.

Van der List: study design, data acquisition, data analysis, data interpretation, writing manuscript, revising manuscript, approval final version

DiFelice: study design, data interpretation, writing manuscript, revising manuscript, approval final version

**Chapter 4.** Van der List JP, Hagemans FJA, Zuiderbaan HA, Van Dijke C, Van Noort A, Kerkhoffs GMMJ. Age, activity level and meniscus injury, but not tear location, tibial slope or anterolateral ligament injury predict coping with anterior cruciate ligament injury. *Knee*. 2021;30(2):222-232.

Van der List: study design, data acquisition, data analysis, data interpretation, writing manuscript, revising manuscript, approval final version

Hagemans: study design, data acquisition, data interpretation, writing manuscript, revising manuscript, approval final version

Zuiderbaan: study design, data acquisition, data interpretation, writing manuscript, revising manuscript, approval final version

Van Dijke: data acquisition, data analysis, data interpretation, revising manuscript, approval final version

Van Noort: study design, data acquisition, data interpretation, writing manuscript, revising manuscript, approval final version

Kerkhoffs: study design, data acquisition, data interpretation, writing manuscript, revising manuscript, approval final version

**Chapter 5.** Van der List JP, Mintz DN, DiFelice GS. The location of anterior cruciate ligament tears: A prevalence study using magnetic resonance imaging. *Orthop J Sports Med.* 2017;5(6):2325967117709966.

Van der List: study design, data acquisition, data interpretation, writing manuscript, revising manuscript, approval final version

Mintz: study design, data acquisition, data interpretation, writing manuscript, revising manuscript, approval final version

DiFelice: study design, data acquisition, data interpretation, writing manuscript, revising manuscript, approval final version

**Chapter 6.** Van der List JP, DiFelice GS. Preoperative magnetic resonance imaging predicts eligibility for arthroscopic primary anterior cruciate ligament repair. *Knee Surg Sports Traumatol Arthrosc.* 2017;13;26(2):660-671.

Van der List: study design, data acquisition, data analysis, data interpretation, writing manuscript, revising manuscript, approval final version

DiFelice: study design, data interpretation, writing manuscript, revising manuscript, approval final version

**Chapter 7.** Van der List JP, Jonkergouw A, Van Noort A, Kerkhoffs GMMJ, DiFelice GS. Identifying candidates for arthroscopic primary repair of the anterior cruciate ligament: a case-control study. *Knee.* 2019;26(3):619-627.

Van der List: study design, data acquisition, data analysis, data interpretation, writing manuscript, revising manuscript, approval final version

Jonkergouw: data acquisition, data acquisition, data analysis, writing manuscript, revising manuscript, approval final version

Van Noort: study design, data interpretation, writing manuscript, revising manuscript, approval final version

Kerkhoffs: study design, data interpretation, writing manuscript, revising manuscript, approval final version

DiFelice: study design, data interpretation, writing manuscript, revising manuscript, approval final version

**Chapter 8.** Van der List JP, DiFelice GS. Range of motion and complications following primary repair versus reconstruction of the anterior cruciate ligament. *Knee*. 2017;24(4):798-807

Van der List: study design, data acquisition, data analysis, data interpretation, writing manuscript, revising manuscript, approval final version

DiFelice: study design, data interpretation, writing manuscript, revising manuscript, approval final version

**Chapter 9.** Van der List JP, Vermeijden HD, Sierevelt IN, DiFelice GS, van Noort A, Kerkhoffs GMMJ. Arthroscopic primary repair of proximal anterior cruciate ligament tears seems safe but higher level of evidence is needed: a systematic review and meta-analysis of recent literature. *Knee Surg Sports Traumatol Arthrosc*. 2020;28(6):1946-1957.

Van der List: study design, data acquisition, data analysis, data interpretation, writing manuscript, revising manuscript, approval final version

Vermeijden: study design, data acquisition, data analysis, data interpretation, writing manuscript, revising manuscript, approval final version

Sierevelt: data analysis, data interpretation, writing manuscript, approval final version

DiFelice: study design, data interpretation, writing manuscript, revising manuscript, approval final version

Van Noort: study design, data interpretation, writing manuscript, revising manuscript, approval final version

Kerkhoffs: study design, data interpretation, writing manuscript, revising manuscript, approval final version

**Chapter 10.** Jonkergouw A, Van der List JP, DiFelice GS. Arthroscopic primary repair of proximal anterior cruciate ligament tears: outcomes of first 56 consecutive patients and the role of additional internal bracing. *Knee Surg Sports Traumatol Arthrosc*. 2019;27(1):21-28.

Jonkergouw: study design, data acquisition, data analysis, data interpretation, writing manuscript, approval final version

Van der List: study design, data acquisition, data analysis, data interpretation, writing manuscript, revising manuscript, approval final version

DiFelice: study design, data interpretation, writing manuscript, revising manuscript, approval final version



**Chapter 11.** DiFelice GS, Van der List JP. Clinical outcomes of arthroscopic primary repair of proximal anterior cruciate ligament tears are maintained at mid-term follow-up. *Arthroscopy*. 2018 Apr;34(4):1085-1093.

DiFelice: study design, data interpretation, writing manuscript, revising manuscript, approval final version

Van der List: study design, data acquisition, data analysis, data interpretation, writing manuscript, revising manuscript, approval final version

**Chapter 12.** Van der List JP, Vermeijden HD, Sierevelt IN, Rademakers MV, Falke MLM, Helmerhorst GTT, Hoogeslag RAG, Van der Wal WA, Van Noort A, Kerkhoffs GMMJ. Repair versus reconstruction for proximal anterior cruciate ligament tears: a study protocol for a prospective multicenter randomized controlled trial. *BMC Musculoskelet Disord*. 2021;22(1):399.

Van der List: study design, writing manuscript, approval final version

Vermeijden: study design, writing manuscript, approval final version

Sierevelt: study design, writing manuscript, approval final version

Rademakers: study design, writing manuscript, approval final version

Falke: study design, writing manuscript, approval final version

Helmerhorst: study design, writing manuscript, approval final version

Hoogeslag: study design, writing manuscript, approval final version

Van der Wal: study design, writing manuscript, approval final version

Van Noort: study design, writing manuscript, approval final version

Kerkhoffs: study design, writing manuscript, approval final version



# Appendices

## List of publications

## Peer reviewed articles

### Published/accepted

1. Vermeijden HD, Yang XA, Rademakers MV, Kerkhoffs GMMJ, **Van der List JP**, DiFelice GS. *Early and delayed surgery for isolated ACL and multiligamentous knee injuries show equal results in this systematic review with meta-analysis*. Am J Sports Med. 2021, in press.
2. Yang XA, Vermeijden HD, O'Brien R, **Van der List JP**, DiFelice GS. *Percutaneous Coracoclavicular Tightrope Reduction of a Displaced Distal Clavicular Fracture: A Case Report*. Journal of Orthopaedic Experience & Innovation. 2021, in press.
3. Kolk RHE, Loggers SAI, **Van der List JP**, Schakenraad D, De Nooij L, Bijlsma TS. *Fracture progression in fragility fractures of the pelvis: a case report*. Trauma. 2021, in press. DOI: 10.1177/14604086211015065.
4. Vermeijden HD, Cerniglia B, Mintz DN, Rademakers MN, Kerkhoffs GMMJ, **Van der List JP**, DiFelice GS. *Distal remnant length can be measured reliably and predicts primary repair of proximal anterior cruciate ligament tears*. Knee Surg Sports Traumatol Arthrosc. 2021 Sep;29(9):2967-2975.
5. Vermeijden HD, Yang XA, **Van der List JP**, DiFelice GS. *Reliable internal consistency and adequate validity of the Forgotten Joint Score-12 after primary anterior cruciate ligament repair*. Arthrosc Sports Med Rehabil. 2021 May;3(3):e893-e900.
6. Bayoumi T, Van Duijvenbode DC, Benner JL, Stavenuiter MHJ, **Van der List JP**. *Clinical improvement is achieved following tibial tubercle distomedialization for patellar maltracking and patella alta without instability*. Arthrosc Sports Med Rehabil. 2021 Jun;3(3):e845-e853.
7. Vermeijden HD, **Van der List JP**, DiFelice GS. *Arthroscopic primary repair of proximal anterior cruciate ligament tears with suture augmentation*. Video J Sports Med. 2021 May/Jun;1(3):26350254211005461.
8. Vermeijden HD, O'Brien R, **Van der List JP**, DiFelice GS. *Primary repair of anterior cruciate ligament injuries: current level of evidence of available techniques*. JBJS Rev. 2021 May 6;9(5): e20.00174.
9. **Van der List JP**, Vermeijden HD, Sierevelt IN, Rademakers MV, Falke MLM, Helmerhorst GTT, Hoogeslag RAG, Van der Wal WA, Van Noort A, Kerkhoffs GMMJ. *Repair versus reconstruction for proximal anterior cruciate ligament tears: a study protocol for a prospective multicenter randomized controlled trial*. BMC Musculoskelet Disord. 2021 Apr;22(1):399.
10. Vermeijden HD, Yang XA, **Van der List JP**, DiFelice GS. *Role of age on success of arthroscopic primary repair of proximal anterior cruciate ligament tears*. Arthroscopy. 2021 Apr;37(4):1194-1201.
11. Vermeijden HD, **Van der List JP**, DiFelice GS. *Arthroscopic primary repair of the posterior cruciate ligament*. J Knee Surg. 2021 Apr;34(5):478-485.

12. Bayoumi T, Benner JL, Stavenuiter MHJ, **Van der List JP**. *Tibial tubercle transfer leads to clinically relevant improvement in patients with patellar maltracking without instability: a systematic review and meta-analysis*. *Knee Surg Sports Traumatol Arthrosc*. 2021 Apr;29(4):1137-1149.
13. **Van der List JP**, El Saddy S, Temmerman OPP, Vos CJ. *Role of preoperative posterior tilt on the outcomes of internal fixation of non-displaced femoral neck fractures: a systematic review and meta-analysis*. *Injury*. 2021 Mar;52(3):316-323.
14. Vermeijden HD, **Van der List JP**, Chen YT, DiFelice GS. *Minocycline-induced black bone disease with synovial pigmentation in a patient undergoing revision anterior cruciate ligament surgery: A case report*. *Int J Surg Case Rep*. 2021 Mar;81(6):105819.
15. **Van der List JP**, Hagemans FJA, Zuiderbaan HA, Van Dijke C, Van Noort A, Kerkhoffs GMMJ. *Age, activity level and meniscus injury, but not tear location, tibial slope or anterolateral ligament injury predict coping with anterior cruciate ligament injury*. *Knee*. 2021 Feb;30(2):222-232.
16. Vermeijden HD, **Van der List JP**, DiFelice GS. *Acute and delayed anterior cruciate ligament repair results in similar short to mid-term outcomes*. *Knee*. 2021 Feb;30(2):142-149.
17. Oosterhoff TCM, Beekman VK, **Van der List JP**, Niessen FB. *Laser treatment of specific scar characteristics in hypertrophic scars and keloid: A systematic review*. *J Plast Reconstr Aesthet Surg*. 2021 Jan;74(1):48-64.
18. Vermeijden HD, Yang XA, **Van der List JP**, DiFelice GS, Rademakers MV, Kerkhoffs GMMJ. *Trauma and femoral tunnel position are the most common failure modes of anterior cruciate ligament reconstruction: a systematic review*. *Knee Surg Sports Traumatol Arthrosc*. 2020 Nov;28(11):3666-3675.
19. Vermeijden HD, Yang XA, **Van der List JP**, DiFelice GS. *Large variation in indications, preferred surgical technique and rehabilitation protocol for primary anterior cruciate ligament repair: a survey among ESSKA members*. *Knee Surg Sports Traumatol Arthrosc*. 2020 Nov;28(11):3613-3621.
20. Hagemans FJA, Jonkers FJ, Van Dam MJJ, Von Gerhardt A, **Van der List JP**. *Clinical and radiographic outcomes of anterior cruciate ligament reconstruction with hamstring tendon graft and femoral cortical button fixation at minimum 20-year follow-up*. *Am J Sports Med*. 2020 Oct;48(12):2962-2969.
21. Vermeijden HD, **Van der List JP**, DiFelice GS. *Primary repair of the lateral collateral ligament using additional suture augmentation*. *Arthrosc Tech*. 2020 Jul 28;9(8):e1073-e1077.
22. **Van der List JP**, Hagemans FJA, Hofstee DJ, Jonkers FJ. *The role of patient characteristics in the success of nonoperative treatment of anterior cruciate ligament injuries*. *Am J Sports Med*. 2020 Jun;48(7):1657-1664.

23. Vermeijden HD, **Van der List JP**, DiFelice GS. *Return to sports following arthroscopic primary repair of the anterior cruciate ligament in the adult population*. *Knee*. 2020 Jun;27(3):906-914.
24. **Van der List JP**, Vermeijden HD, Sierevelt IN, DiFelice GS, Van Noort A, Kerkhoffs GMMJ. *Arthroscopic primary repair of proximal anterior cruciate ligament tears seems safe but higher level of evidence is needed: a systematic review and meta-analysis of recent literature*. *Knee Surg Sports Traumatol Arthrosc*. 2020 Jun;28(6):1946-1957.
25. Vermeijden HD, O'Brien R, **Van der List JP**, DiFelice GS. *Patients forget about their operated knee more following arthroscopic primary repair of the anterior cruciate ligament than following reconstruction*. *Arthroscopy*. 2020 Mar;36(3):797-804.
26. Vermeijden HD, **Van der List JP**, DiFelice GS. *Arthroscopic posterior cruciate ligament primary repair*. *Sports Med Arthros Review*. 2020 Mar;28(1):23-29.
27. Vermeijden HD, Jonkergouw A, **Van der List JP**, DiFelice GS. *Arthroscopic primary repair of the anterior cruciate ligament with single-bundle graft augmentation*. *Arthrosc Tech*. 2020 Feb;9(3):e367-e373.
28. Vermeijden HD, Jonkergouw A, **Van der List JP**, DiFelice GS. *The multiple ligament-injured knee: when is primary repair an option?* *Knee*. 2020 Jan;27(1):173-182.
29. Verbeek DO, **Van der List JP**, Helfet DL. *Computed tomography versus plain radiography assessment of acetabular fracture reduction is more predictive for native hip survivorship*. *Arch Orthop Trauma Surg*. 2019 Dec;139(12):1667-1672.
30. **Van der List JP**, Mintz DN, DiFelice GS. *The locations of anterior cruciate ligament tears in pediatric and adolescent patients: a magnetic resonance imaging study*. *J Pediatr Orthop*. 2019 Oct;39(9):441-448.
31. **Van der List JP**, Jonkergouw A, DiFelice GS. *Anterior cruciate ligament reconstruction following failed primary repair: surgical technique and a report of three cases*. *Minerva Orthop e Trauma*. 2019 June;70(2):70-77.
32. **Van der List JP**, Jonkergouw A, Van Noort A, Kerkhoffs GMMJ, DiFelice GS. *Identifying candidates for arthroscopic primary repair of the anterior cruciate ligament: a case-control study*. *Knee*. 2019 Jun;26(3):619-627.
33. **Van der List JP**, Mintz DN, DiFelice GS. *Postoperative magnetic resonance imaging following arthroscopic primary anterior cruciate ligament repair*. *Adv Orthop*. 2019 Mar;2019:5940195.
34. Jonkergouw A, **Van der List JP**, DiFelice GS. *Arthroscopic primary repair of proximal anterior cruciate ligament tears: outcomes of first 56 consecutive patients and the role of additional internal bracing*. *Knee Surg Sports Traumatol Arthrosc*. 2019 Jan;27(1):21-28.
35. Villa JC, **Van der List JP**, Koressel J, Cohn M, Lyden JP, Wellman DS, Lorch DG, Lane JM. *Predictors of in-hospital ambulatory status following low energy hip fractures*. *Geriatr Orthop Surg Rehabil*. 2019 Jan 10;10:2151459318814825.

36. Jonkergouw A, **Van der List JP**, DiFelice GS. *Multiligament repair with suture augmentation in a knee dislocation with medial-sided injury*. Arth Tech. 2018 Jul;7(8):e839-e843.
37. Verbeek DO, **Van der List JP**, Moloney GM, Wellmann DS, Helfet DL. *Assessing postoperative reduction after acetabular fracture surgery: a standardized digital computed tomography-based method*. J Orthop Trauma. 2018 Jul;32(7):e284-e288.
38. Verbeek DO, **Van der List JP**, Tissue CM, Helfet DL. *Predictors for long-term hip survivorship following acetabular fracture surgery: importance of gap compared with step displacement*. J Bone Joint Surg Am. 2018 Jun;100(11):922-929.
39. Verbeek DO, **Van der List JP**, Tissue CM, Helfet DL. *Long-term patient reported outcomes following acetabular fracture fixation*. Injury. 2018 Jun;49(6):1131-1136.
40. Camp CL, Dines JS, **Van der List JP**, Conte S, Conway J, Altcheck DW, Coleman SH, Pearle AD. *Summative report on time out of play for major and minor league baseball: an analysis of 49,955 injuries from 2011 through 2016*. Am J Sports Med. 2018 Jun;46(7):1727-1732.
41. Kleeblad LJ, **Van der List JP**, Zuiderbaan HA, Pearle AD. *Larger range of motion and increased return to activity, but higher revision rates following unicompartmental versus total knee arthroplasty in patients under 65: a systematic review*. Knee Surg Sports Traumatol Arthrosc. 2018 Jun;26(6):1811-1822.
42. Daniels S, **Van der List JP**, Kazam J, DiFelice GS. *Arthroscopic primary repair of the anterior cruciate ligament: what the radiologist needs to know*. Skeletal Radiol. 2018 May;47(5):619-629.
43. DiFelice GS, **Van der List JP**. *Clinical outcomes of arthroscopic primary repair of proximal anterior cruciate ligament tears are maintained at mid-term follow-up*. Arthroscopy. 2018 Apr;34(4):1085-1093.
44. Camp CL, Klinger CE, Lazaro LE, Villa JC, **Van der List JP**, Altchek DW, Lorch DG, Dines JS. *Osseous vascularity of the medial elbow after ulnar collateral ligament reconstruction: a comparison of the docking and modified Jobe techniques*. Orthop J Sports Med. 2018 Apr 2;6(4):2325967118763153.
45. Kleeblad LJ, **Van der List JP**, Pearle AD, Fragomen A, Rozbruch SR. *Predicting the feasibility of correcting mechanical axis in large varus deformities with unicompartmental knee arthroplasty*. J Arthroplasty. 2018 Feb;33(2):372-378.
46. **Van der List JP**, DiFelice GS. *Preoperative magnetic resonance imaging predicts eligibility for arthroscopic primary anterior cruciate ligament repair*. Knee Surg Sports Traumatol Arthrosc. 2018 Feb; 26(2):660-671.
47. **Van der List JP**, Camp CL, Sinatro A, Dines JS, Pearle AD. *Systematic review of outcomes reporting in professional baseball: a call for increased validation and consistency*. Am J Sports Med. 2018 Feb;46(2):487-496.

48. Lazaro LE, Nawabi DH, Klinger CE, Sculco PK, **Van der List JP**, Dyke JP, Helfet DL, Kelly BT, Lorich DG. *Quantitative assessment of femoral head perfusion following arthroscopic femoral osteochondroplasty: a cadaveric study*. J Bone Joint Surg Am. 2017 Dec;99(24): 2092-2102.
49. Kleeblad LJ, **Van der List JP**, Zuiderbaan HA, Pearle AD. *Regional femoral and tibial radiolucency in cemented unicompartmental knee arthroplasty and the relationship to functional outcomes*. J Arthroplasty. 2017 Nov;32(11):3345-3351.
50. Verbeek DO, **Van der List JP**, Villa JC, Wellmann DS, Helfet DL. *Postoperative CT is superior for acetabular fracture reduction assessment and reliably predicts hip survivorship*. J Bone Joint Surg Am. 2017 Oct;99(20):1745-1752.
51. **Van der List JP**, DiFelice GS. *Role of tear location on outcomes of open primary repair of the anterior cruciate ligament: a systematic review of historical studies*. Knee. 2017 Oct;24(5):898-908.
52. **Van der List JP**, Zuiderbaan HA, Pearle AD. *Mid-term outcomes of metal-backed unicompartmental knee arthroplasty show superiority to all-polyethylene unicompartmental and total knee arthroplasty*. HSS J. 2017 Oct;13(3):232-240.
53. Kent RN, Boorman-Padgett JF, Thein R, **Van der List JP**, Nawabi DH, Wickiewicz TL, Imhauser CW, Pearle AD. *High interspecimen variability in engagement of the anterolateral ligament: an in vitro cadaveric study*. Clin Orthop Relat Res. 2017 Oct;475(10):2438-2444.
54. **Van der List JP**, DiFelice GS. *Arthroscopic primary posterior cruciate ligament repair with suture augmentation*. Arthrosc Tech. 2017 Sep;6(5):e1685-e1690.
55. **Van der List JP**, DiFelice GS. *Arthroscopic primary anterior cruciate ligament repair with suture augmentation*. Arthrosc Tech. 2017 Sep;6(5):e1529-e1534.
56. Chawla H, Nwachukwu B, **Van der List JP**, Eggman AA, Pearle AD, Ghomrawi HM. *Cost effectiveness of patellofemoral versus total knee arthroplasty in young patients*. Bone Joint J. 2017 Aug;99-B(8):1028-1036.
57. **Van der List JP**, DiFelice GS. *Primary repair of the medial collateral ligament with internal bracing*. Arthrosc Tech. 2017 Aug;6(4):e933-e937.
58. **Van der List JP**, DiFelice GS. *Range of motion and complications following primary repair versus reconstruction of the anterior cruciate ligament*. Knee. 2017 Aug;24(4):798-807.
59. **Van der List JP**, Chawla H, Zuiderbaan HA, Pearle AD. *Survivorship and functional outcomes of patellofemoral arthroplasty: a systematic review*. Knee Surg Sports Traumatol Arthrosc. 2017 Aug;25(8):2622-2631.
60. **Van der List JP**, Mintz, DN, DiFelice GS. *The location of anterior cruciate ligament tears: a prevalence study using magnetic resonance imaging*. Orthop J Sports Med. 2017 Jun;5(6):2325967117709966.



61. McDonald LS, **Van der List JP**, Jones KJ, Zuiderbaan HA, Nguyen JT, Nawabi DH, Potter HG, Wickiewicz TJ, Pearle AD. *Passive anterior tibial subluxation in the setting of anterior cruciate ligament injuries: a comparative analysis of ligament-deficient states.* Am J Sports Med. 2017 Jun;45(7):1537-1546.
62. **Van der List JP**, Sheng DL, Kleeblad LJ, Chawla H, Pearle AD. *Outcomes of cementless unicompartmental and total knee arthroplasty: a systematic review.* Knee. 2017 Jun;24(3):497-507.
63. **Van der List JP**, DiFelice GS. *Primary repair of the anterior cruciate ligament: a paradigm shift.* Surgeon. 2017 Jun;15(3):161-168.
64. **Van der List JP**, Zuiderbaan HA, Nawabi DH, Pearle AD. *Impingement following anterior cruciate ligament reconstruction: comparing the direct versus indirect femoral tunnel position.* Knee Surg Sports Traumatol Arthrosc. 2017 May;25(5):1617-1624.
65. Pearle AD, **Van der List JP**, Lee L, Coon TM, Borus TA, Roche MW. *Survivorship and patient satisfaction of robotic-assisted medial unicompartmental knee arthroplasty at a minimum two-year follow-up.* Knee. 2017 Mar;24(2):419-428.
66. **Van der List JP**, DiFelice GS. *Gap formation following primary repair of the anterior cruciate ligament: a biomechanical evaluation.* Knee. 2017 Mar;24(2):243-249.
67. Chawla H, **Van der List JP**, Christ AB, Sobrero MR, Zuiderbaan HA, Pearle AD. *Annual revision rates of partial versus total knee arthroplasty: a comparative meta-analysis.* Knee. 2017 Mar;24(2):179-190.
68. **Van der List JP**, Chawla H, Villa JC, Pearle AD. *The role of patient characteristics on the choice of unicompartmental versus total knee arthroplasty in patients with medial osteoarthritis.* J Arthroplasty. 2017 Mar;32(3):761-766.
69. **Van der List JP**, Chawla H, Villa JC, Zuiderbaan HA, Pearle AD. *Early functional outcome after lateral UKA is sensitive to postoperative lower limb alignment.* Knee Surg Sports Traumatol Arthrosc. 2017 Mar;25(3):687-693.
70. Zuiderbaan HA, **Van der List JP**, Khamaisy S, Nawabi DH, Thein R, Ishmael C, Paul S, Pearle AD. *Unicompartmental knee arthroplasty versus total knee arthroplasty: which type of artificial joint do patients forget?* Knee Surg Sports Traumatol Arthrosc. 2017 Mar;25(3):681-686.
71. **Van der List JP**, DiFelice GS. *Successful arthroscopic primary repair of a chronic anterior cruciate ligament tear 11 years following injury.* HSS J. 2017 Feb;13(1):90-95.
72. **Van der List JP**, Chawla H, Villa JC, Pearle AD. *Why do patellofemoral arthroplasties fail today? A systematic review.* Knee. 2017 Jan;24(1):2-8.
73. Chawla H, Ghomrawi HM, **Van der List JP**, Eggman AA, Zuiderbaan HA, Pearle AD. *Establishing age-specific cost-effective annual revision rates for unicompartmental knee arthroplasty: a meta-analysis.* J Arthroplasty. 2017 Jan;32(1):326-335.

74. **Van der List JP**, Chawla H, Villa JC, Pearle AD. *Different optimal alignment but equivalent functional outcomes in medial and lateral unicompartmental knee arthroplasty.* Knee. 2016 Dec;23(6):987-995.
75. **Van der List JP**, Chawla H, Zuiderbaan HA, Pearle AD. *Patients with isolated lateral osteoarthritis: unicompartmental or total knee arthroplasty?* Knee. 2016 Dec;23(6):968-974.
76. **Van der List JP**, Zuiderbaan HA, Pearle AD. *Why do lateral unicompartmental knee arthroplasties fail today?* Am J Orthop. 2016 Nov/Dec;45(7):432-438, 462.
77. **Van der List JP**, DiFelice GS. *Preservation of the anterior cruciate ligament: surgical techniques.* Am J Orthop. 2016 Nov/Dec;45(7):E406-E414.
78. **Van der List JP**, DiFelice GS. *Preservation of the anterior cruciate ligament: a treatment algorithm based on tear location and tissue quality.* Am J Orthop. 2016 Nov/Dec;45(7):E393-E405.
79. **Van der List JP**, Chawla H, Joskowicz J, Pearle AD. *Current state of computer navigation and robotics in unicompartmental and total knee arthroplasty: a systematic review with meta-analysis.* Knee Surg Sports Traumatol Arthrosc. 2016 Nov;24(11):3482-3495.
80. **Van der List JP**, Chawla H, Zuiderbaan HA, Pearle AD. *The role of preoperative patient characteristics on outcomes of unicompartmental knee arthroplasty: a meta-analysis critique.* J Arthroplasty. 2016 Nov;31(11):2617-2627.
81. Villa JC, **Van der List JP**, Gausden EB, Lorich DG, Helfet DL, Kloen P, Wellman DS. *Plate fixation and bone grafting of distal clavicle nonunions: radiologic and functional outcomes.* Arch Orthop Trauma Surg. 2016 Nov;136(11):1521-1529.
82. Villa JC, Hussain S, **Van der List JP**, Gianakos A, Fields K, Lane JM. *Treatment of pre-collapse stages of osteonecrosis of the femoral head: a systematic review of randomized control trials.* HSS J. 2016 Oct;12(3):261-271.
83. Zuiderbaan HA, **Van der List JP**, Appelboom P, Kort NP, Pearle AD, Rademakers MV. *Modern indications, results, and global trends in the use of unicompartmental knee arthroplasty and high tibial osteotomy in the treatment of isolated medial compartment osteoarthritis.* Am J Orthop. 2016 Sep/Oct;45(6):E355-E361.
84. DiFelice GS, **Van der List JP**. *Arthroscopic primary repair of proximal anterior cruciate ligament tears.* Arthrosc Tech. 2016 Sep;5(5):e1057-e1061.
85. Zuiderbaan HA, **Van der List JP**, Chawla H, Khamaisy S, Thein R, Pearle AD. *Predictors of subjective outcome after medial unicompartmental knee arthroplasty.* J Arthroplasty. 2016 Jul;31(7):1453-1458.
86. Chawla H, **Van der List JP**, Fein NB, Henry MW, Pearle AD. *Barbed suture is associated with increased risk of wound infection after unicompartmental knee arthroplasty.* J Arthroplasty. 2016 Jul;31(7):1561-1567.

87. Khamaisy S, Zuiderbaan HA, **Van der List JP**, Nam D, Pearle AD. *Medial unicompartmental knee arthroplasty improves congruence and restores joint space width of the lateral compartment*. *Knee*. 2016 Jun;23(3):501-505.
88. **Van der List JP**, Chawla H, Pearle AD. *Robotic-assisted knee arthroplasty: an overview*. *Am J Orthop*. 2016 May-Jun;45(4):202-211.
89. **Van der List JP**, Zuiderbaan HA, Pearle AD. *Why do medial unicompartmental knee arthroplasties fail today?* *J Arthroplasty*. 2016 May;31(5):1016-1021.
90. DiFelice GS, **Van der List JP**. *Arthroscopic primary repair of posterior cruciate ligament injuries*. *Oper Tech Sports Med*. 2015 Dec;23(4):307-314.
91. **Van der List JP**, McDonald LS, Pearle AD. *Systematic review of medial versus lateral survivorship in unicompartmental knee arthroplasty*. *Knee*. 2015 Dec;22(6):454-460.
92. **Van der List JP**, Witbreuk MM, Buizer AI, Van der Sluijs JA. *The head-shaft angle of the hip in early childhood: a comparison of reference values for children with cerebral palsy and normally developing hips*. *Bone Joint J*. 2015 Sep;97-B(9):1291-1295.
93. **Van der List JP**, Witbreuk MM, Buizer AI, Van der Sluijs JA. *The prognostic value of the head-shaft angle on hip displacement in children with cerebral palsy*. *J Child Orthop*. 2015 Apr;9(2):129-135.

#### **Editorials and letters**

94. **Van der List JP**. *Editorial commentary: Anterolateral reconstruction versus lateral extra-articular tenodesis: Six of one and half a dozen of the other?* *Arthroscopy*. 2020 Jul;36(7):1951-1952.
95. DiFelice GS, Sonnery-Cottet B, Douoguih WA, **Van der List JP**. *Should we rethink how to define success following ACL surgery? A letter to the editor*. *Am J Sports Med*. 2019 Aug;47(10):NP58-NP59.
96. Ahmad SS, DiFelice GS, **Van der List JP**, Ateschrang, Hirschmann MT. *Primary repair of the anterior cruciate ligament: real innovation or reinvention of the wheel?* *Knee Surg Sports Traumatol Arthrosc*. 2019 Jan;27(1):1-2
97. **Van der List JP**, DiFelice GS. *Reply to the letter to the editor regarding our article "Preoperative magnetic resonance imaging predicts eligibility for arthroscopic primary anterior cruciate ligament repair"*. *Knee Surg Sports Traumatol Arthrosc*. 2018 Feb; 26(2):672-673.
98. DiFelice GS, **Van der List JP**. *Regarding "Acute proximal anterior cruciate ligament tears: outcomes after arthroscopic suture anchor repair versus anatomic single-bundle reconstruction"*. *Arthroscopy*. 2017 Apr;33(4):693-694.

#### **Collaborator**

99. COVIDSurg Collaborative, GlobalSurg Collaborative [**Van der List JP**]. *Effects of pre-operative isolation on postoperative pulmonary complications after elective surgery: an international prospective cohort study*. *Anaesthesia*. 2021, in press.

100. COVIDSurg Collaborative, GlobalSurg Collaborative [Van der List JP]. *SARS-CoV-2 vaccination modelling for safe surgery to save lives: data from an international prospective cohort study*. Br J Surg. 2021, in press.
101. COVIDSurg Collaborative, GlobalSurg Collaborative [Van der List JP]. *Timing of surgery following SARS-CoV-2 infection: an international prospective cohort study*. Anaesthesia. 2021 Jun;76(6):748-758.

### **Book chapters**

1. Vermeijden HD, **Van der List JP**, DiFelice GS. *Arthroscopic Primary Repair of the Cruciate Ligaments*. Evidence-Based Management of Complex Knee Injuries: Restoring the Anatomy to Achieve Best Outcomes. 2020, pp 144-156.
2. **Van der List JP**, Jonkergouw A, DiFelice GS. *Preservation of the anterior cruciate ligament: arthroscopic primary repair of proximal tears*. Lower Extremity Joint Preservation: Techniques for Treating the Hip, Knee, and Ankle. 2020, pp 179-192.
3. Jonkergouw A, **Van der List JP**, DiFelice GS. *Arthroscopic primary repair in the multiple ligament injured knee*. The Multiple Ligament Injured Knee: A Practical Guide to Management. 2019, pp. 213-226.
4. **Van der List JP**, DiFelice GS. *The role of primary repair in pediatric anterior cruciate ligament injuries*. The Pediatric Anterior Cruciate Ligament: Evaluation and Management Strategies. 2017, pp. 227-239.
5. **Van der List JP**, Pearle AD. *Instrumental laxity evaluation*. Controversies in the Technical Aspects of ACL Reconstruction: An Evidence Based Medicine Approach. 2017, pp. 437-450.
6. **Van der List JP**, Nawabi DH, Pearle AD. *Functional analysis of ACL insertion site*. Controversies in the Technical Aspects of ACL Reconstruction: An Evidence Based Medicine Approach. 2017, pp. 181-192.
7. Nawabi DH, **Van der List JP**, Williams AM. *Technical considerations for patella tendon harvest*. Controversies in the Technical Aspects of ACL Reconstruction: An Evidence Based Medicine Approach, 2017, pp. 103-120.
8. **Van der List JP**, DiFelice GS. *The role of ligament repair in ACL surgery*. Ligamentous Injuries of the Knee. 2016, pp. 199-220.
9. **Van der List JP**, Pearle AD. *Mechanizing the pivot shift test*. Rotatory Knee Instability: An Evidence Based Approach. 2016, pp. 255-268.

# Appendices

## Acknowledgements

## Acknowledgments

This work is done! Without the help of many of people this thesis would have never been possible.

**Gregory DiFelice, “Dr. D”**, what an amazing time it has this been! From day one you have made me feel very welcome. Inviting my parents, Rhian and me over to your apartment at the start of the year meant a lot to me. These years were unforgettable with all the research meetings, the (very!) early Friday morning squash sessions and the many studies we have published. I am sure that we will work closely together in the future on this beautiful topic. You have been a great example for me, and I am honored to have worked together! Below a picture of us together at the Annual AAOS Meeting in 2017 in San Diego where all our initial work came together. Thank you for everything!



**Prof. dr. Kerkhoffs, Gino**, thank you very much for the opportunity to work together and help me bringing this thesis to an end! I am looking forward to our collaboration on the research of primary ACL repair and working together at the AMC!

**Arthur van Noort**, thank you very much for all your guidance over the years: from my first internship, making plans for going to HSS, and applying to residency in ROGO to the help with this thesis. You have taught me invaluable skills in several aspects of life, for which I am very grateful. And perhaps we will become colleagues in the field of shoulder surgeons as well!

**Rob and Yashira**, thank you very much for all your help with the research we performed. You must have been annoyed by the endless request for the MRIs or arthroscopy videos of the patients, for calling patients to see them in clinic or other otherwise. Also, my apologies for constantly delaying clinics by distracting dr. DiFelice 😊! Thank you for all the help and I promise to always step by when I am in New York!

**Craig Klinger**, thank you for the great time in the office on the 12<sup>th</sup> floor! Your help has been invaluable with directing me in the hospital, reviewing manuscripts, playing golf and the many drinks we had around the Upper East Side, although we did not always share each other's taste in music! You are a valuable friend, and I am sure we will always stay in touch!

**Dr. Mintz**, thank you for the brainstorming sessions and your help with the MRI studies and the classification system. Also thank you for being one of the friendliest doctors in HSS and inviting me and Rhian over for that great dinner!

**Dr. Pearle**, you have given me the chance to come to New York and work together on many great projects on robotic unicompartmental knee arthroplasty and ACL reconstruction. I will not forget our corroboration and the many Mets games we visited, and will never forget you extended my contract so I could stay in the US! Thank you for everything!

**Aernout and Jill**, “**the Pearle train**” is on full steam! **Aernout**, thank you for making it possible for me to go to the US and to get me adjusted to working in HSS and living in New York! **Jill**, thanks for the great time in the office, the many discussions, all your edits, listening to my endless primary repair stories and supporting Rhian and me with the transition! Your theses have been an inspiration for me!

**Anne and Daan**, thank you very much for all your energy and input as the successors on primary ACL repair research. Together with the rest of the team, we have definitely been leaders in the field of ACL repair, and I am sure our work will function as a foundation for future research.

**Dr. Helfet**, thank you for the support during my stay at HSS. You were the one of the first to focus on me as a person and I am grateful for your personal approach. I really enjoyed the acetabulum projects with Diederik, and they turned out to be great publications and a great thesis for Diederik. Thank you for all your (personal) help!

**Diederik**, I will always look back on our time in New York with great joy. I enjoyed the research, the many runs in Central Park and the friendship that grew from there!

**Gem and Max, my paranymphes**. **Gem**, the choice for you as a paranymph was an easy one, as our young careers have been parallel for most parts. I also appreciated that you kept submitting abstracts to conferences in New York, so you had both an excuse and funding to visit! **Max**, the choice for you as a paranymph was an easy one as well. Many and many sessions we have had in The Penrose and how we motivated each other for research and set

goals for our careers! And thank you for listening to the endless repair stories... Thank you both for joining me today, it's an honor!

**Colleagues at NWZ Alkmaar and SG Hoofddorp**, I have truly enjoyed my time as a resident at both hospitals and would like to thank you all for guiding me and helping me to become a better surgeon. A special thanks to the ACL surgeons in these hospitals (**Maarten, Wieger, Freerk** and **Dirk Jan**) for all you have taught me on this topic. Hopefully I can be your colleague in the future!

**Members of the review committee**, thank you for the critical evaluation of this thesis and I am looking forward to the day to defend the thesis with (and against) you.

**Other co-authors of the articles in this thesis**, thank you very much for all your help and contributions.

The **Jones family. Peter and Linda**, from day one you both have made me feel very welcome and loved, and a real part of your family. It is always a joy when we are together, and I am looking forward to many more experiences with the travel buddies! **David & Rebecca, Owen & Rachel, Gareth & Megan**, also thank you all for the joy and great times we have together, and Rhian and I cannot wait to have so many fun years and experiences ahead!

**W.Ph. van der List, lieve opa Flip**, thank you for the beautiful stories about how you fixed and repaired ACL tears in the 1960s and 1970s (with some arguable techniques). I also hope to become a great orthopaedic surgeon like you!

**Puck and Frederieke, lieve zusjes**, thank you both for always keeping me involved in the family and thank you for the visits! I'm really proud you of the both of you, and I am so happy to have you as sisters and as aunts for Gwyneth!


**Mom and dad**, I honestly don't know how to express my gratitude towards the both of you! You have always supported me in my choices and ambitions. Without the both of you, working in New York at HSS, and thus this thesis, would never have been possible. Thank you very much for always being there for me and for your unlimited support!

**Rhian Jones, Rhitje**, you have been the most amazing person I have ever met. Thank you for listening to the endless stream of stories on primary repair and even referring patients that are now in the study cohorts! More importantly, thank you for being the amazing, sweet and loving person that you are and for making me happy every day, and our shared love for our crazy girl Gwyneth! I love you very much and can't wait to spend the rest of my life with you and all our upcoming chapters together!



## About the author

Jelle Philip Jacob van der List (August 31, 1989) was born in Rotterdam, the Netherlands, and grew up in Maastricht and Amersfoort. After graduating from grammar school Johan van Oldebarneveld Gymnasium in Amersfoort, he started his medical school at the Free University (VU) Amsterdam. During the last years of medical school, he developed a special interest for orthopaedic surgery which resulted in his first publications during a research internship (Dr. Van der Sluijs), and an internship at the department of orthopaedic surgery of the Spaarne hospital (Dr. Van Noort).



In 2015 Jelle graduated from medical school and started to work as a research fellow at the Hospital for Special Surgery at the departments of Sports Medicine and Computer Assisted Surgery (Dr. Pearle) in New York, USA. Jelle performed research on the topics of robotic unicompartmental knee arthroplasty and completed the United States Medical License Examinations (USMLE) during this time. In July 2016, Jelle started to work as a research fellow on the topic of arthroscopic primary repair of the anterior cruciate ligament (Dr. DiFelice), which laid the foundation for this thesis that he performed and continued at the Amsterdam University Medical Centers in Amsterdam (Prof. Dr. Kerkhoffs). Over the years, he has given several presentations at national and international conferences on the topic of unicompartmental knee arthroplasty and arthroscopic primary anterior cruciate ligament repair.

In 2017, Jelle started his residency in orthopaedic surgery in NorthWest Clinics (Dr. Burger), Spaarne Gasthuis (Dr. Van Noort) and University Amsterdam Medical Centers (prof. Dr. Kerkhoffs). Jelle is currently an editorial board member for *Arthroscopy*, and a peer-reviewer for several journals including *The American Journal of Sports Medicine*, *Bone and Joint Journal*, *The Knee*, *The Surgeon* and *Knee Surgery, Sports Traumatology and Arthroscopy*.

He is part of a family of orthopaedic surgeons, as his grandfather (W.Ph. van der List), his uncle (J.J.J. van der List) and his father (M.P.J. van der List) are (former) orthopaedic surgeons. Jelle currently lives in Amsterdam with his wife Rhian and their daughter Gwyneth. In 2021, he started his part-time Master of Business Administration (MBA) at the Johns Hopkins University.